

Diagnose van middenvoet artrose

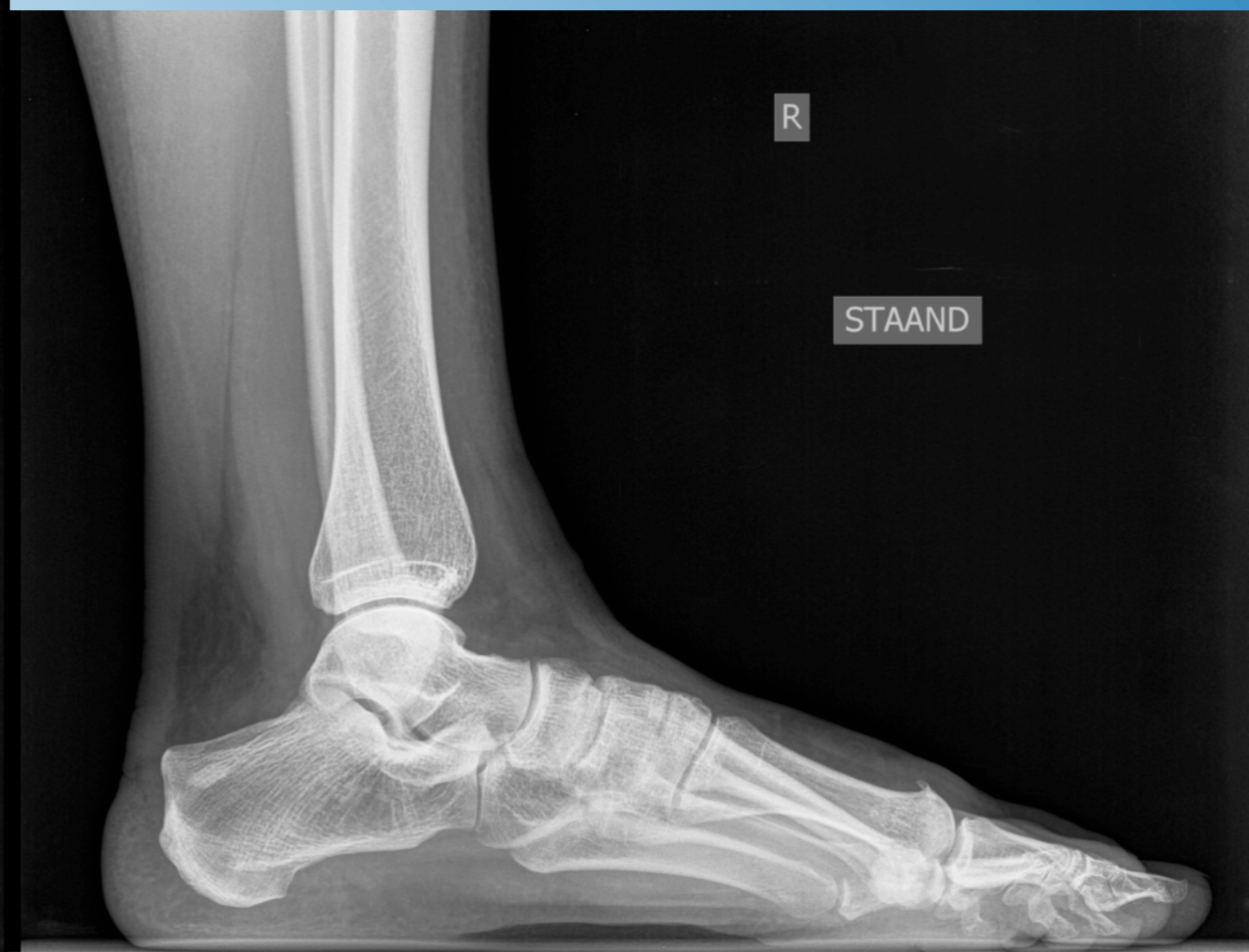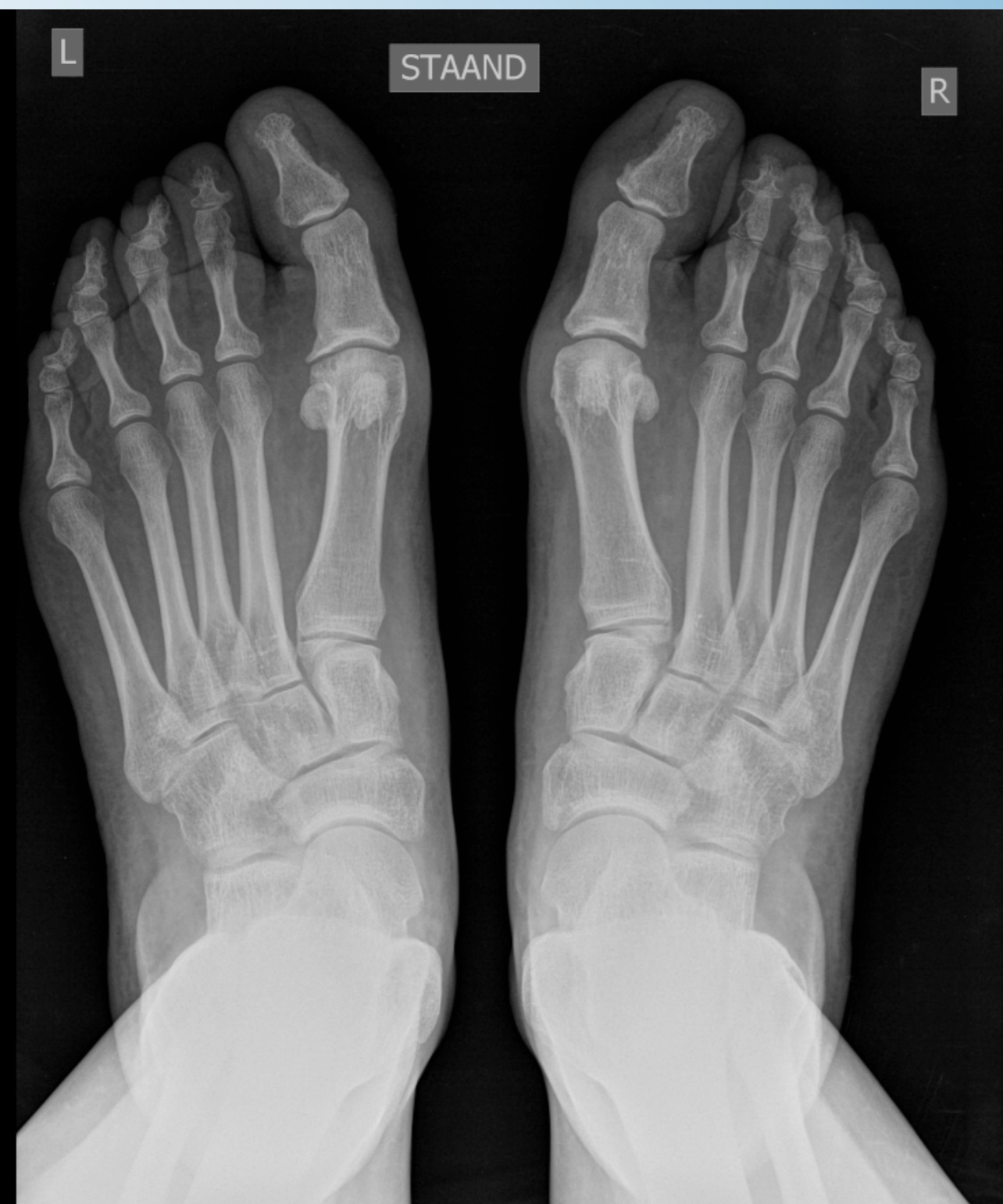Dr. Geoffroy Vandeputte

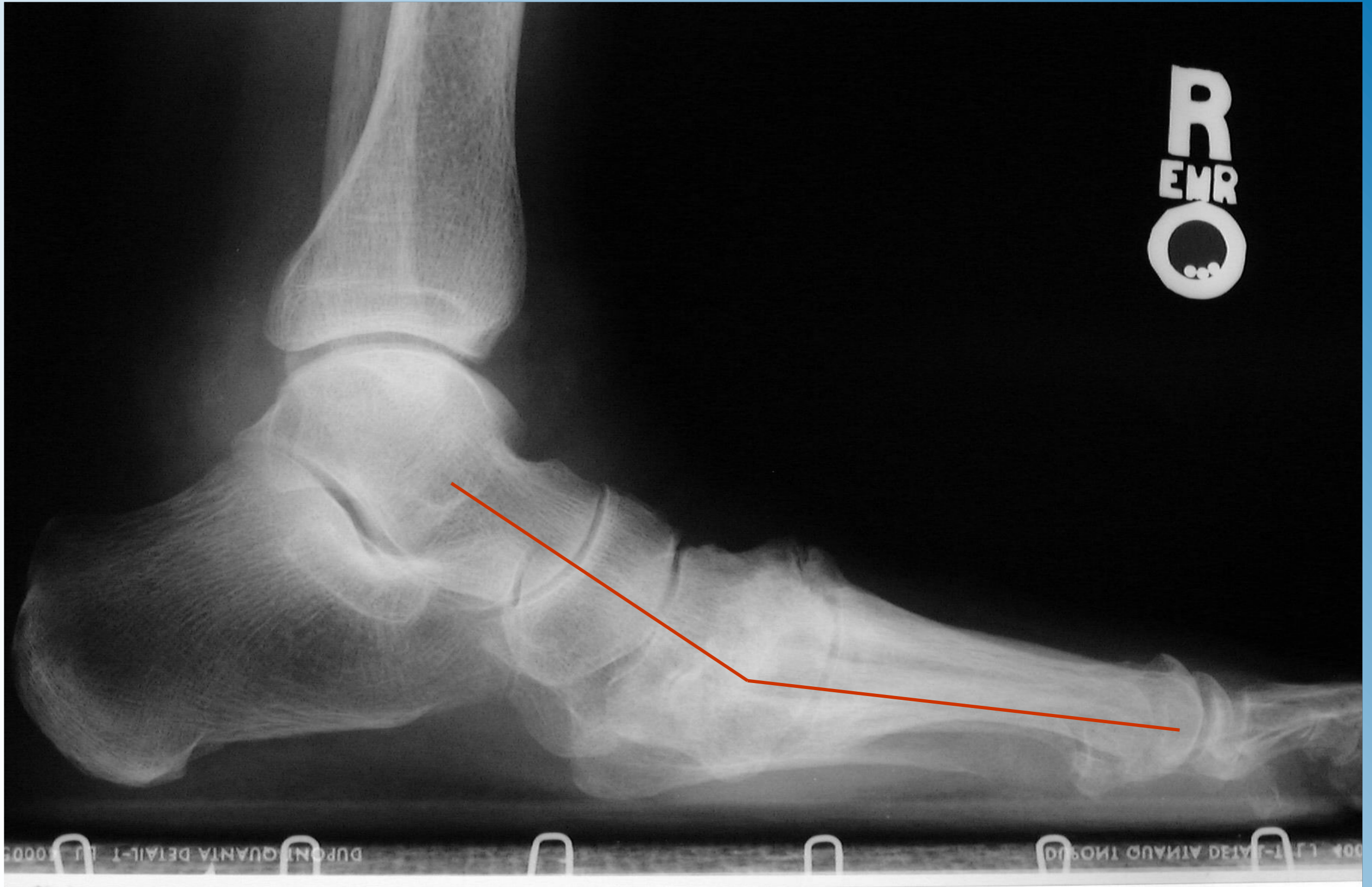Heilig Hart Ziekenhuis Lier

Belgium

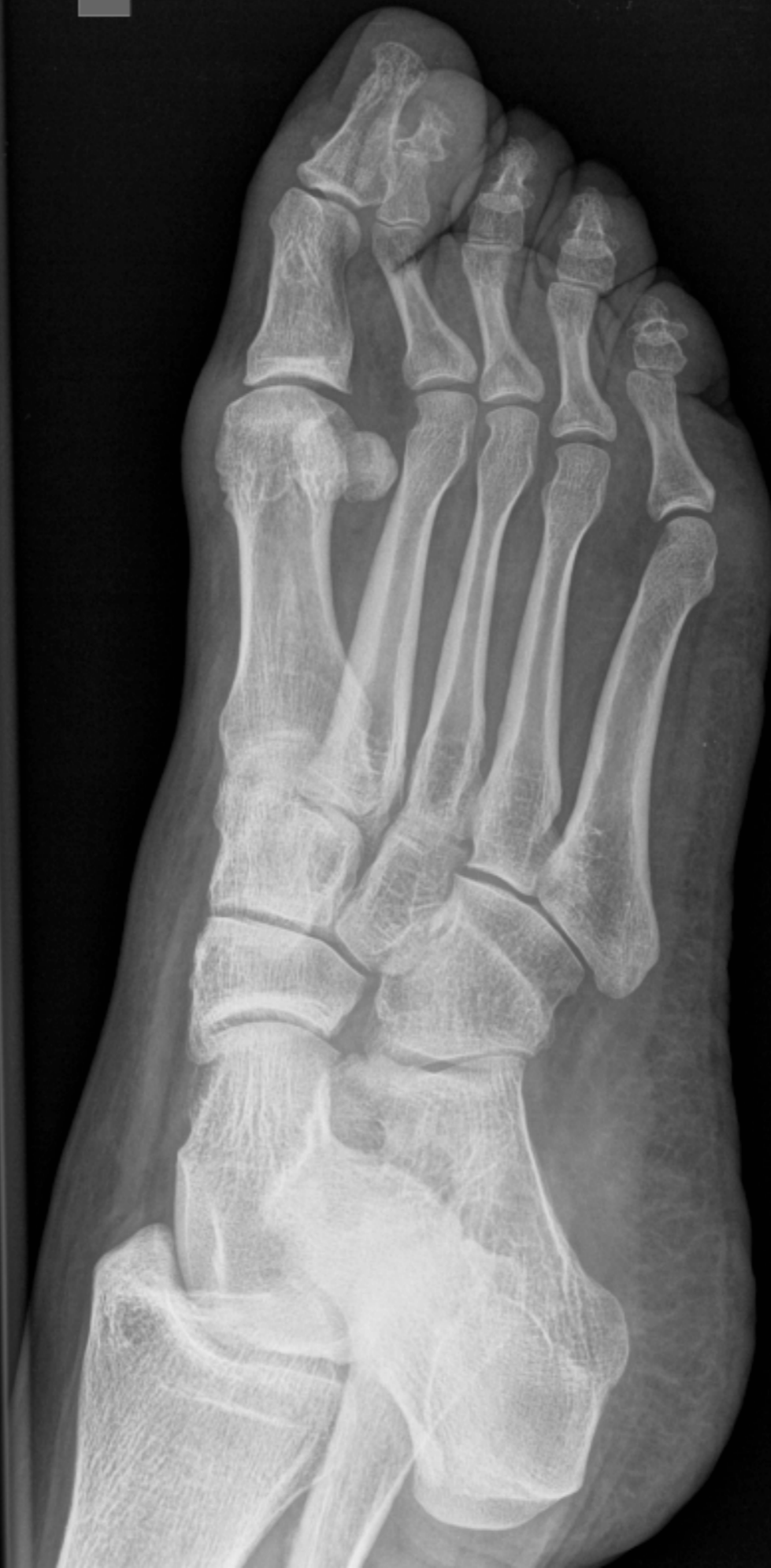Function of the midfoot joint complex

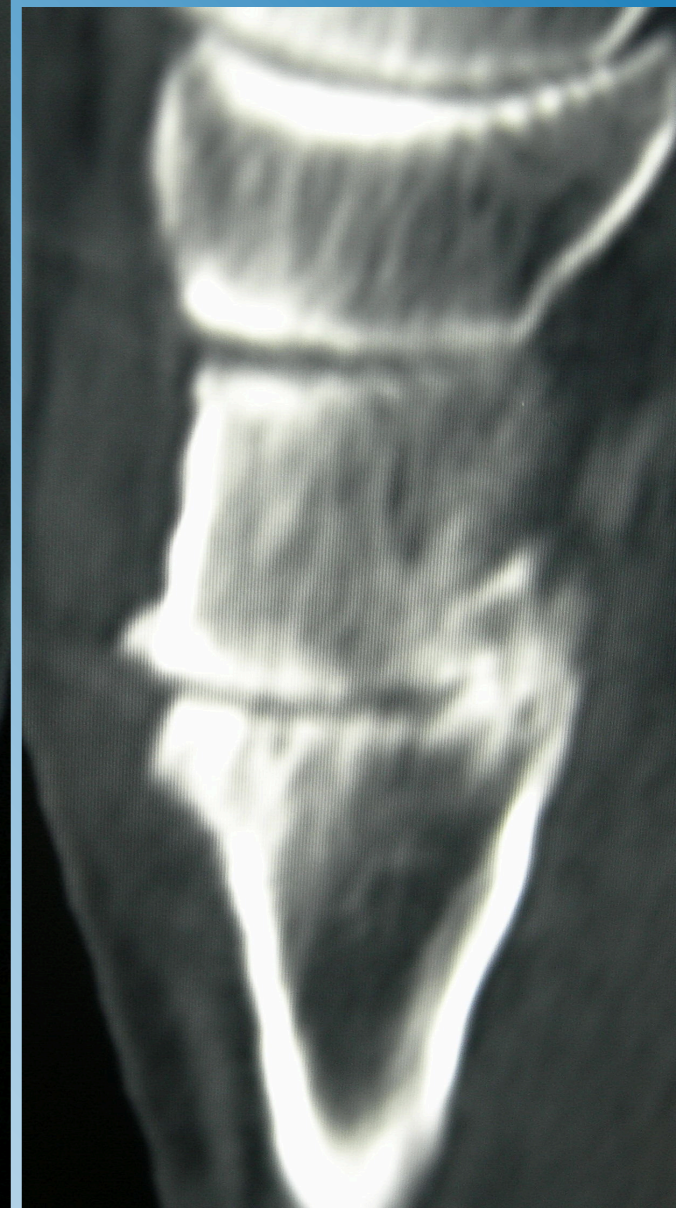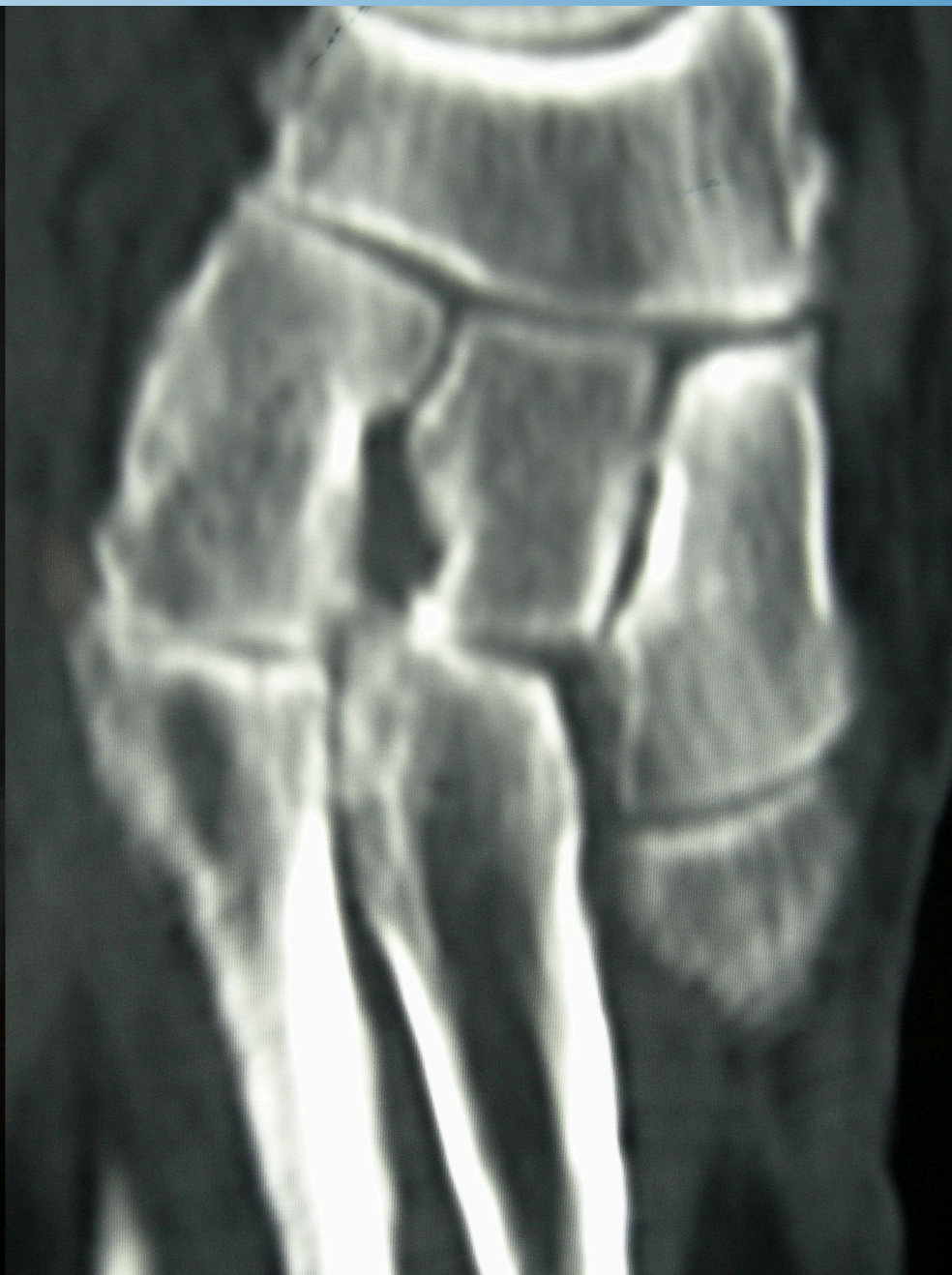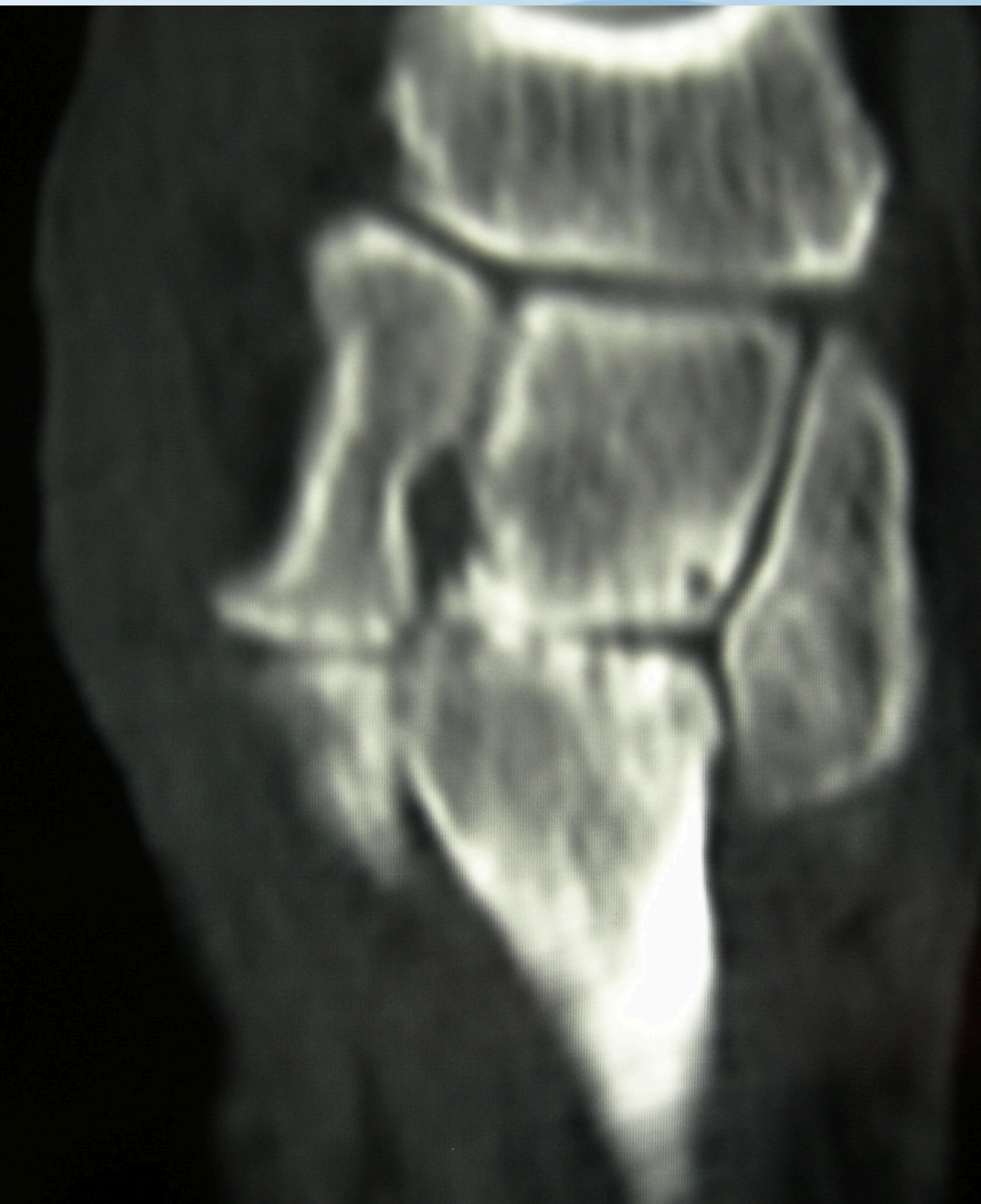
- TMT 1, 2 and 3 are relatively immobile.
- TMT 4 and 5 have some motion, foot adaptation to uneven ground

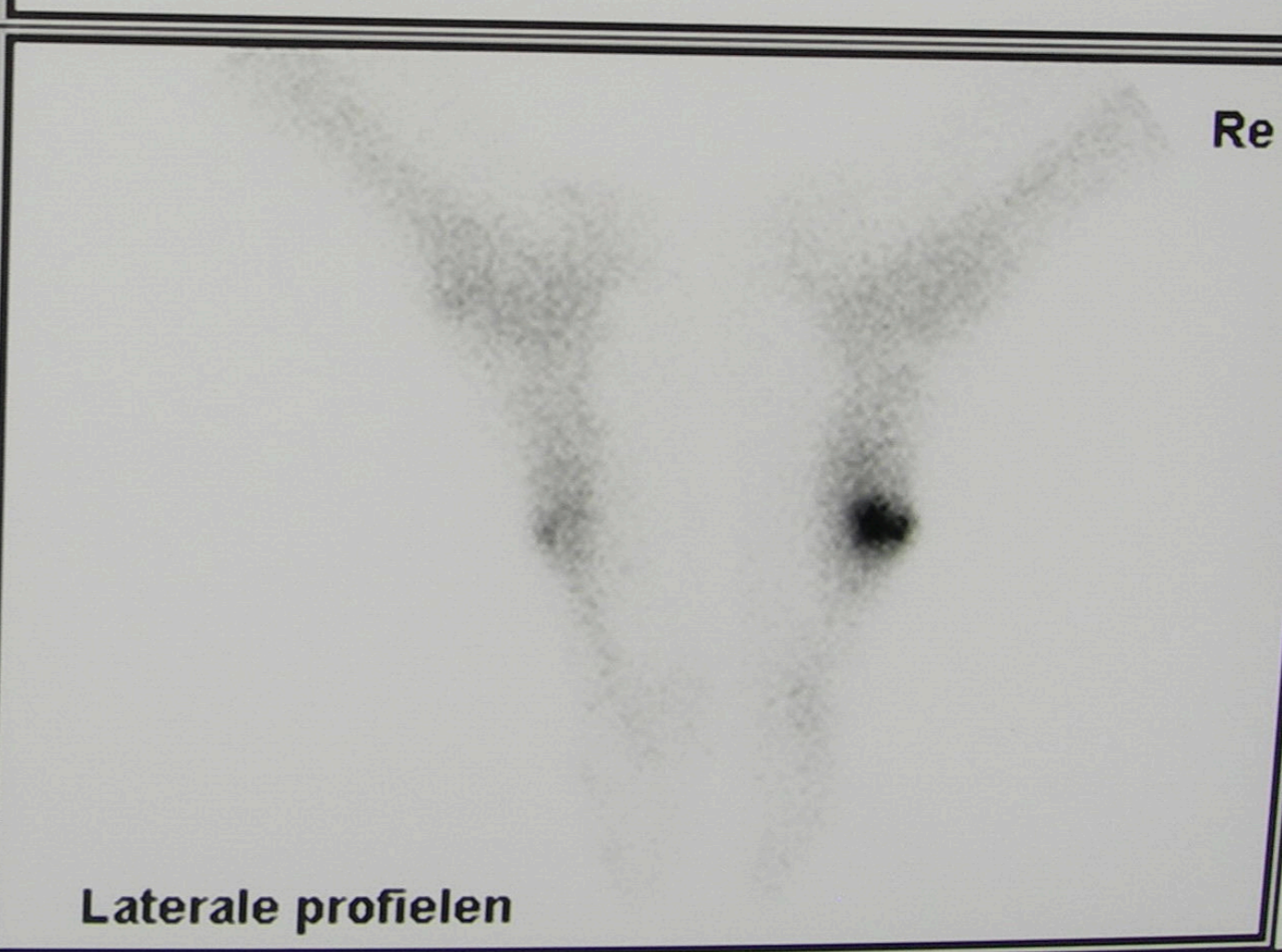
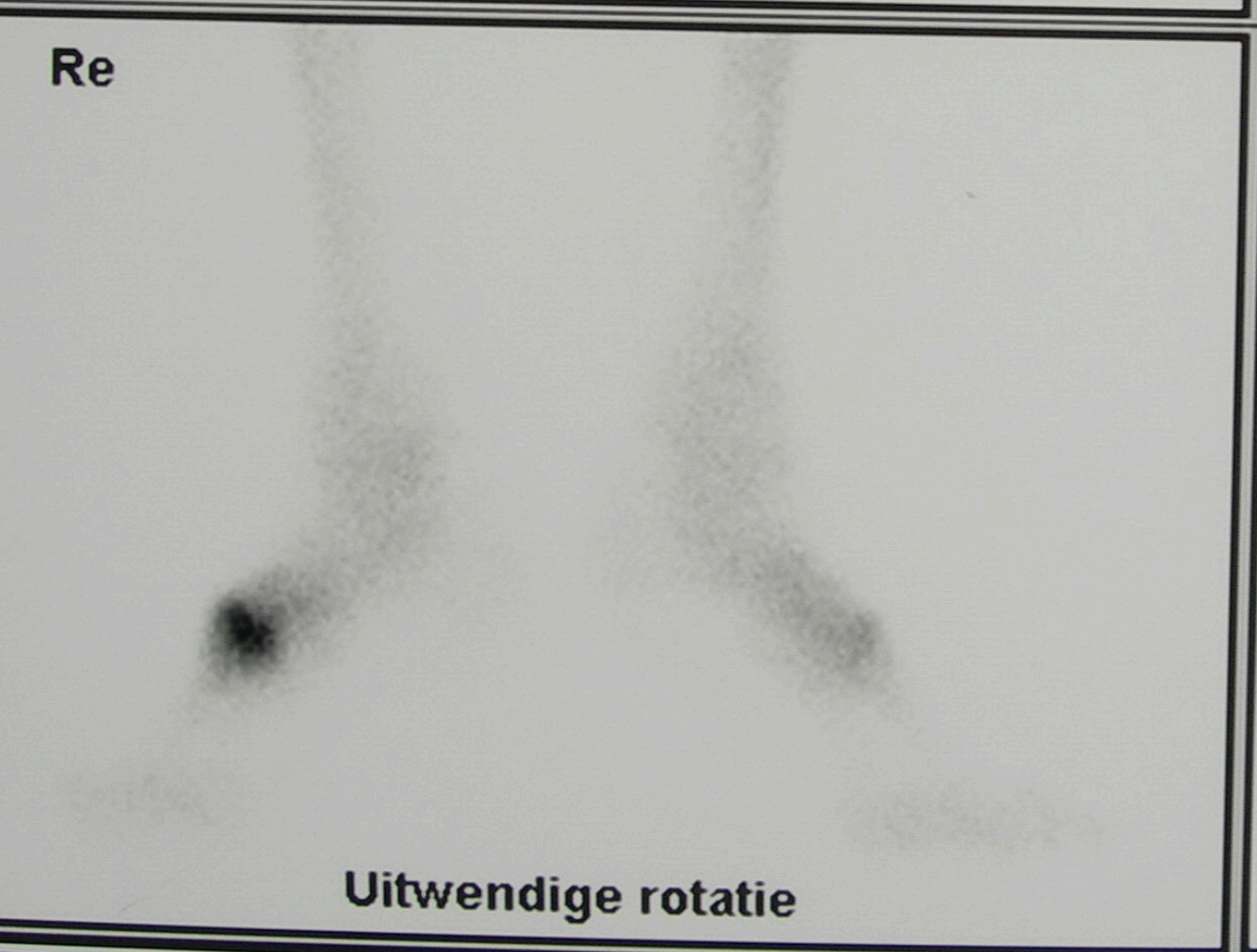
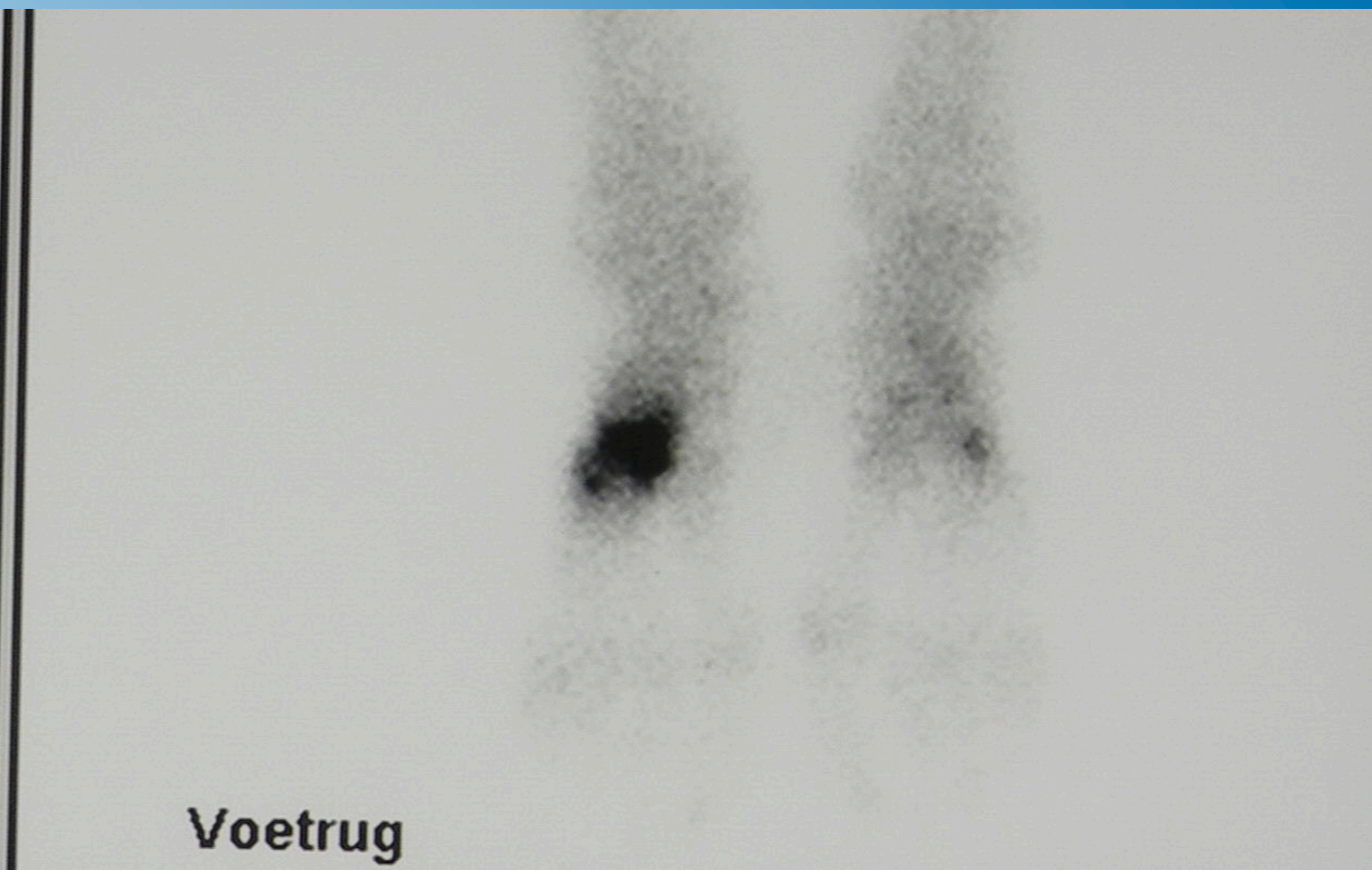
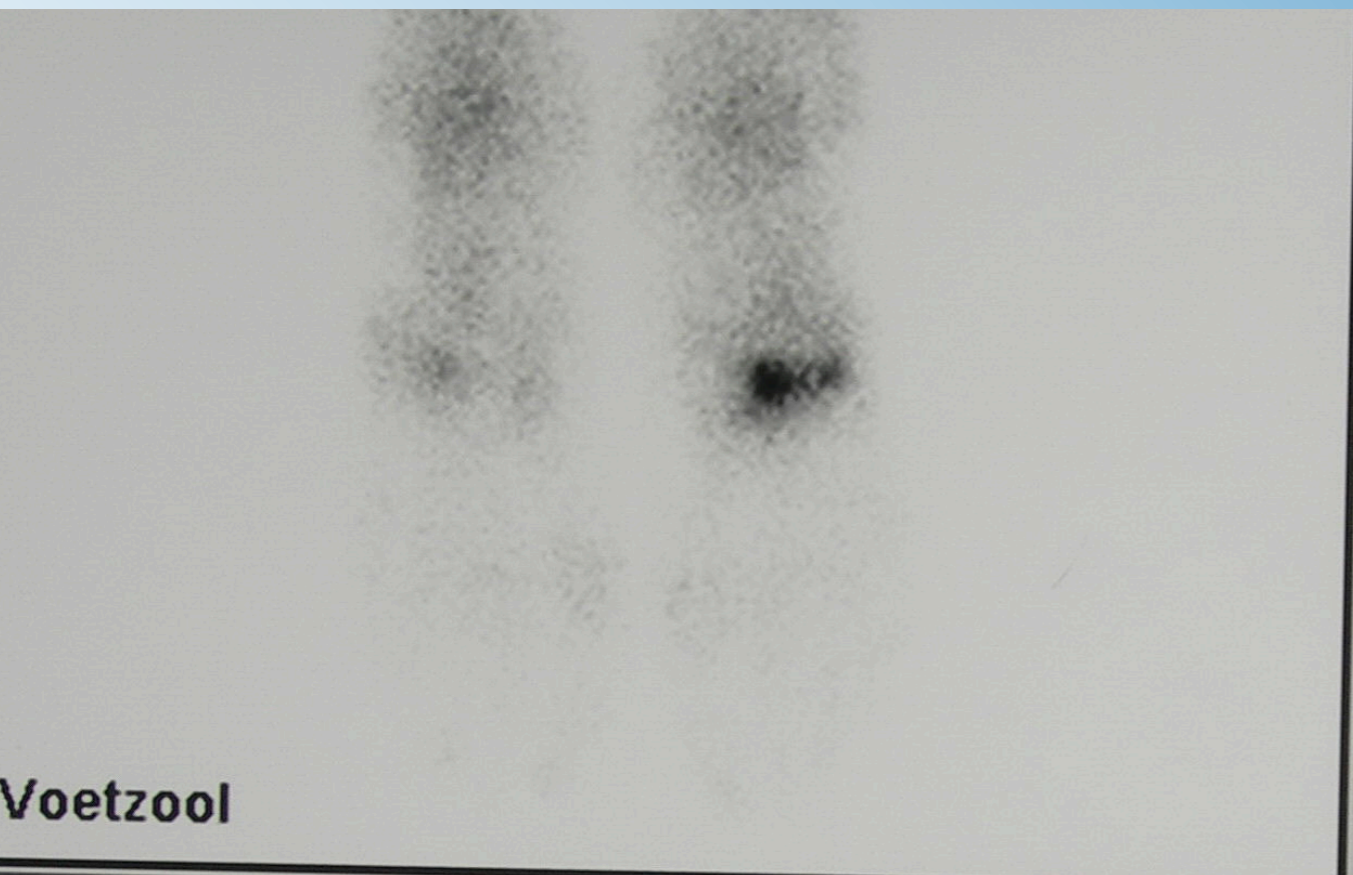


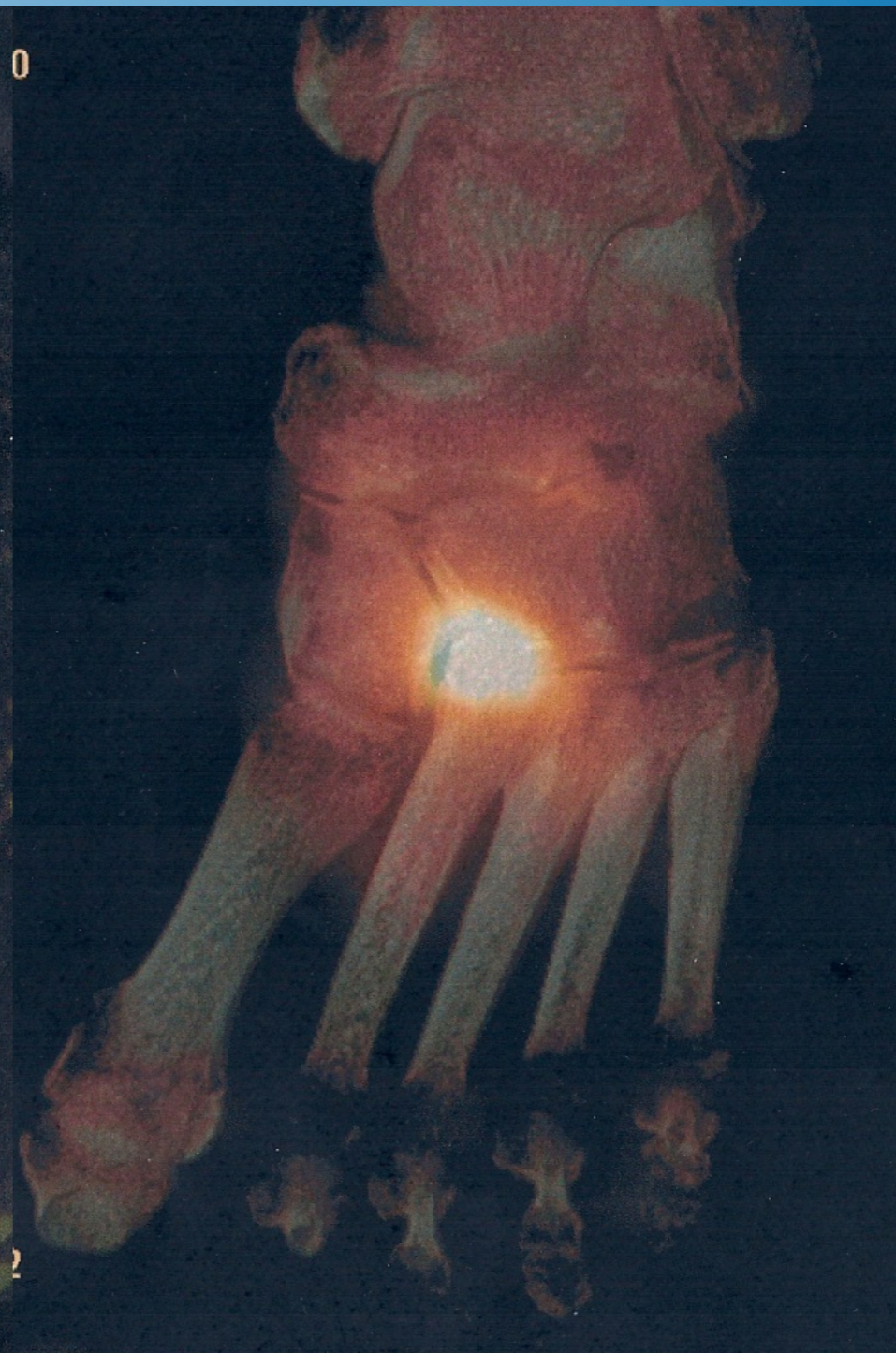
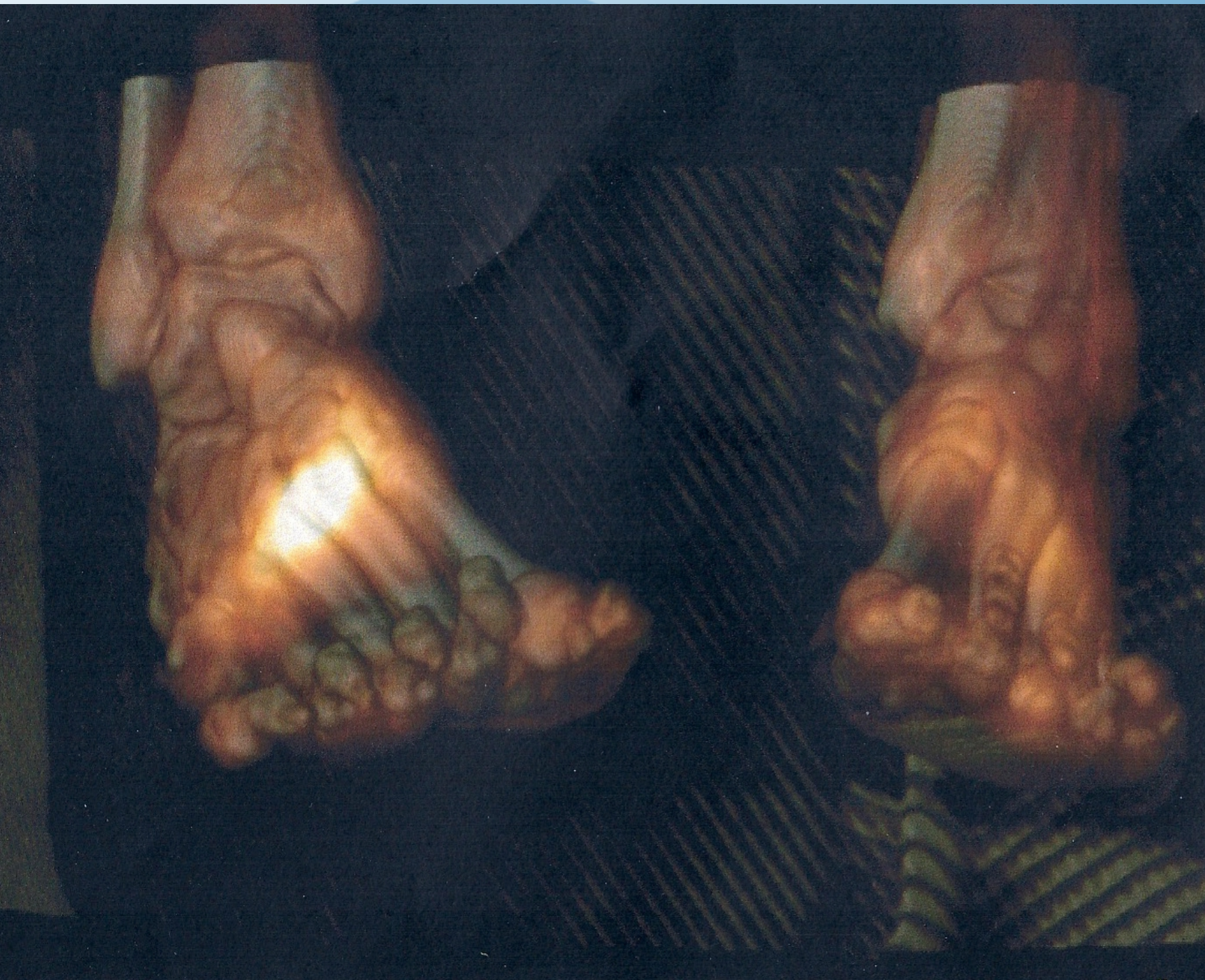

R







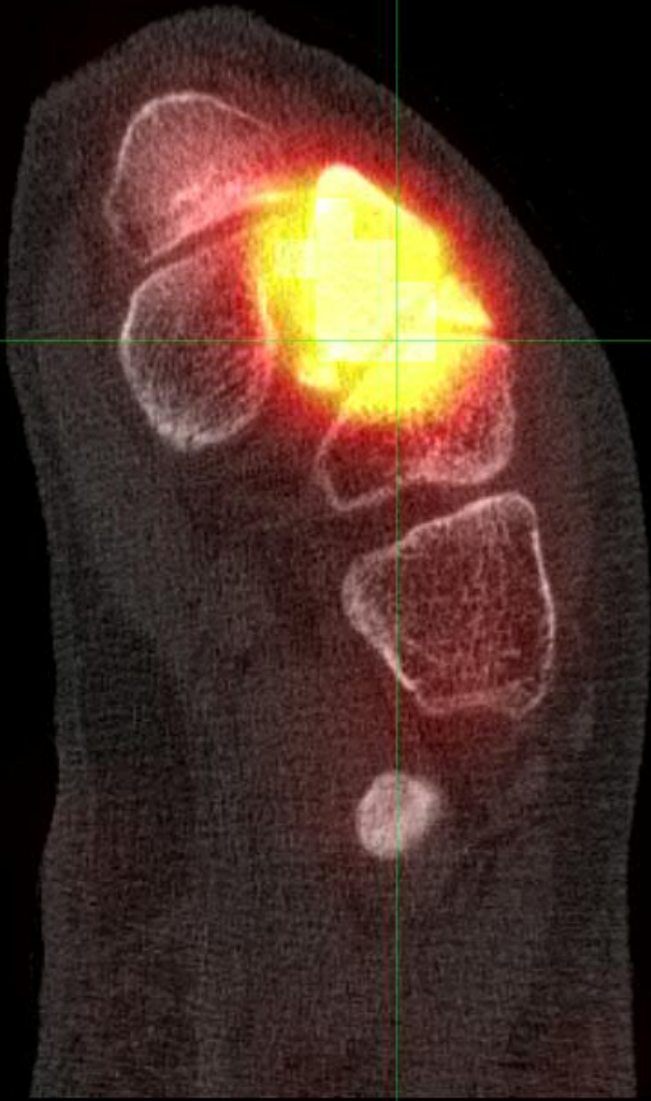

A

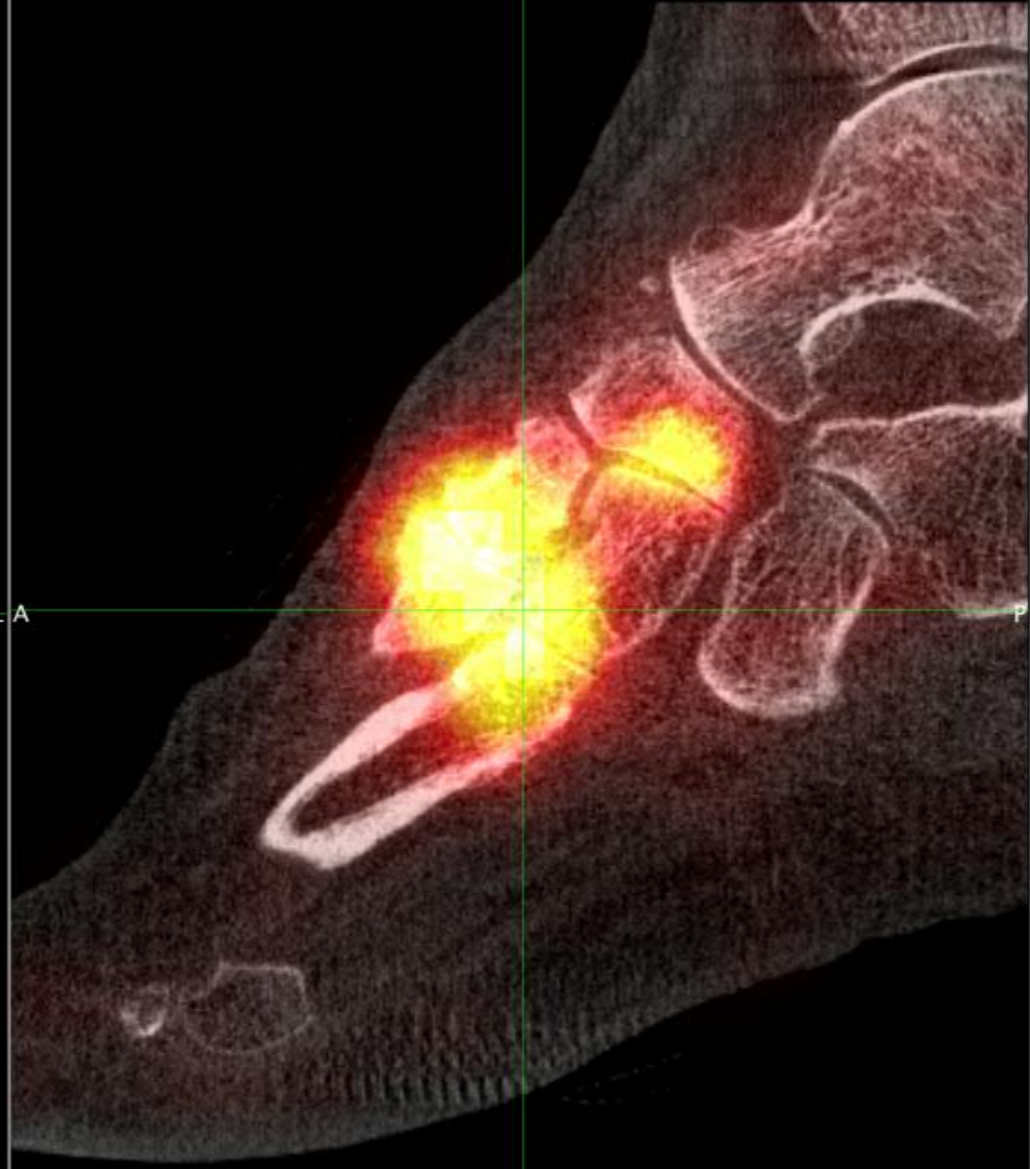
3242

S

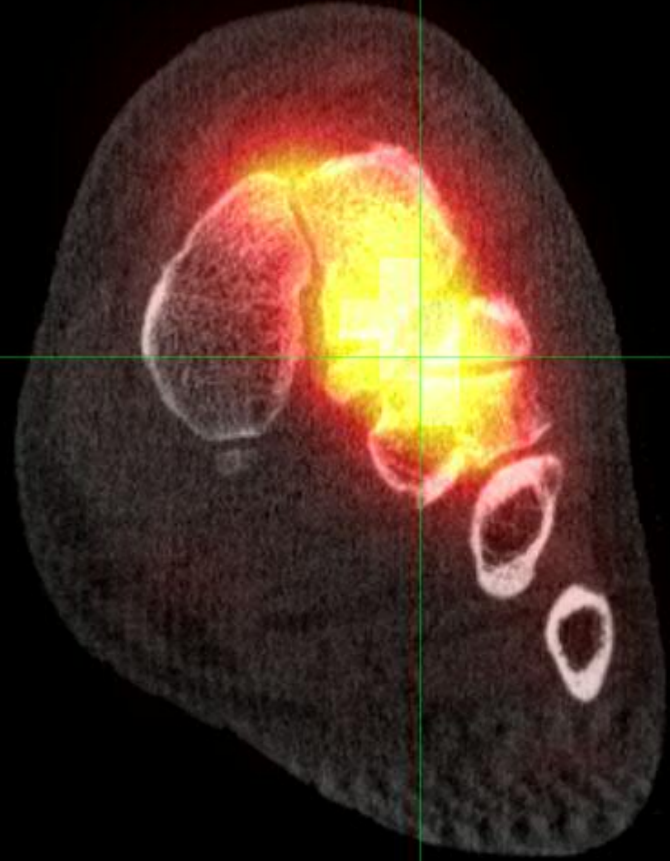
S



L A



P R

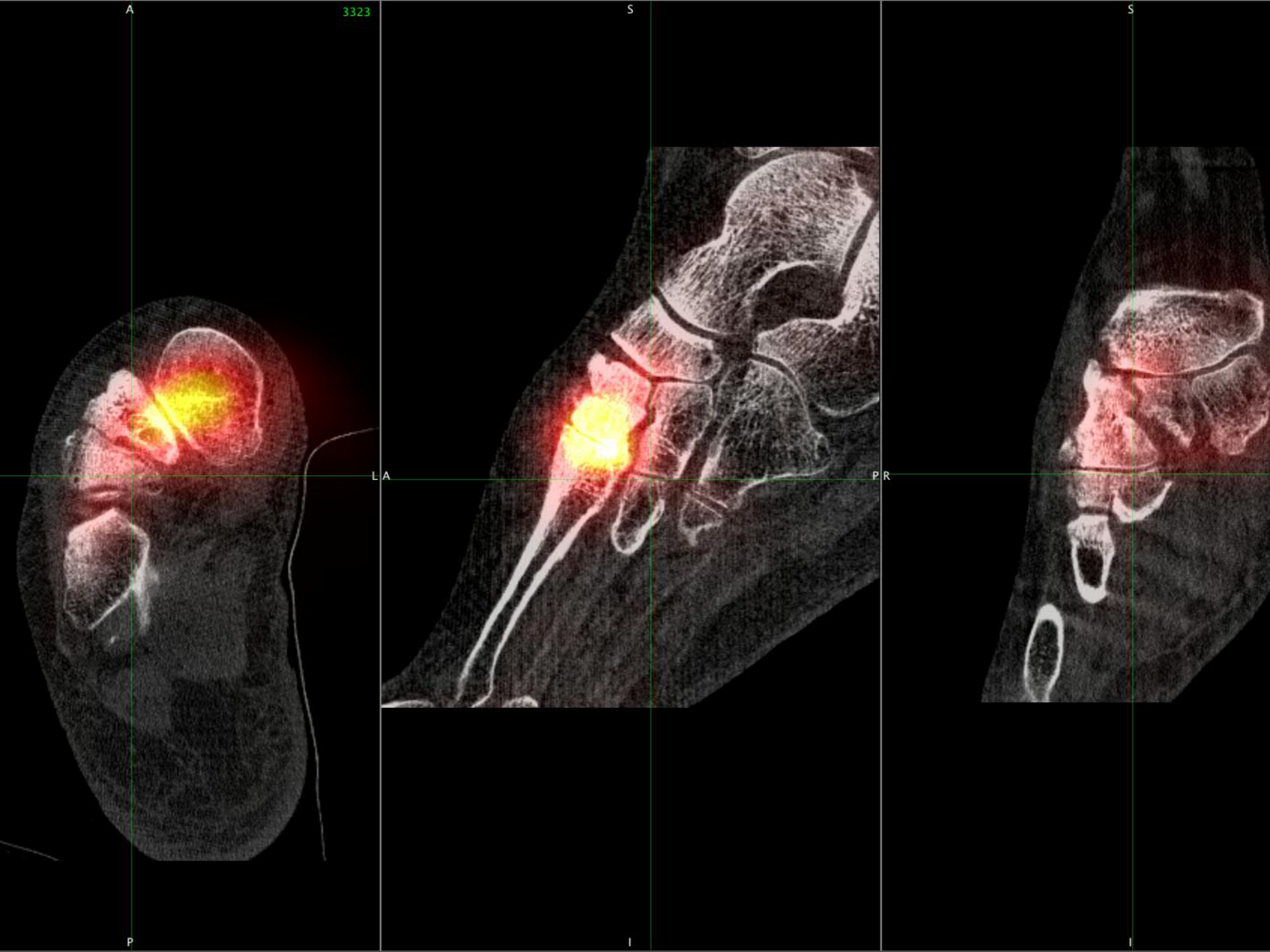


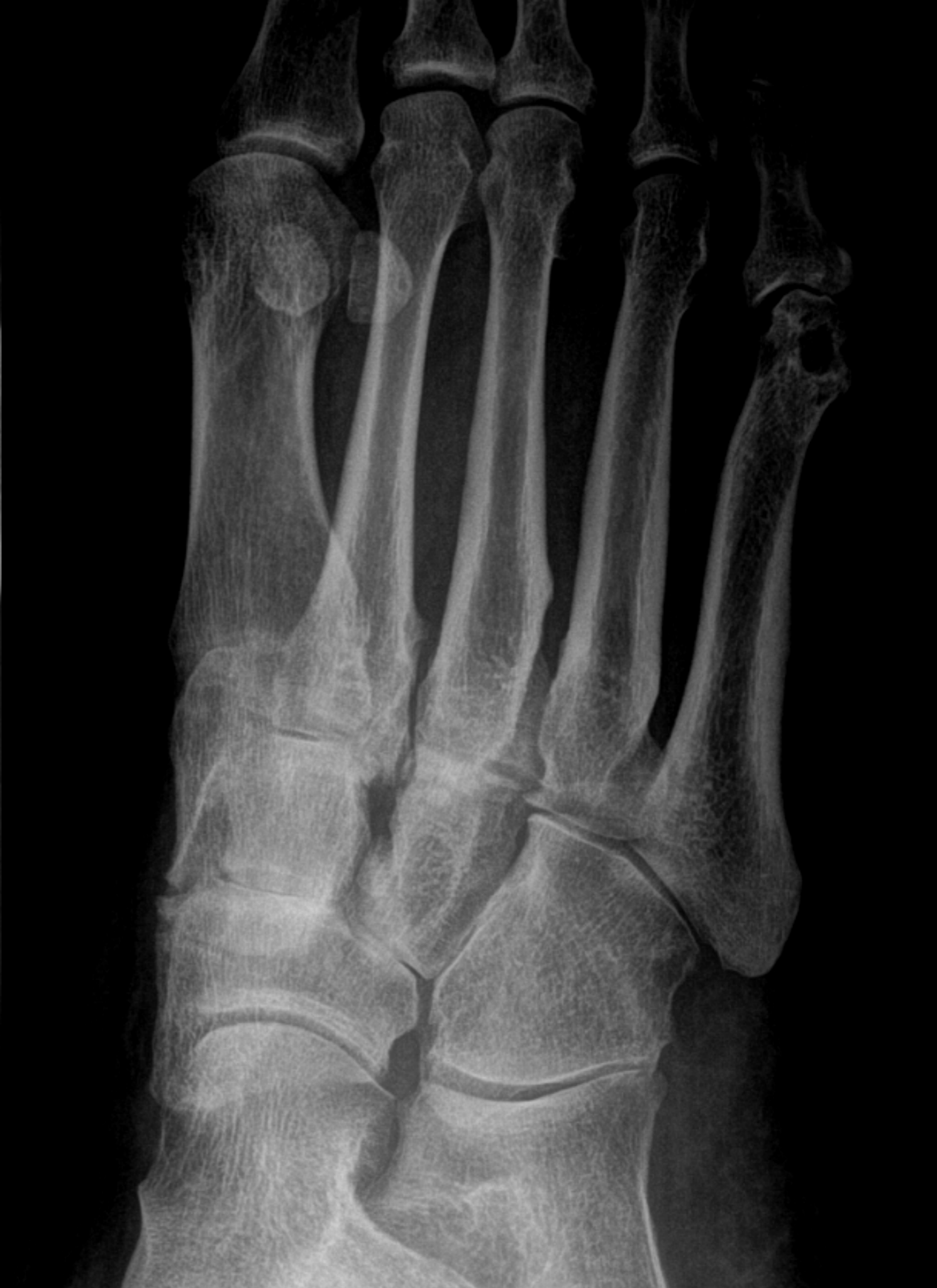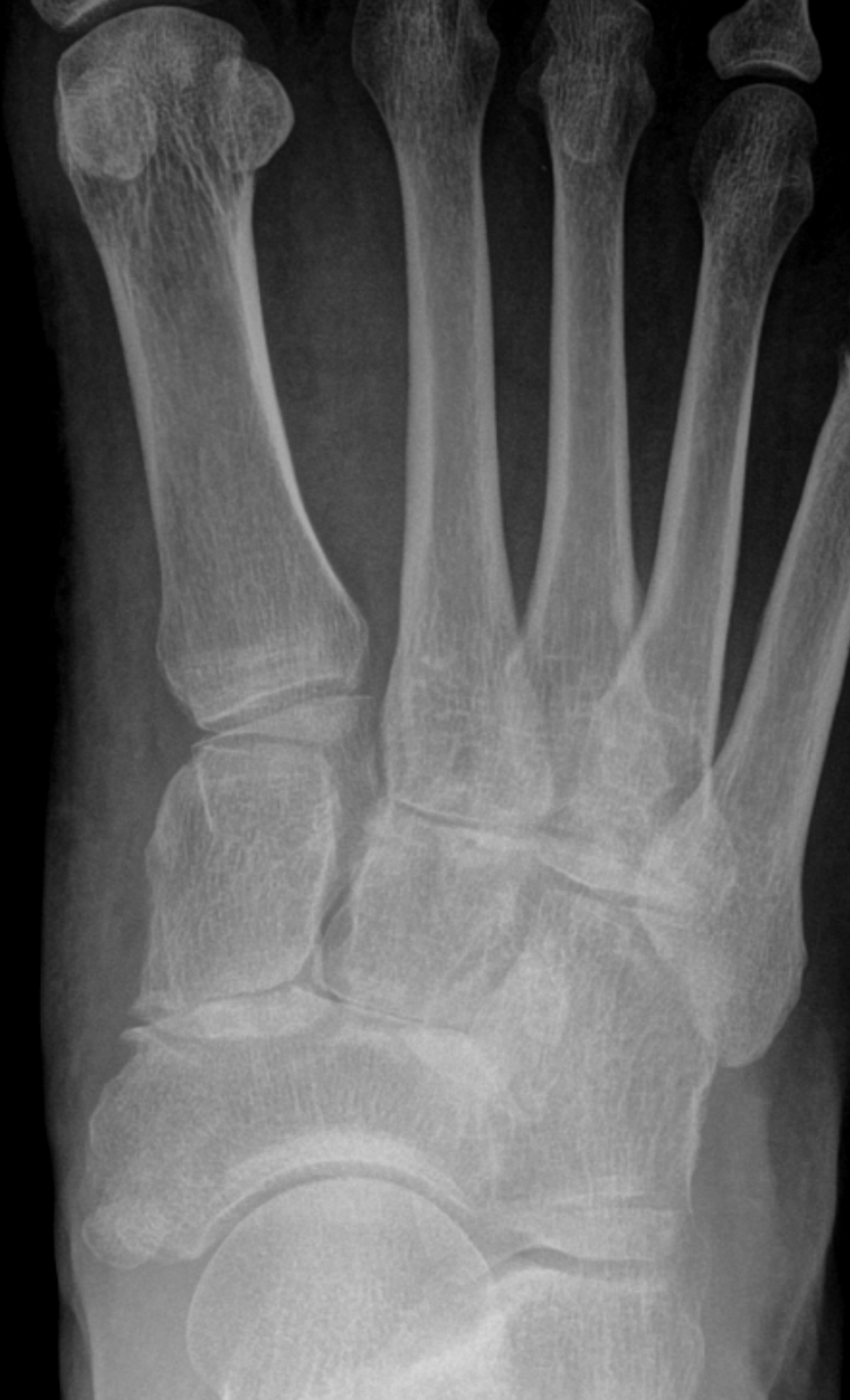P

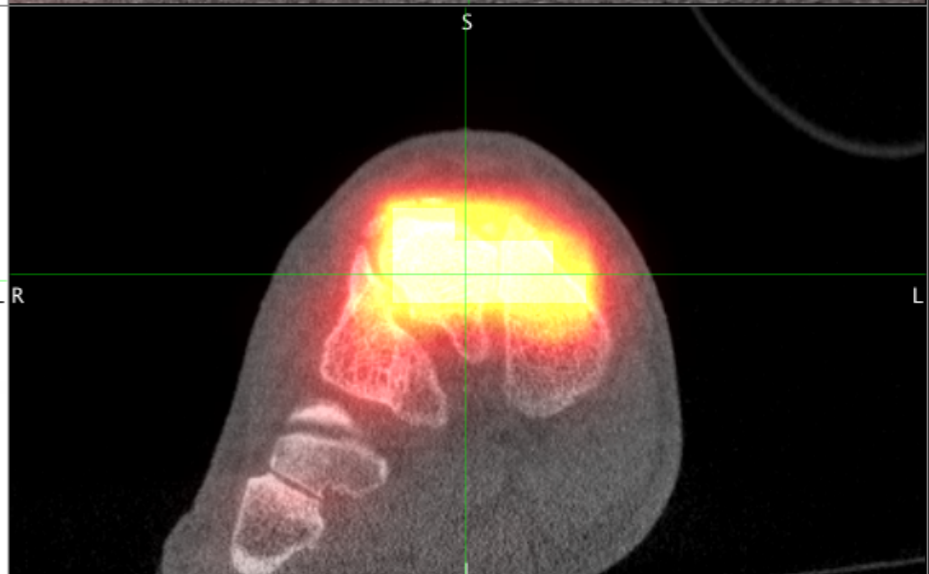

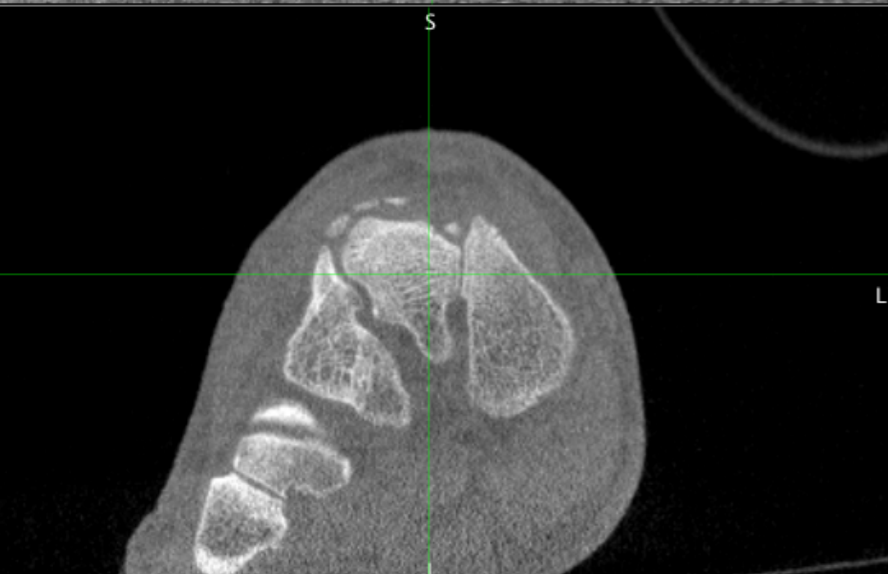
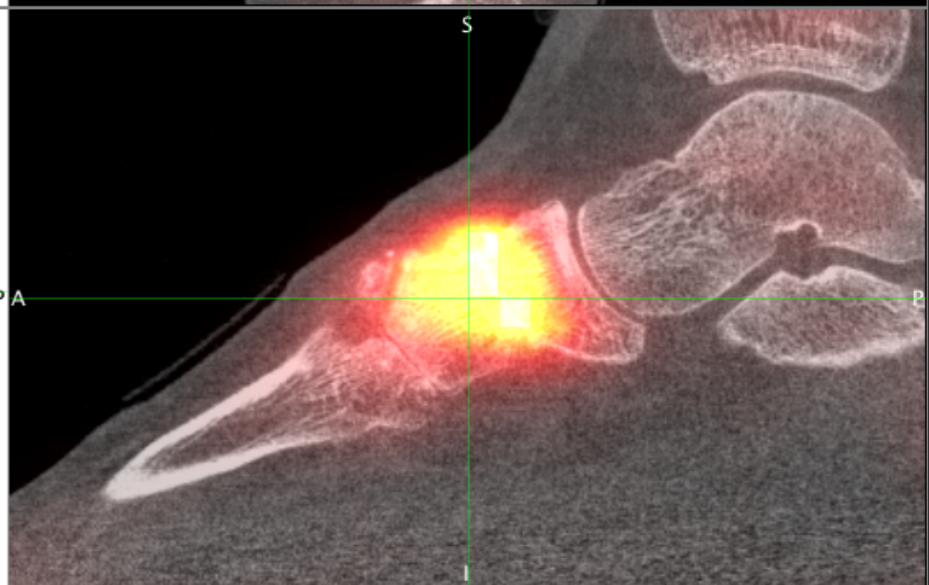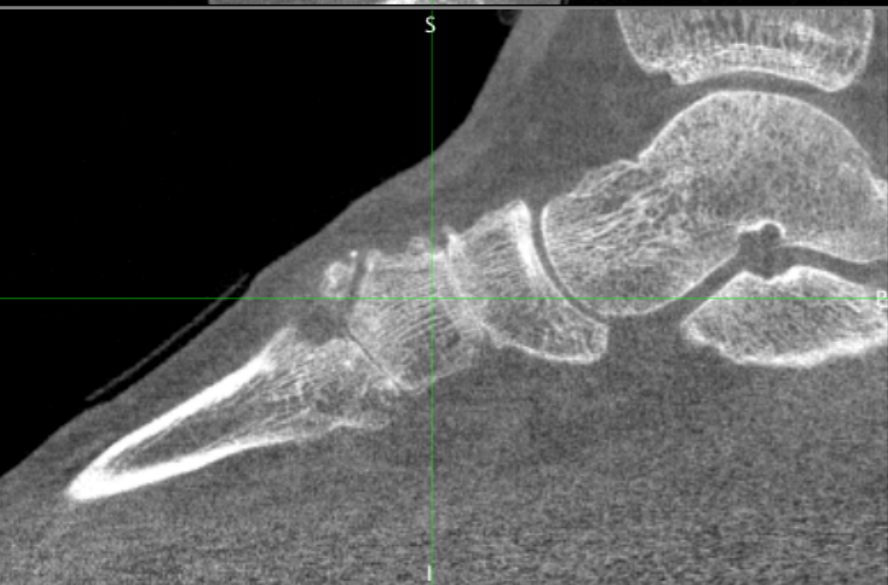

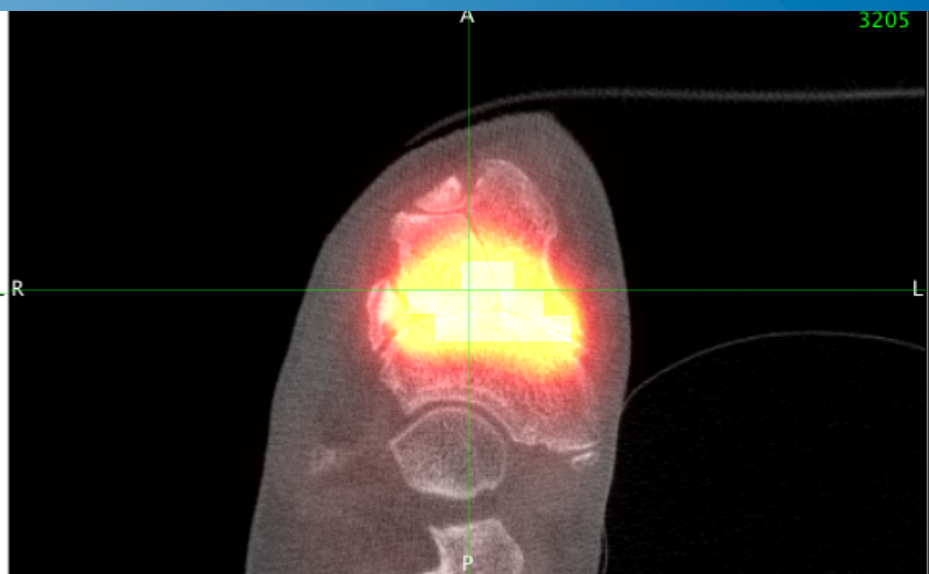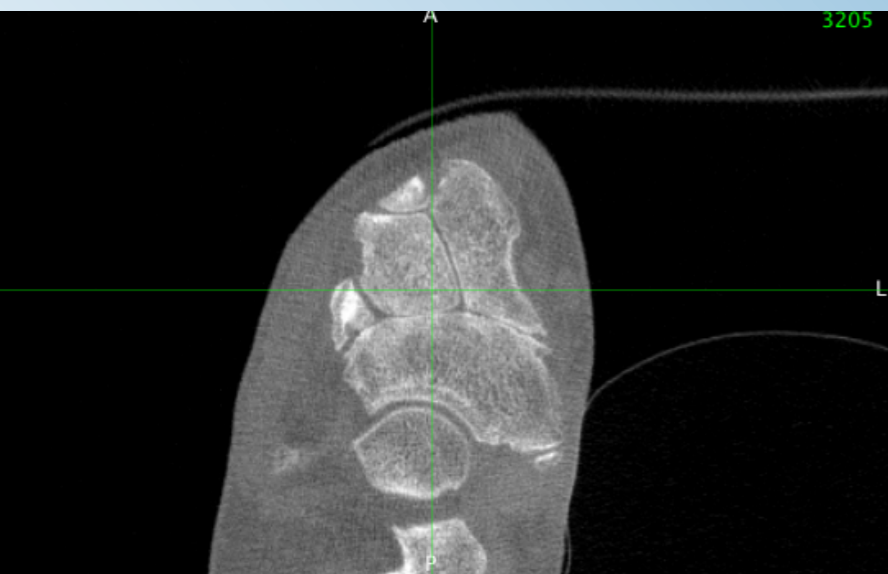

I

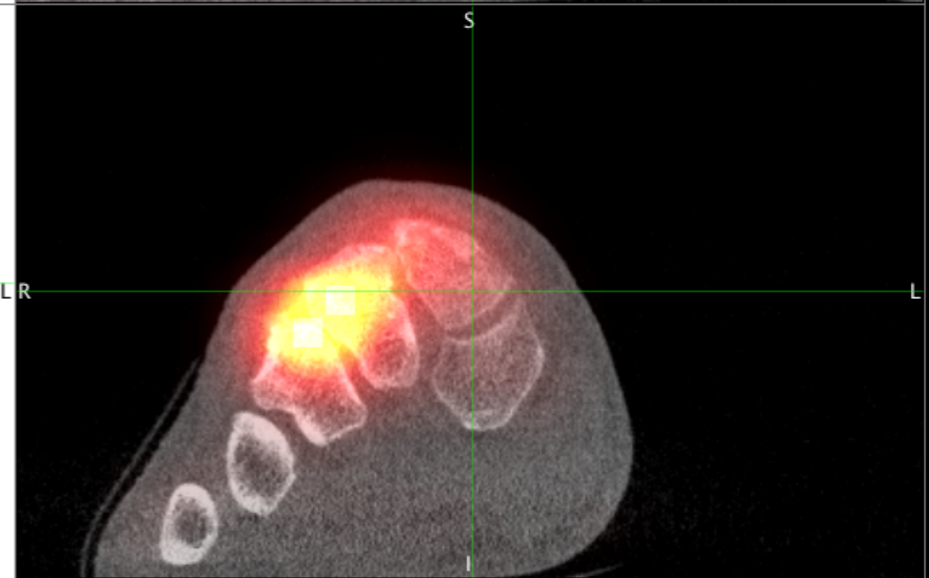
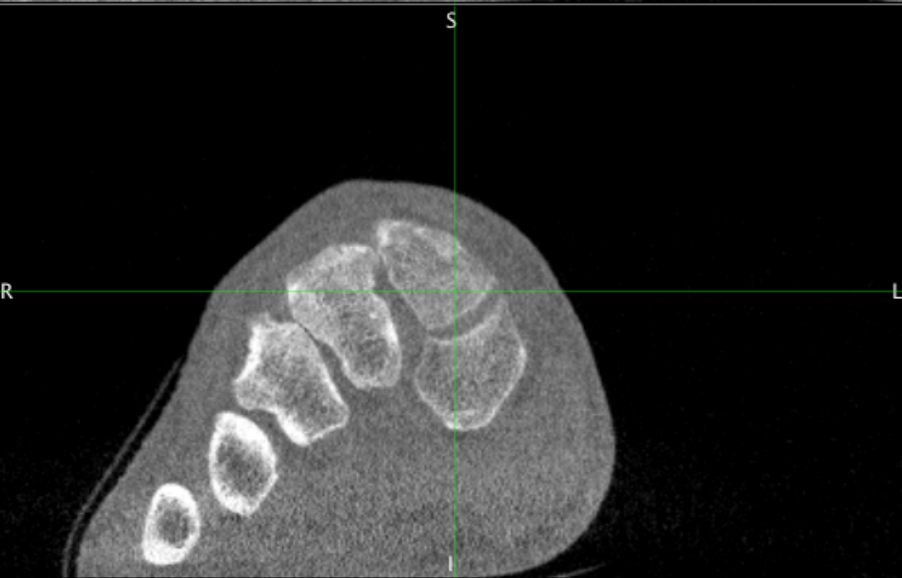
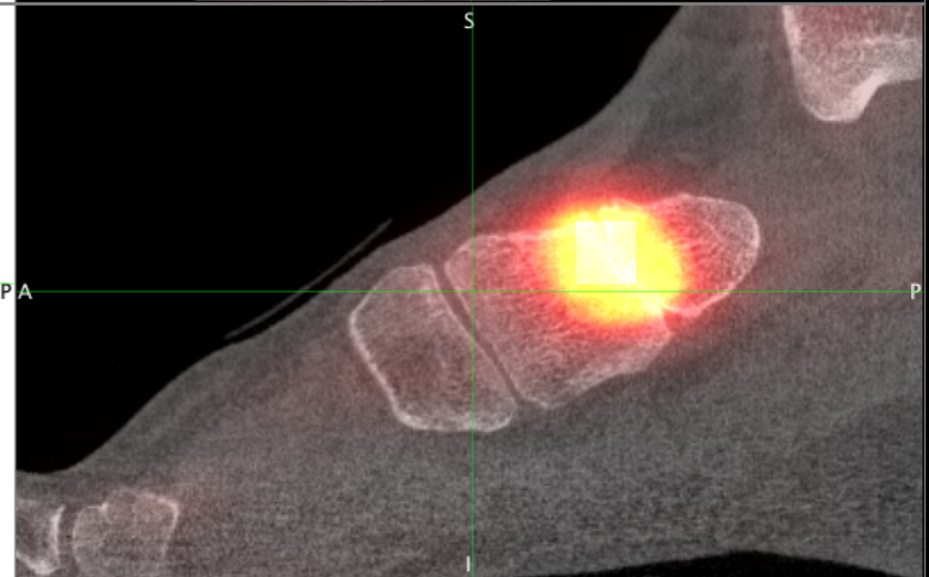
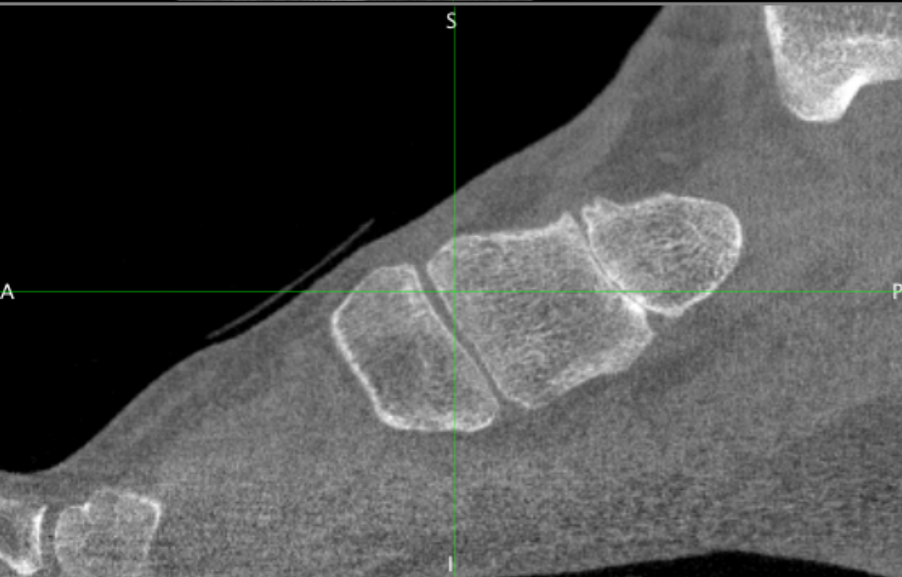
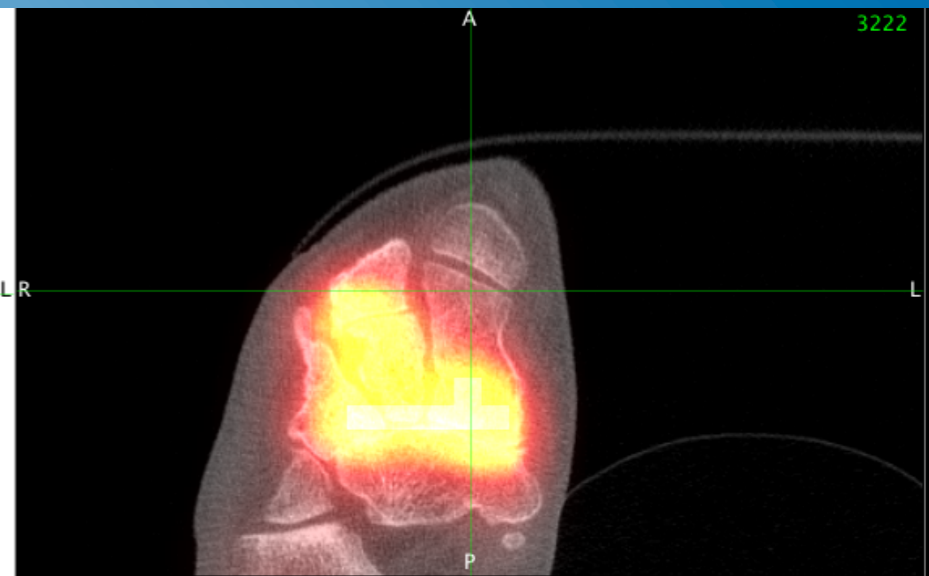

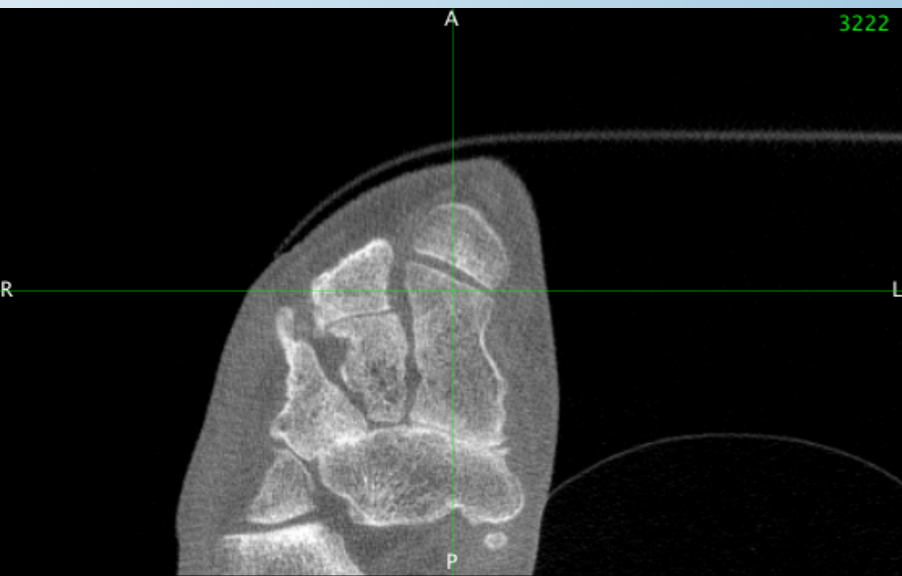
I

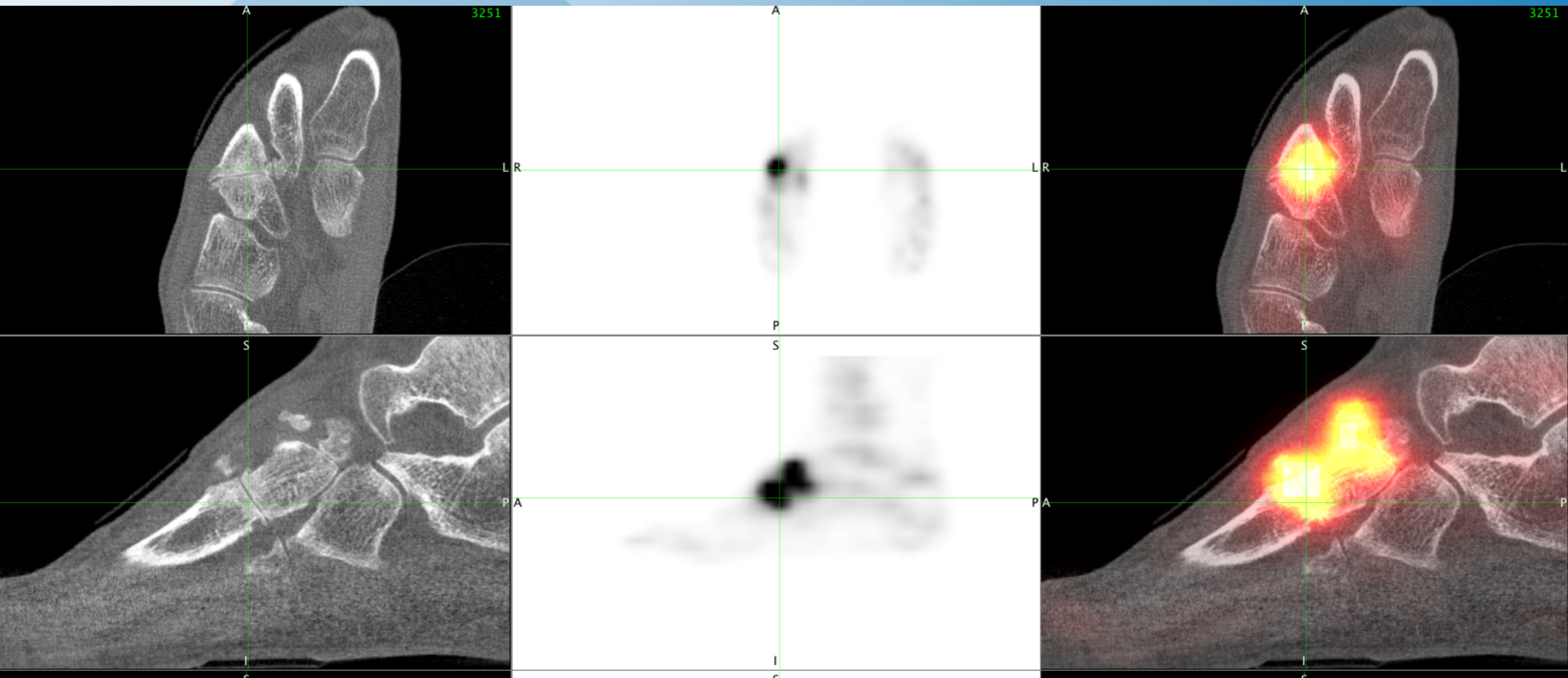
3323







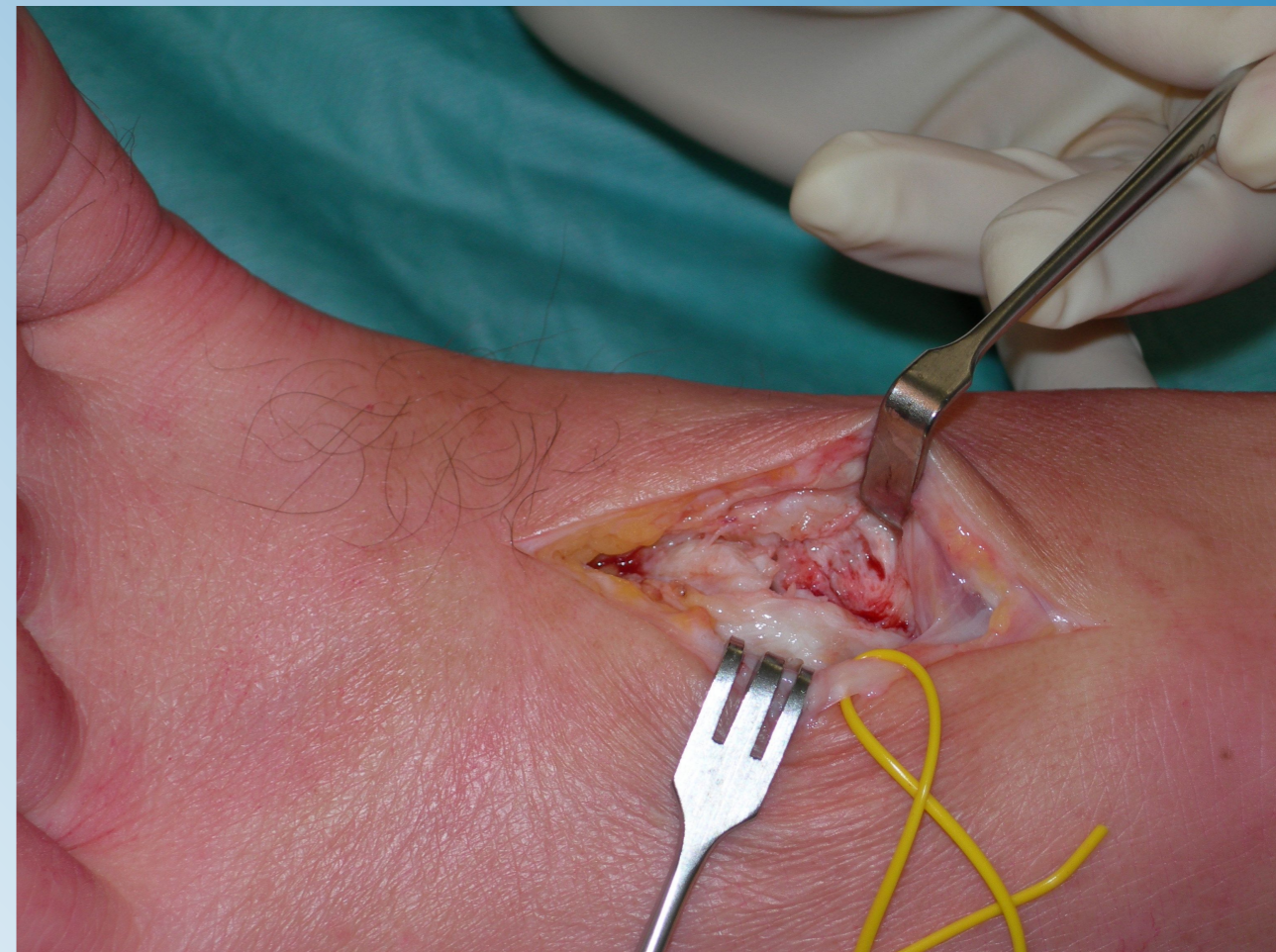
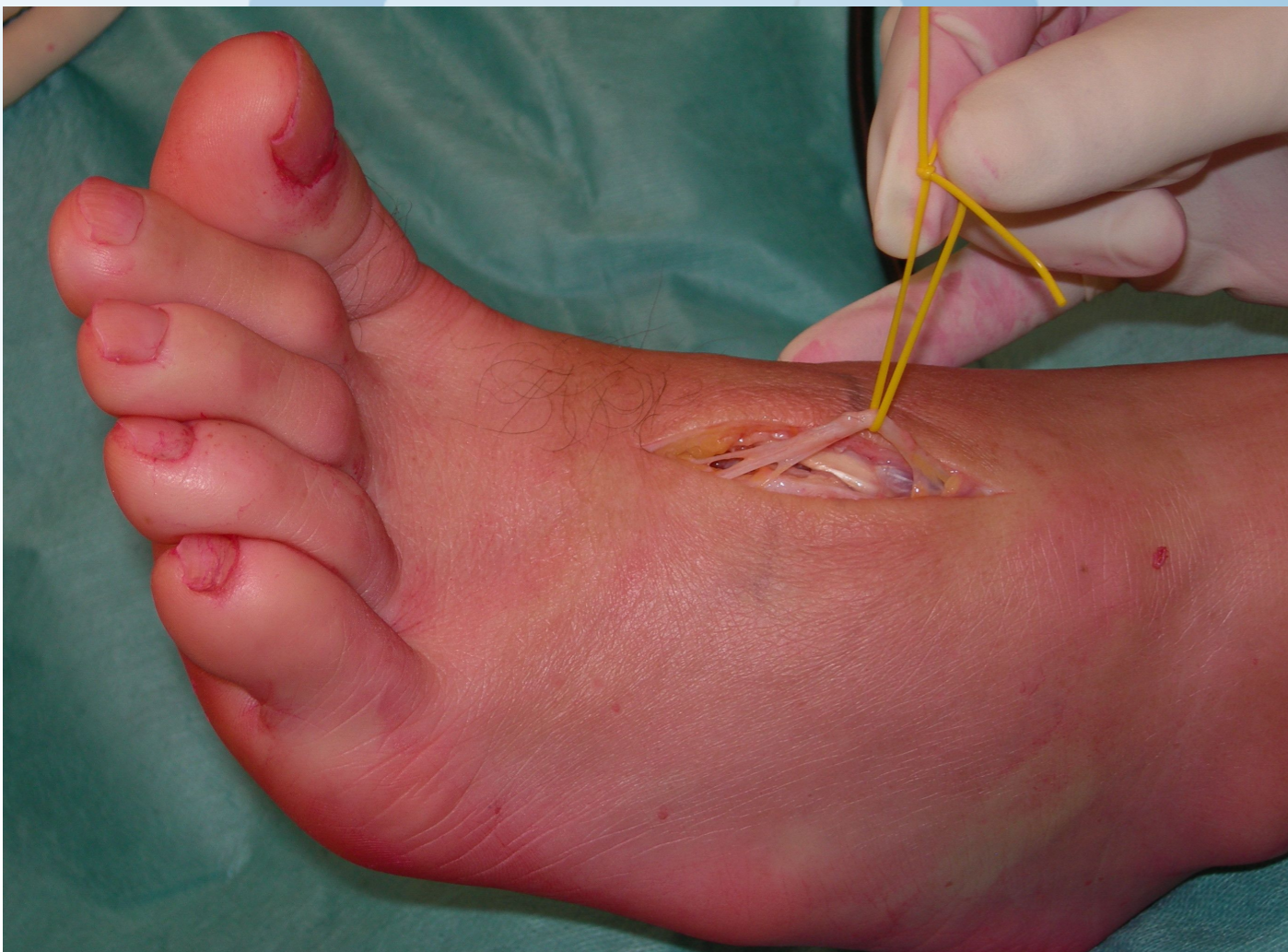


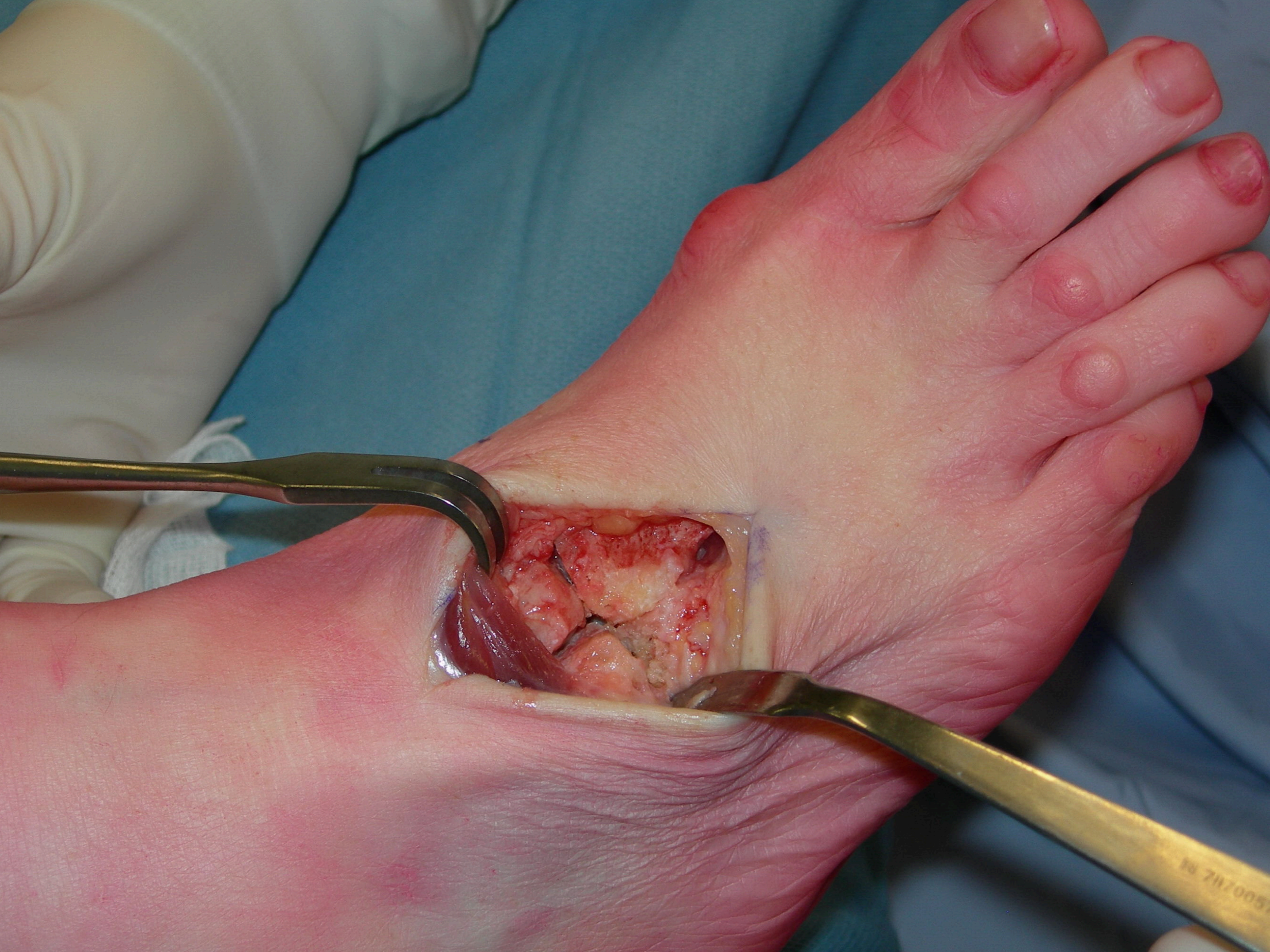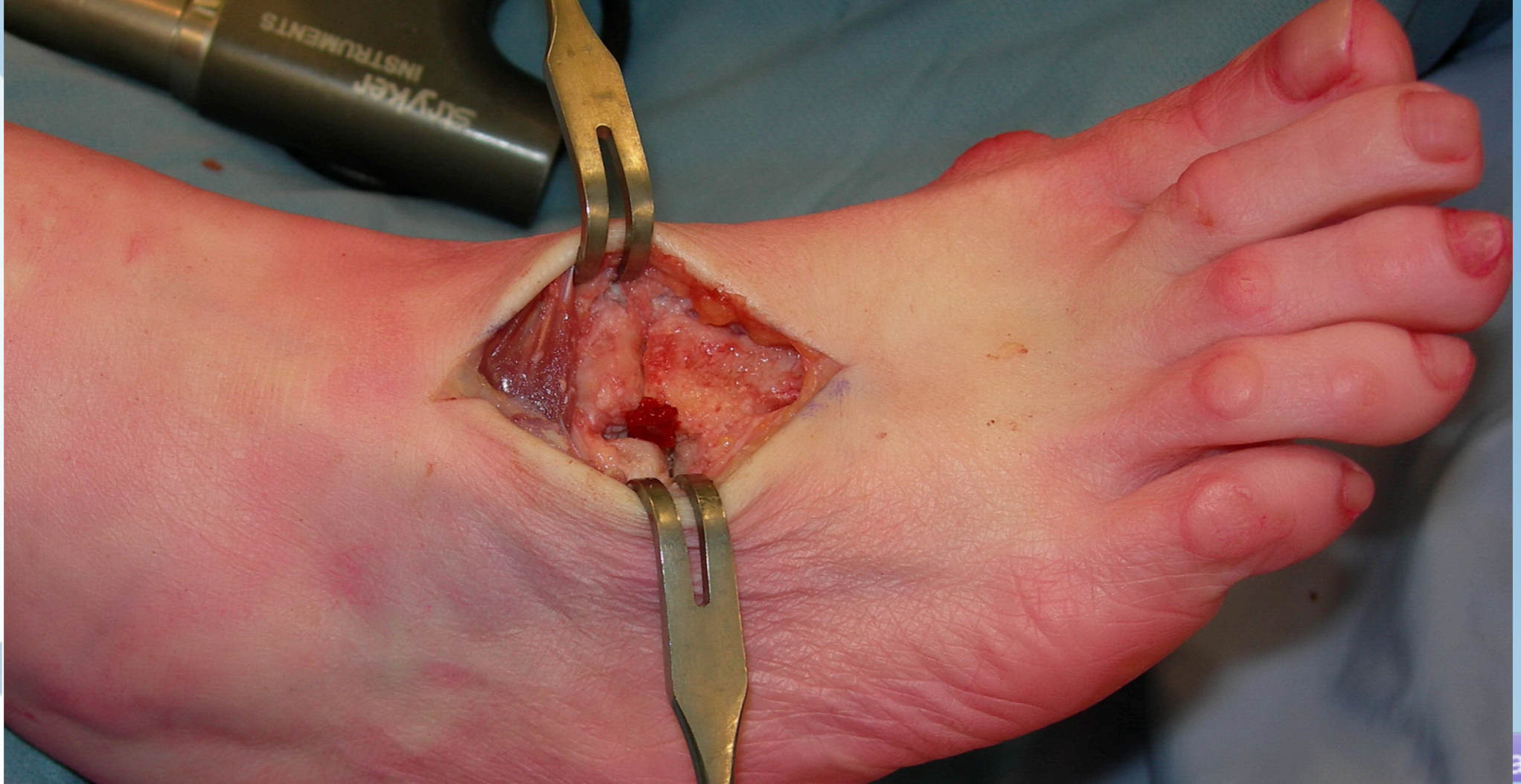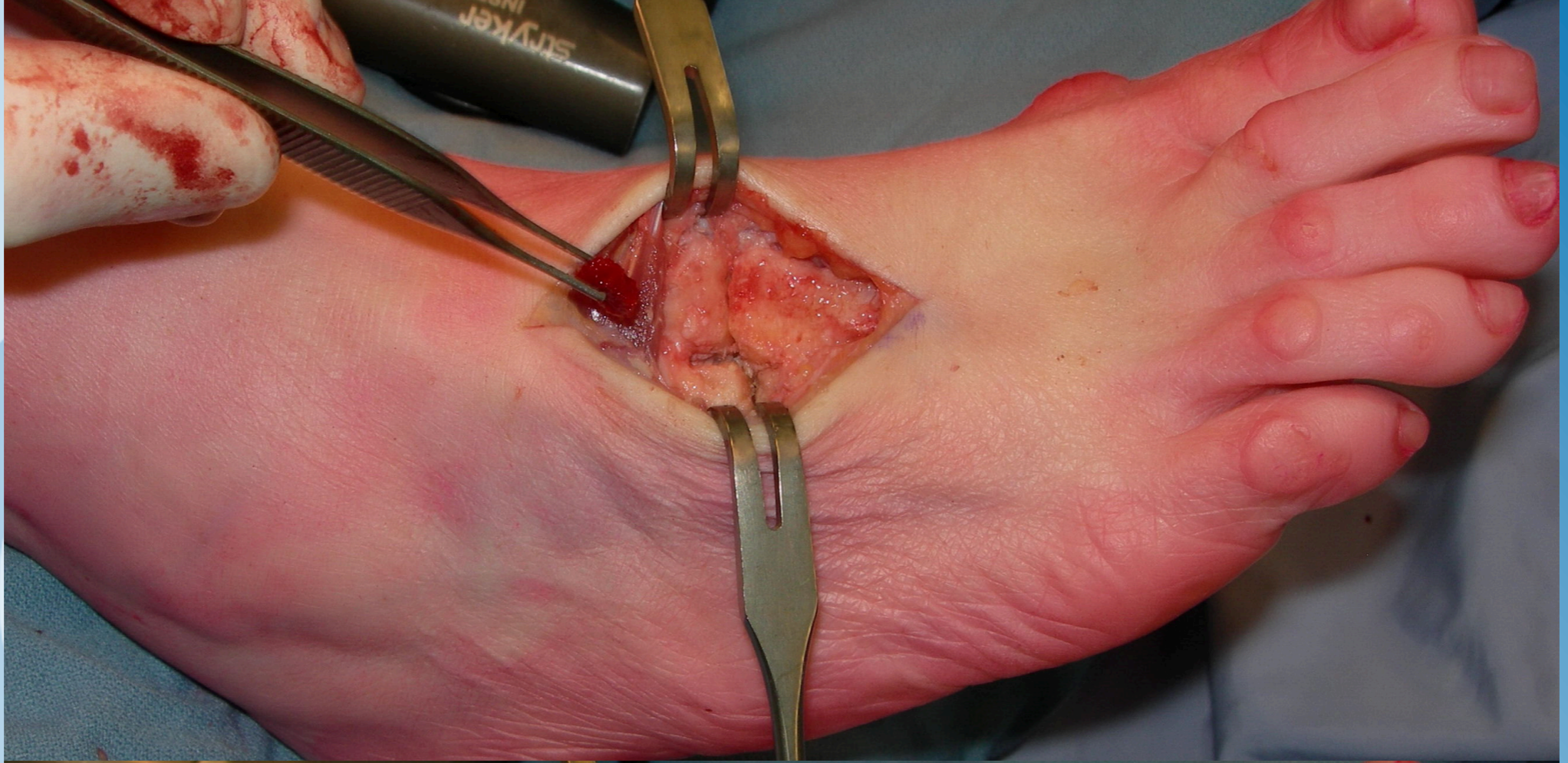
Conservative treatment

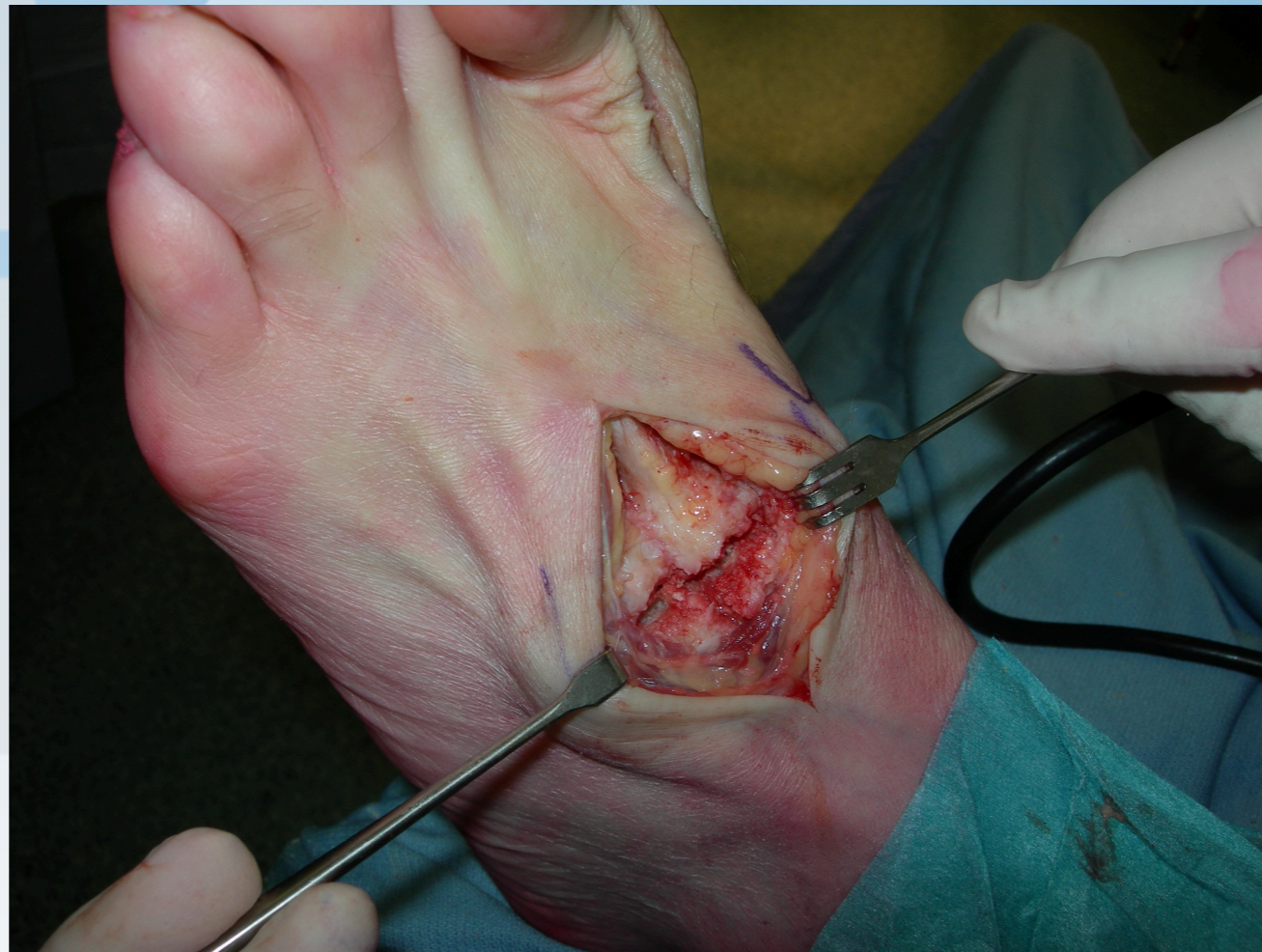

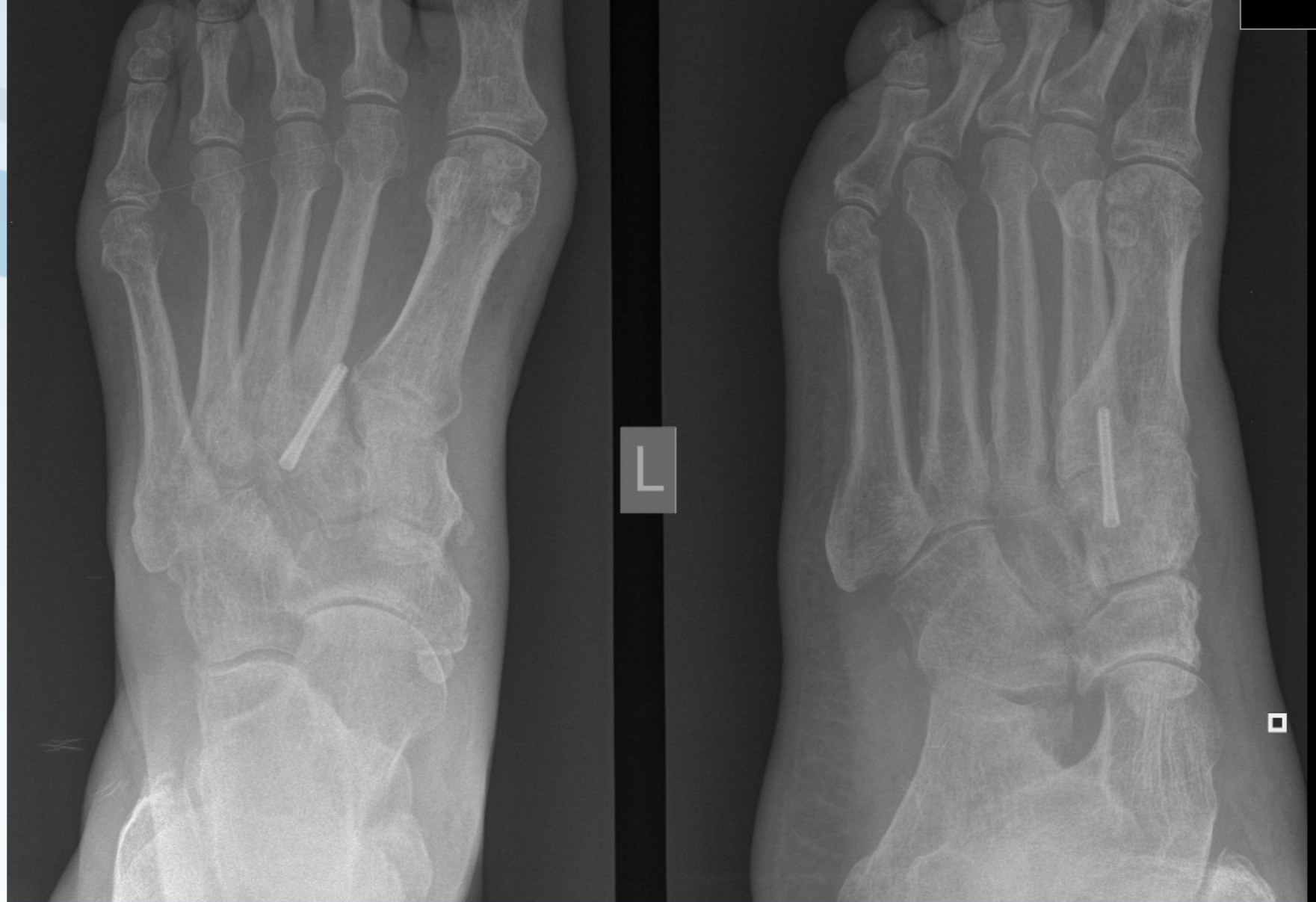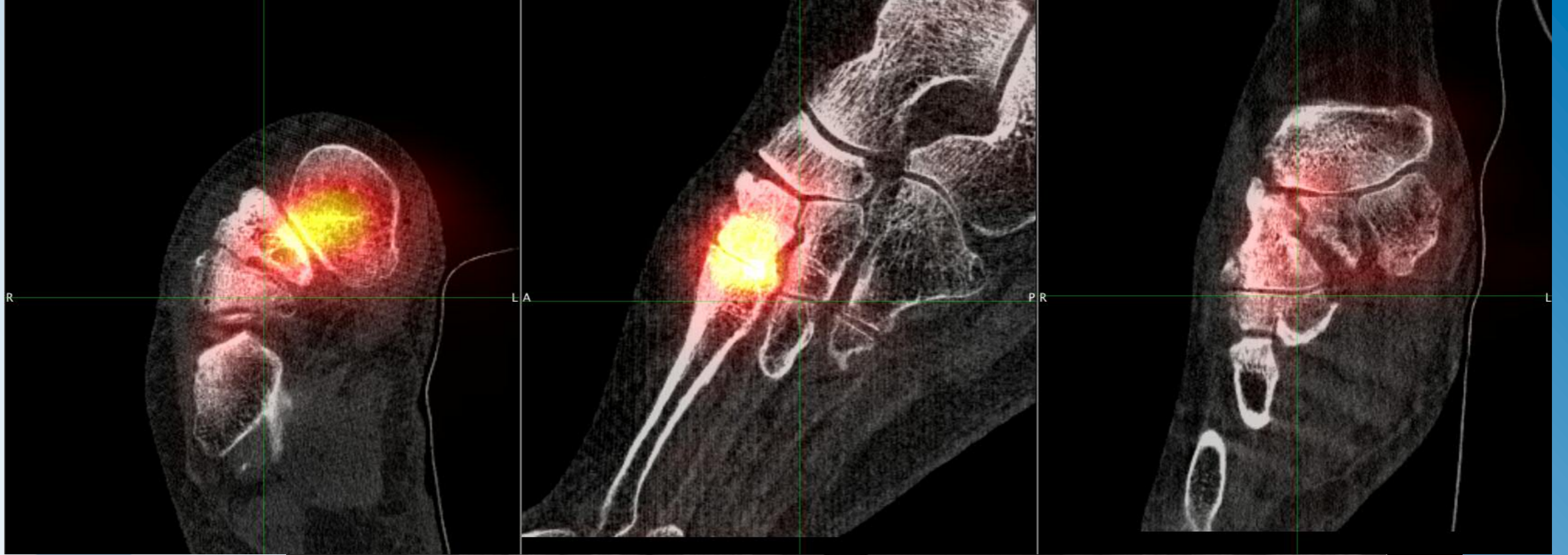Operative treatment

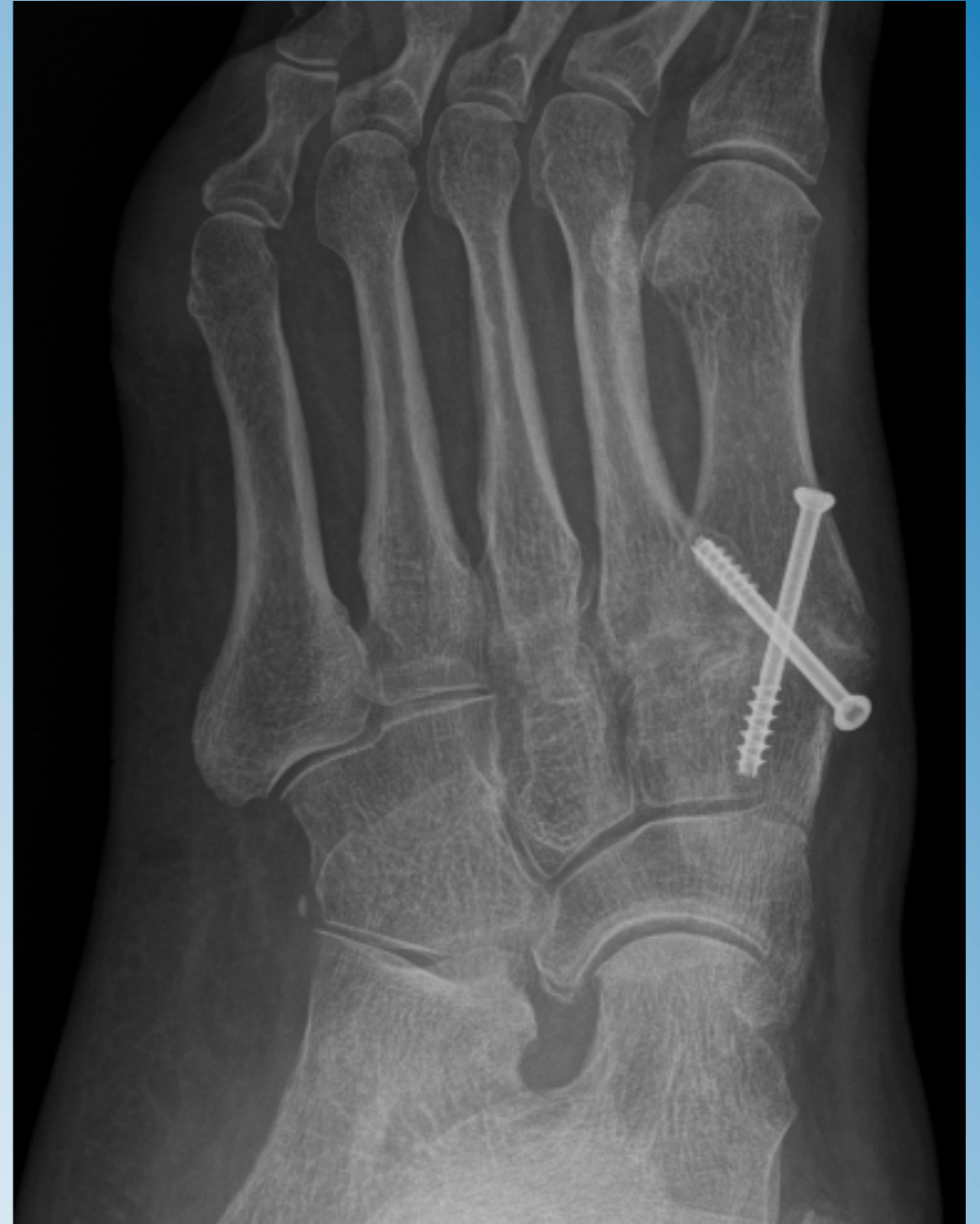
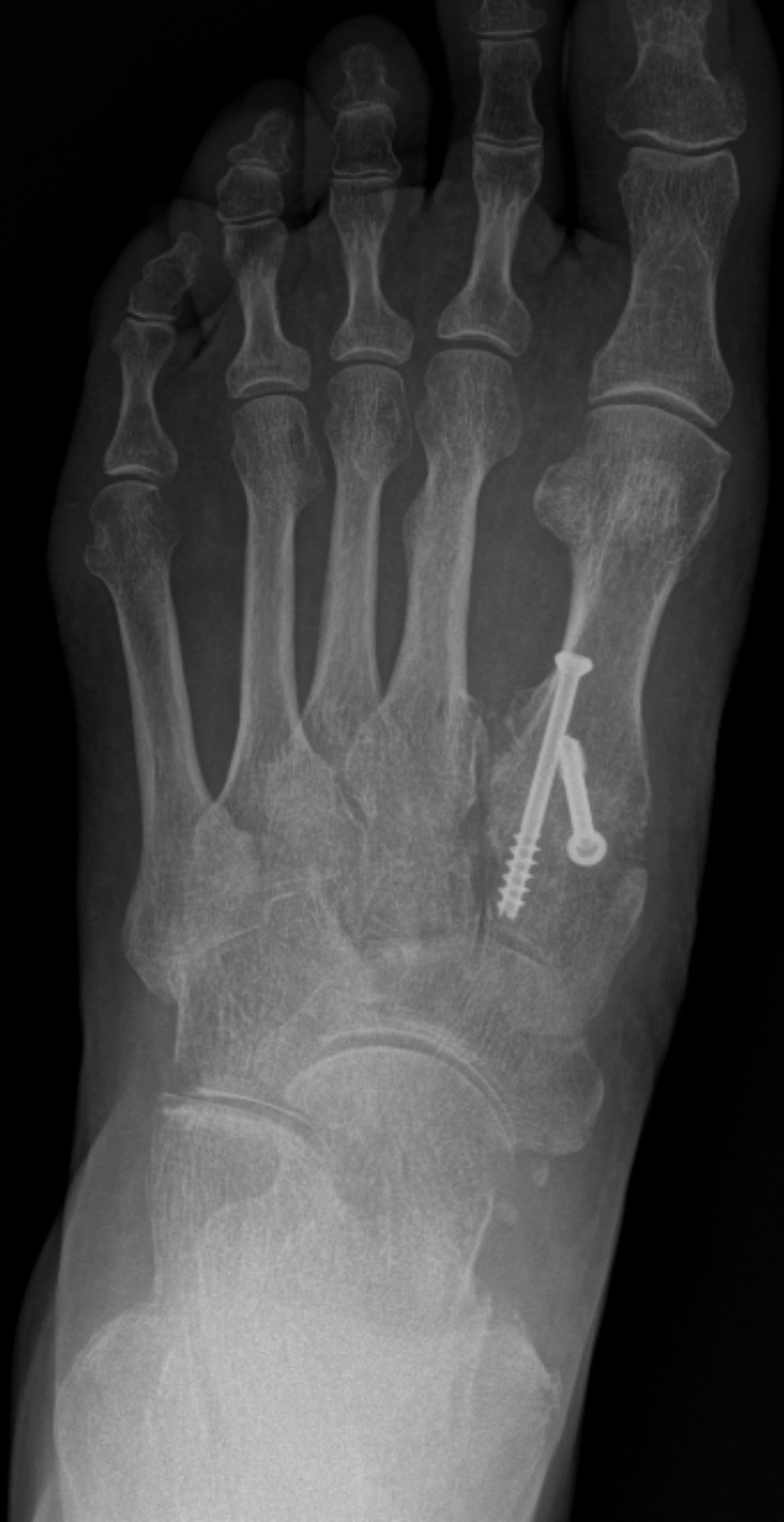




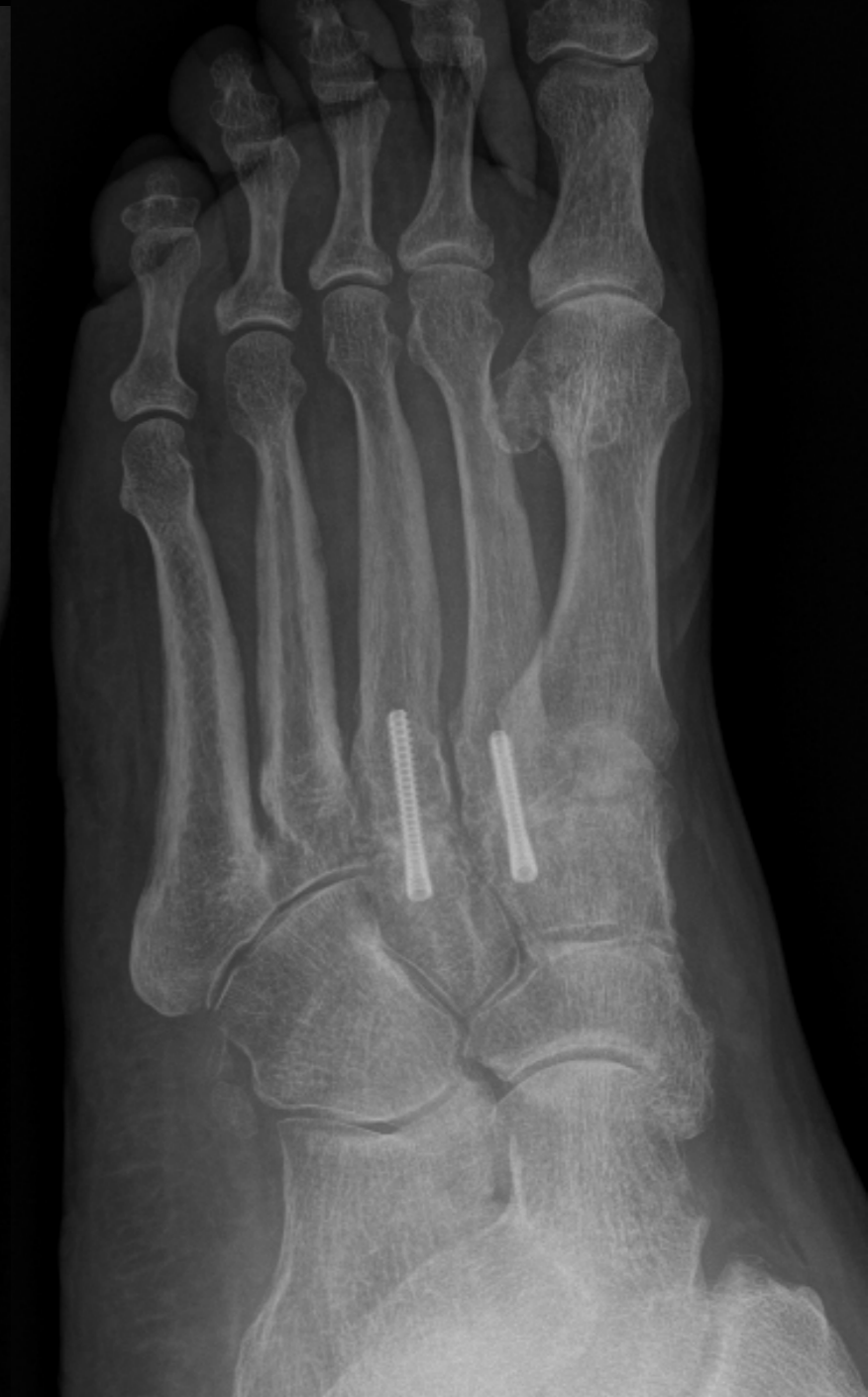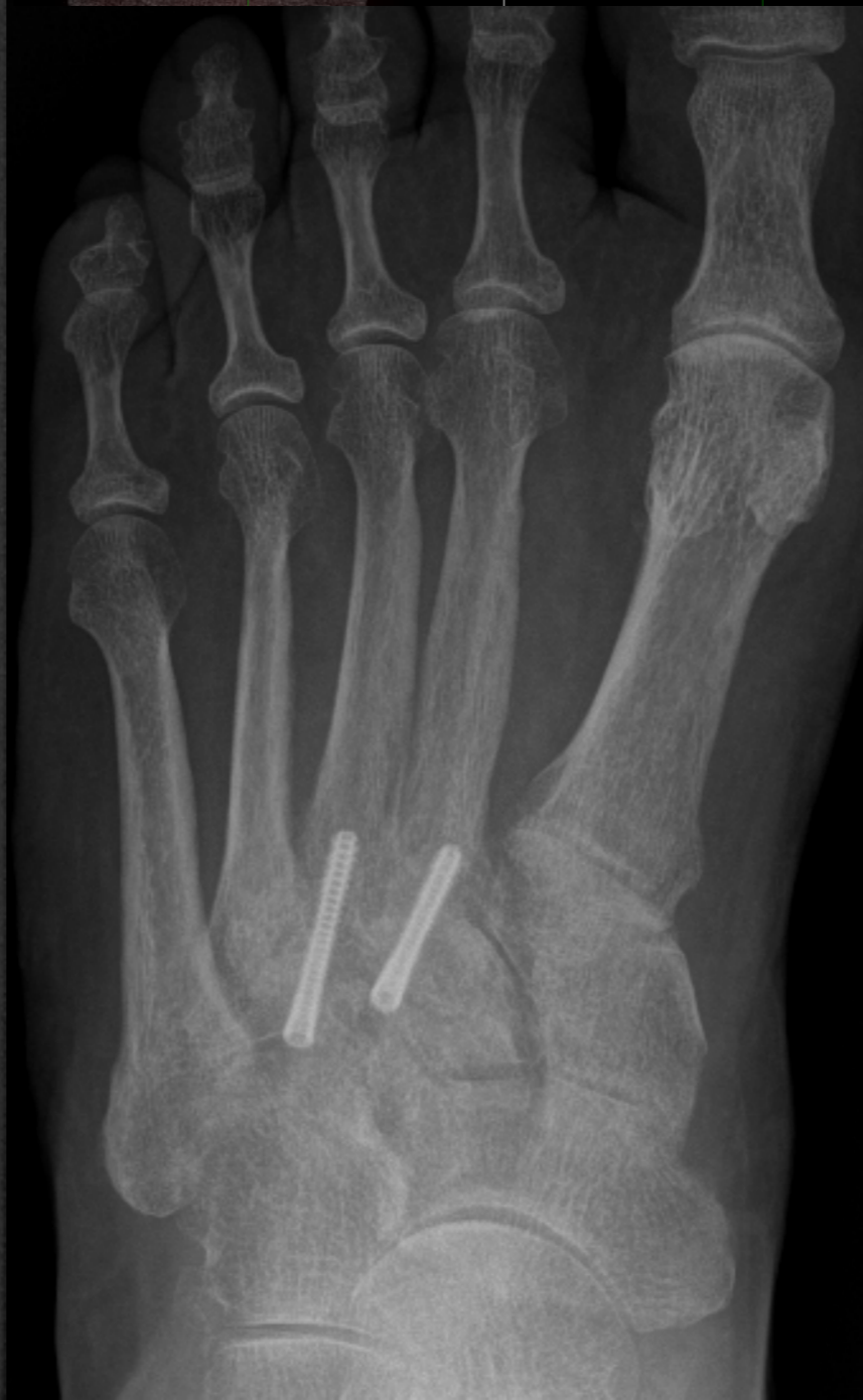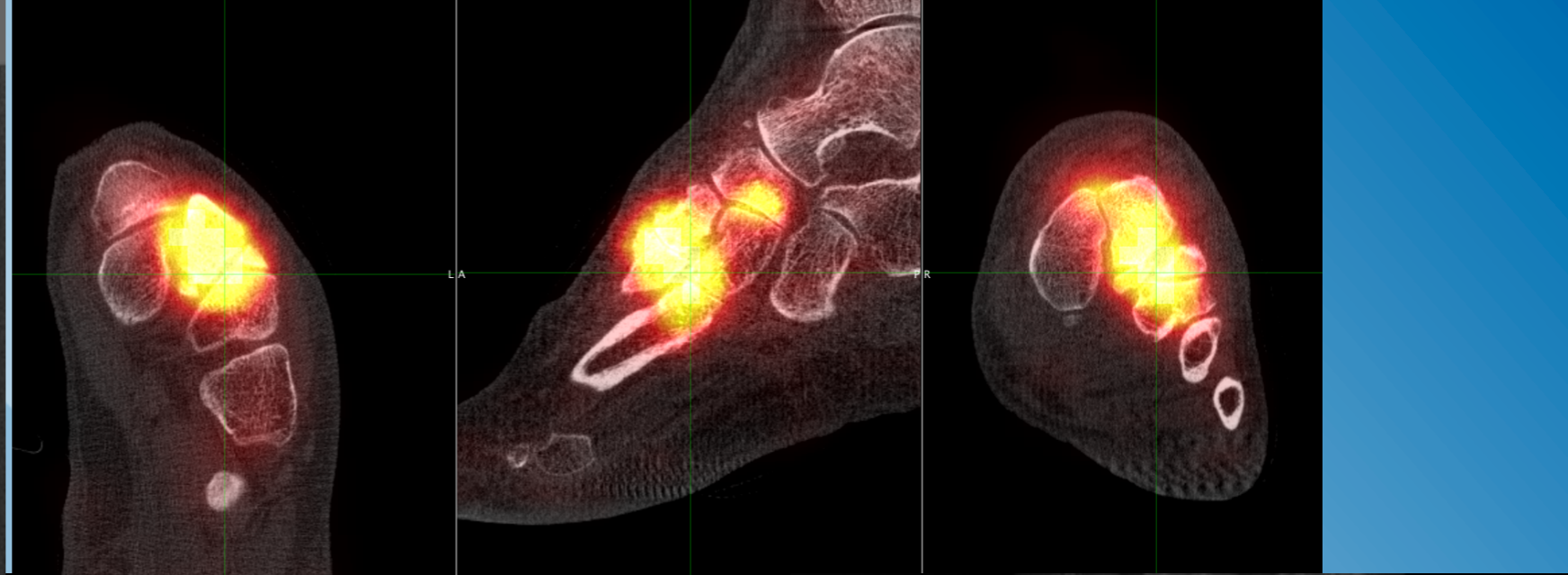




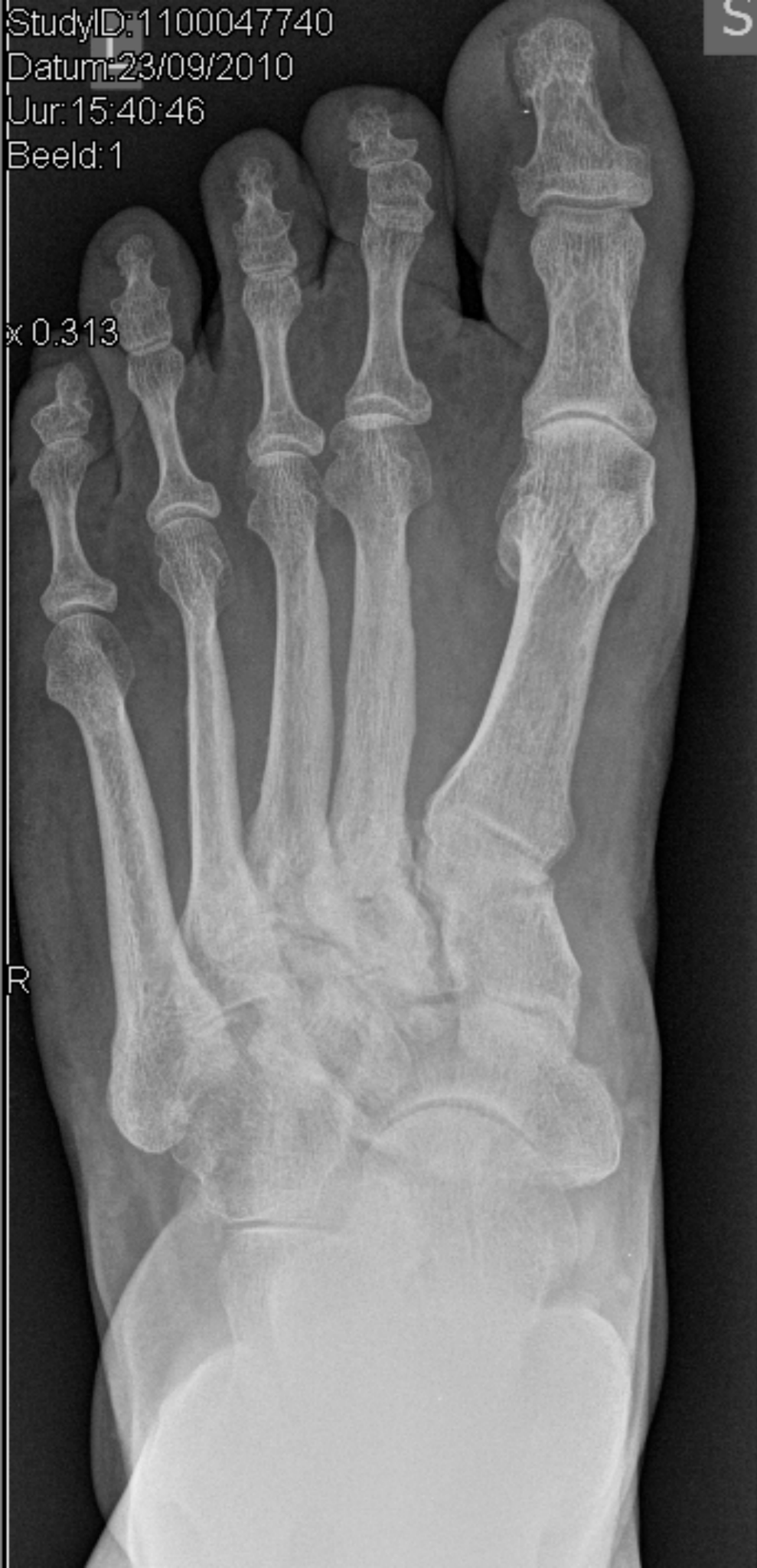

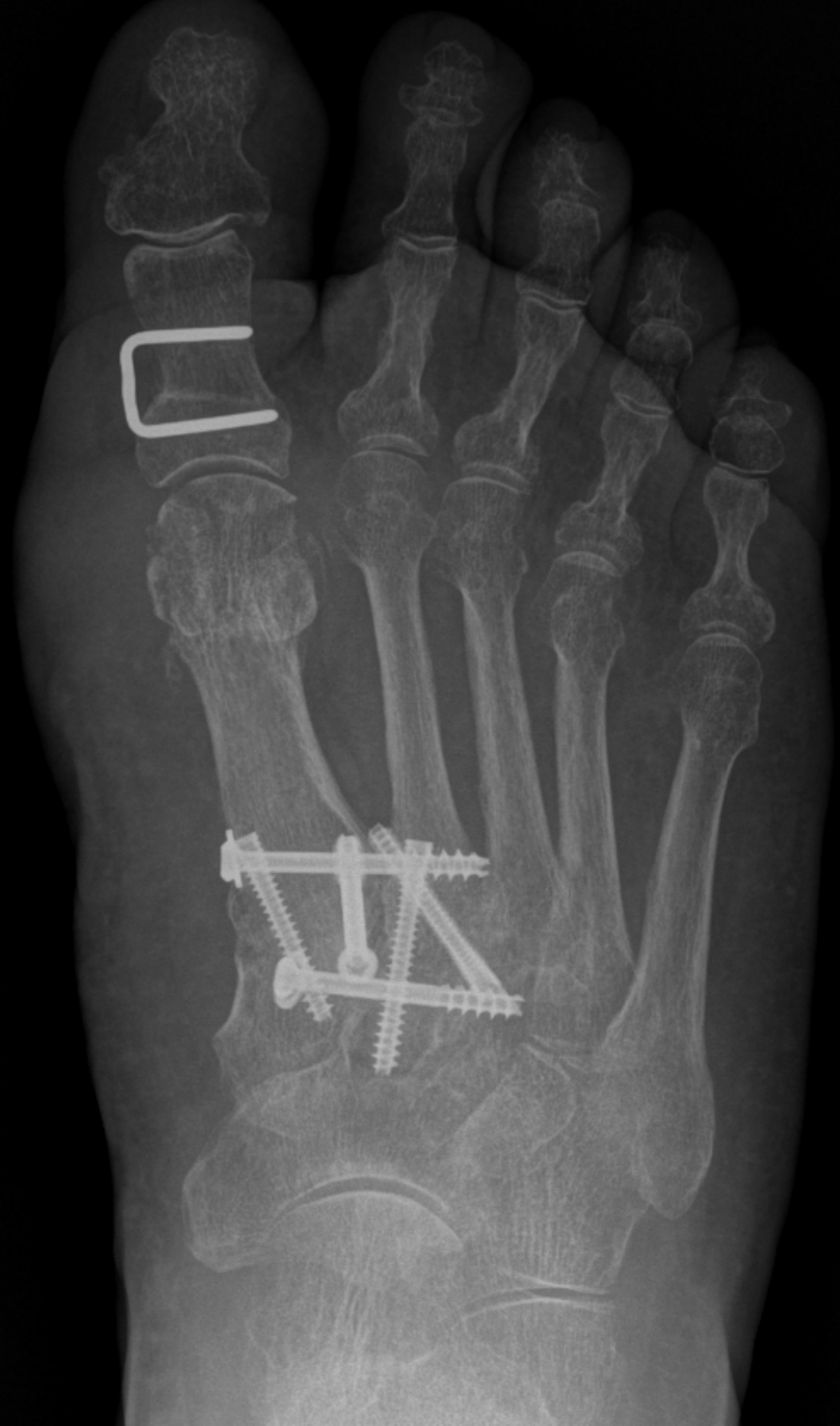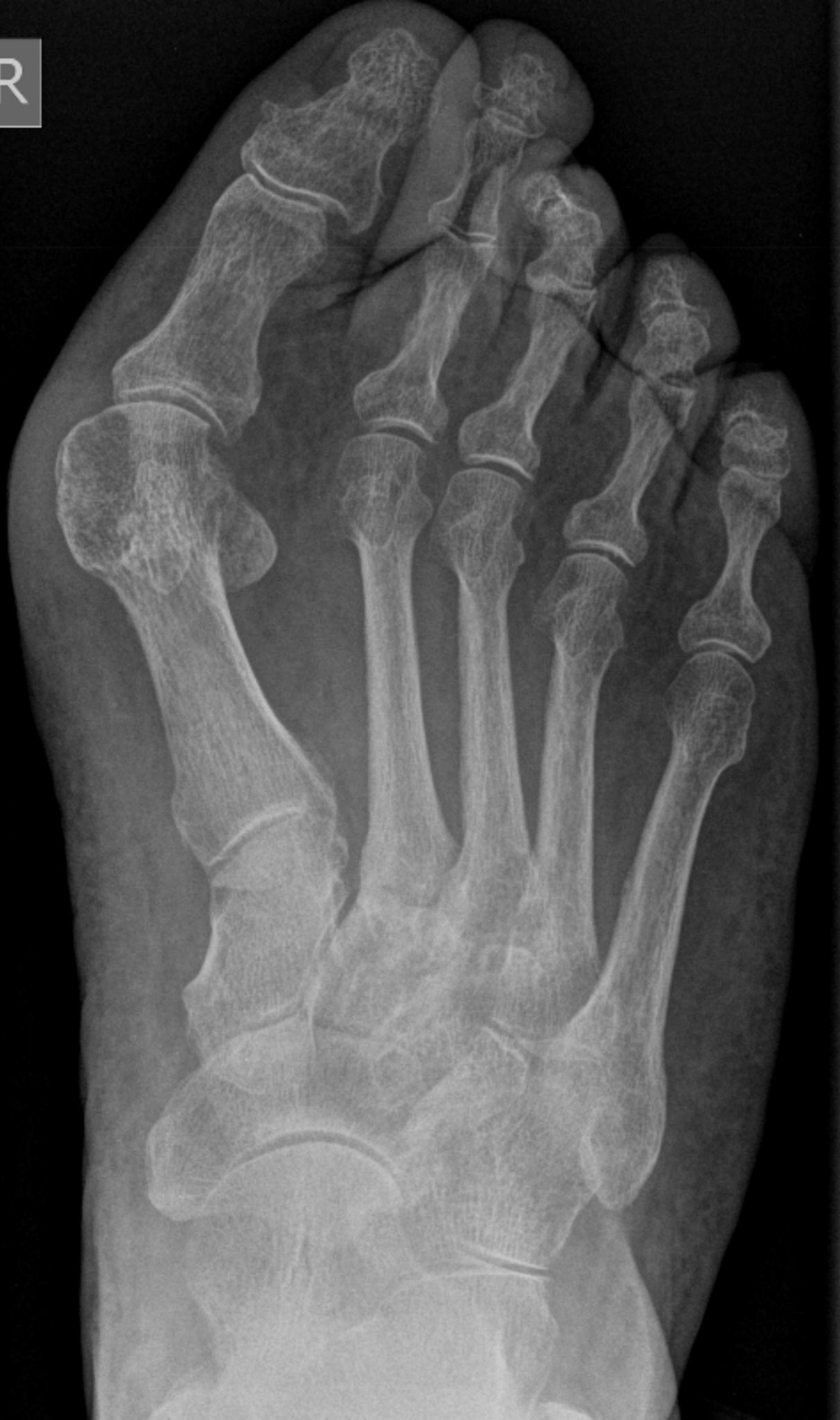StudyID: 1100047740
Datum: 23/09/2010
Uur: 15:40:46
Beeld: 1

x 0.313

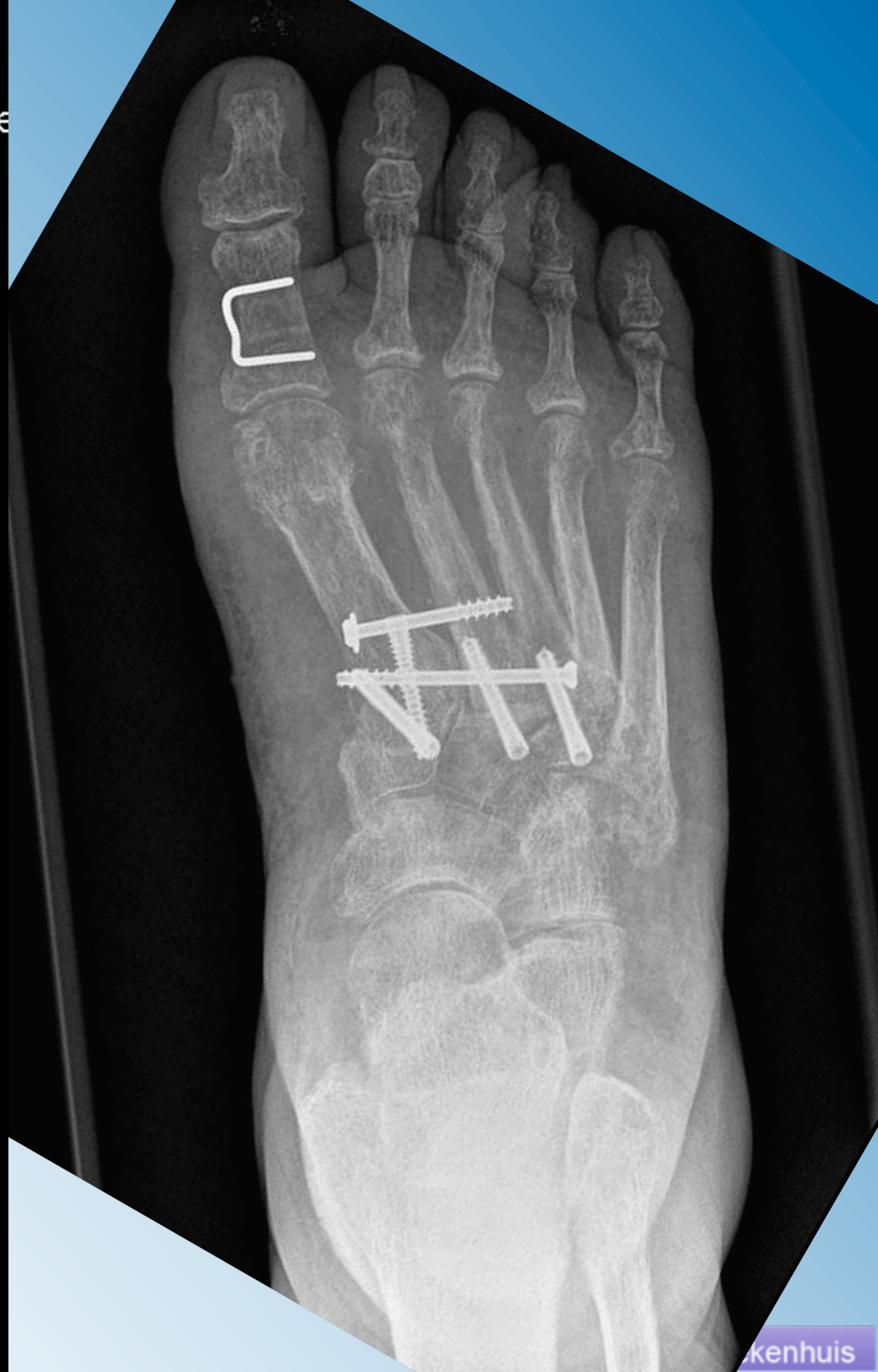
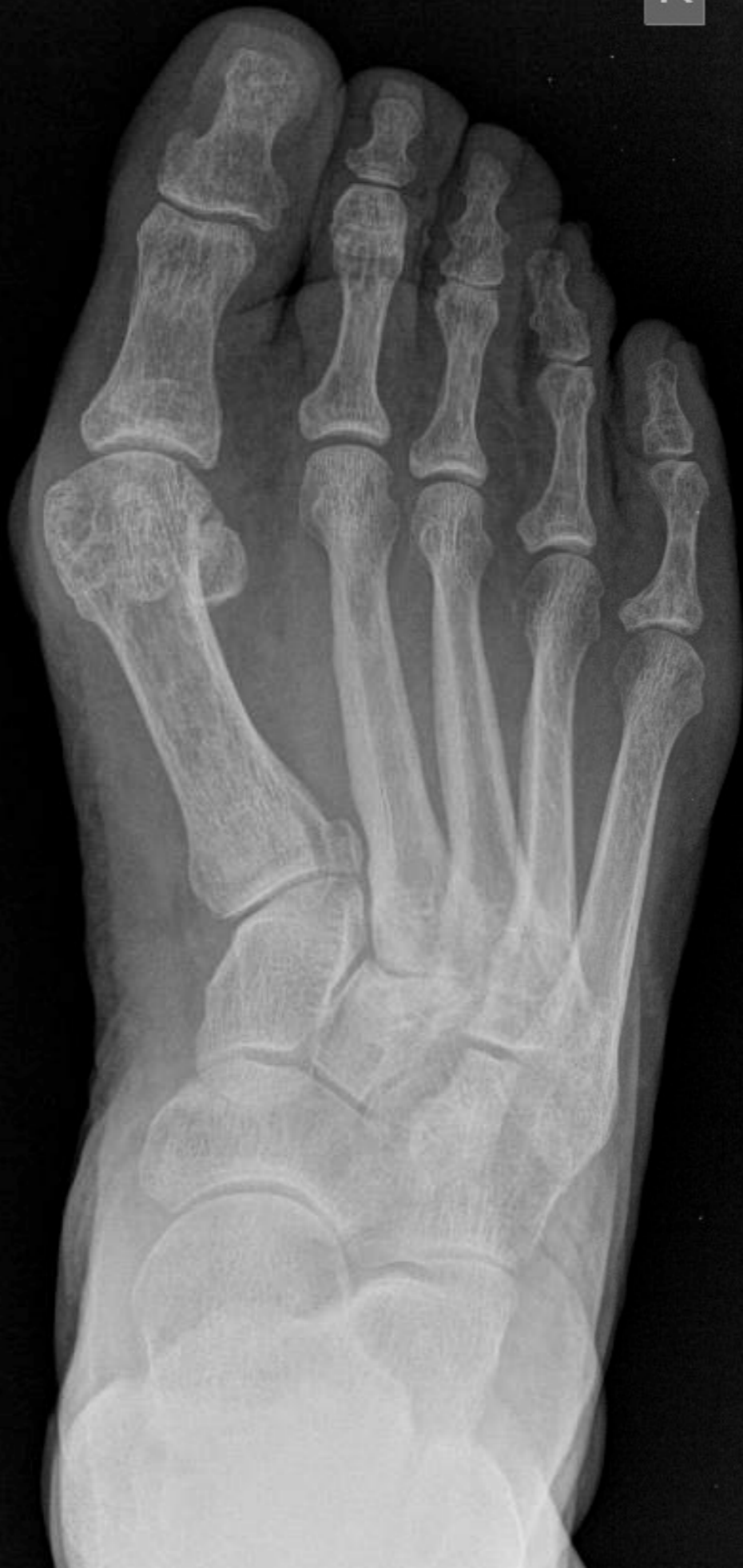
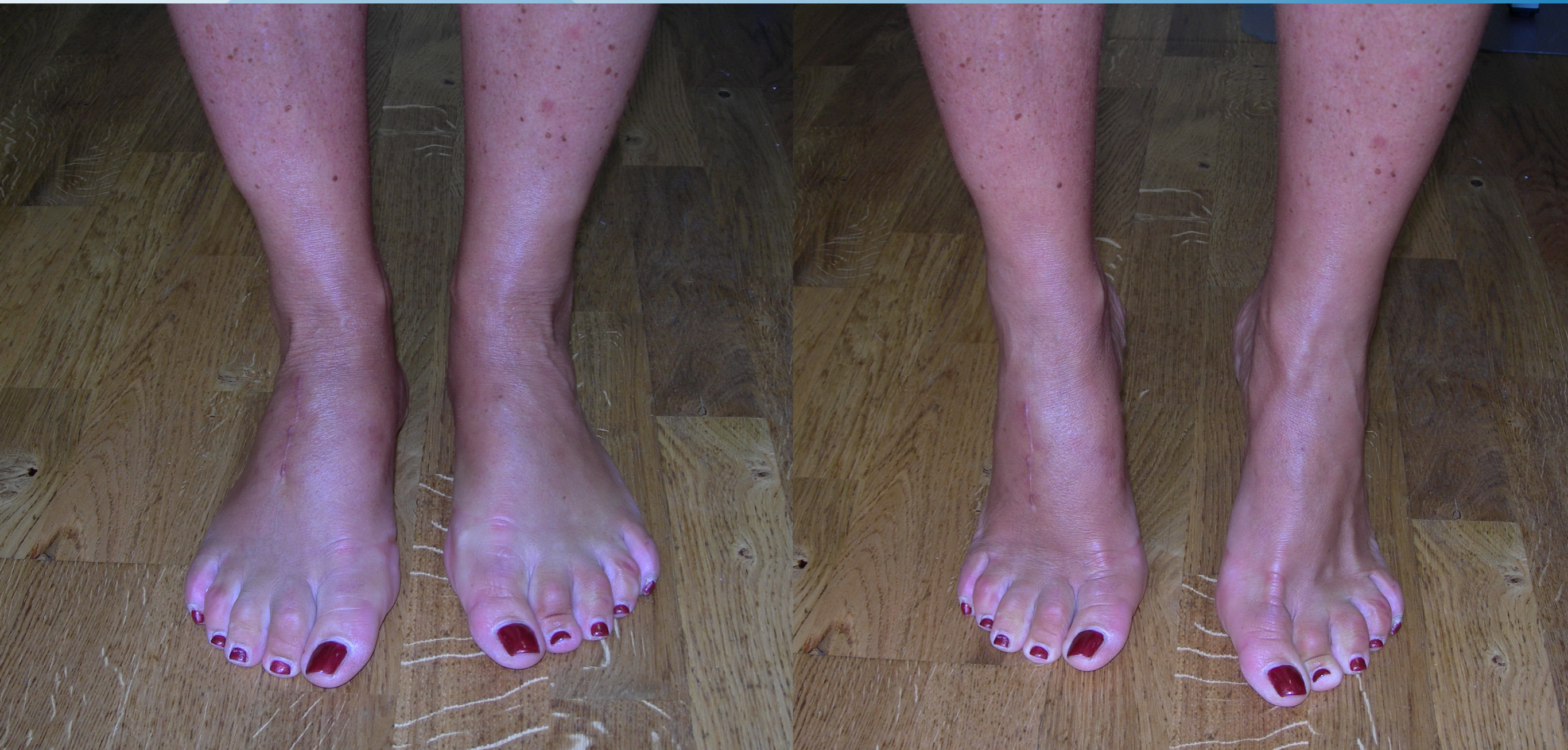R

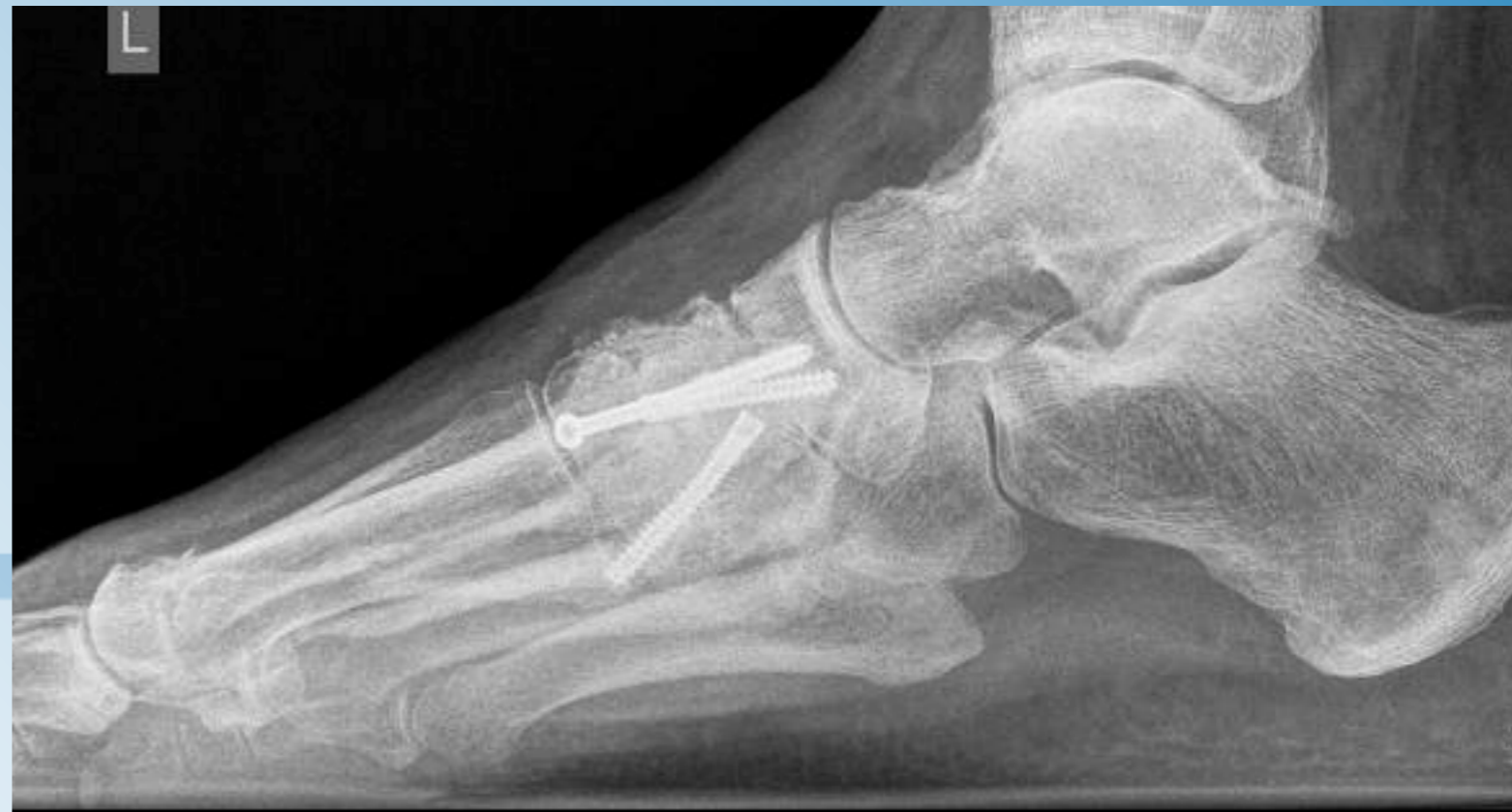
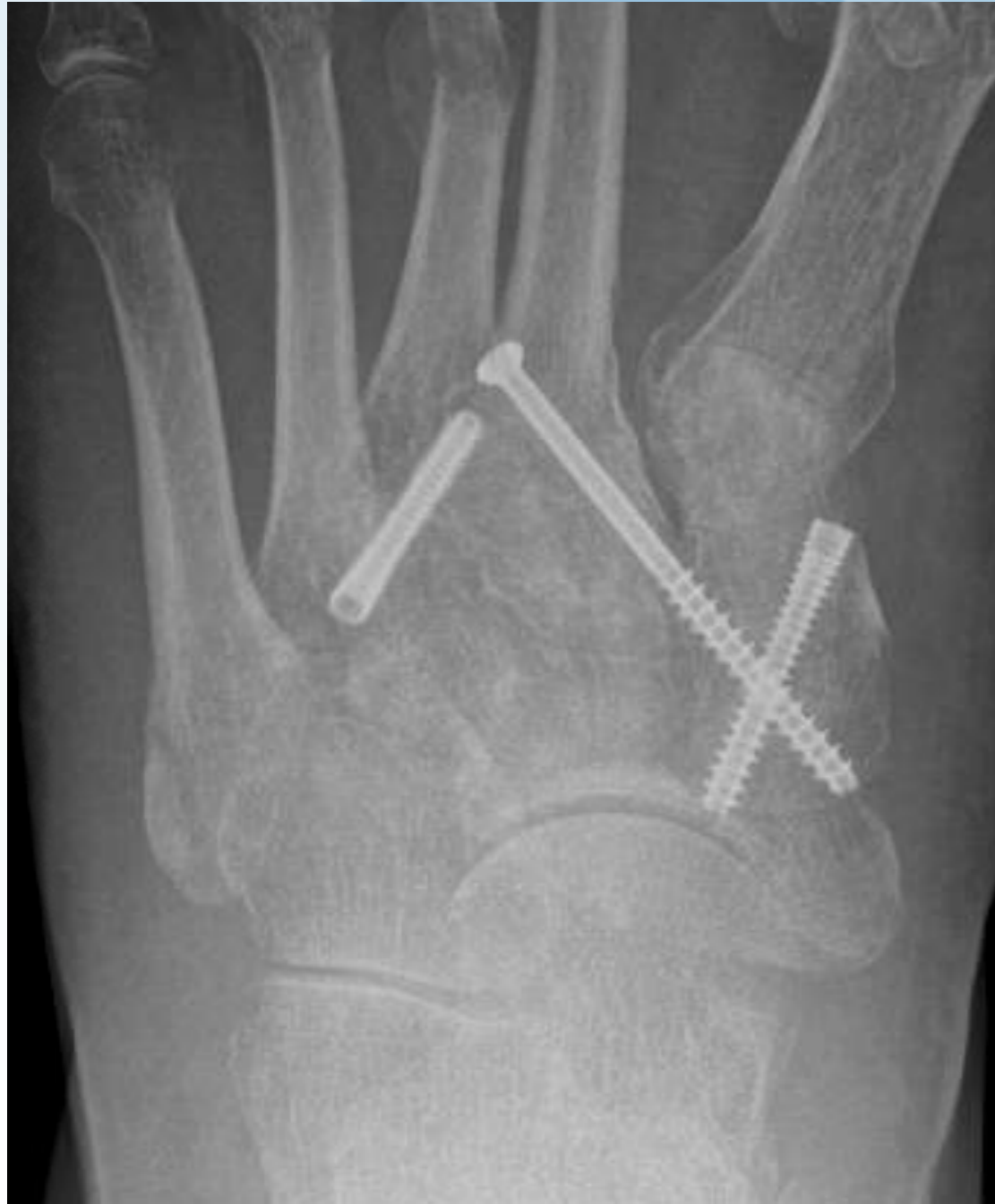
R

Re







Personal series : isolated TMT fusions

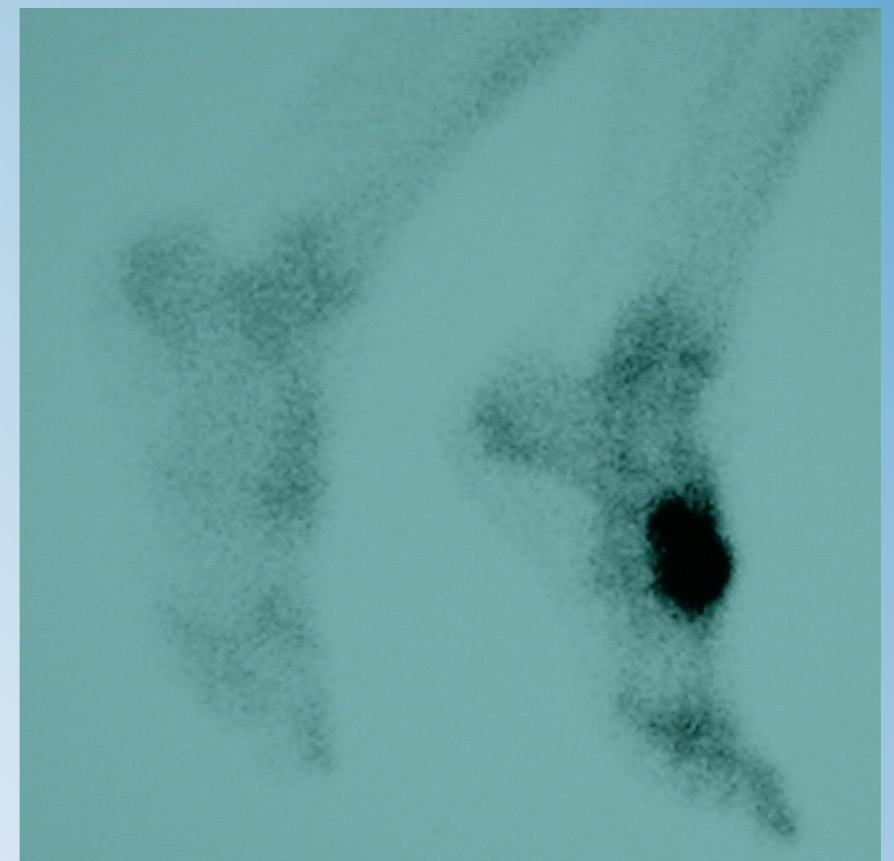
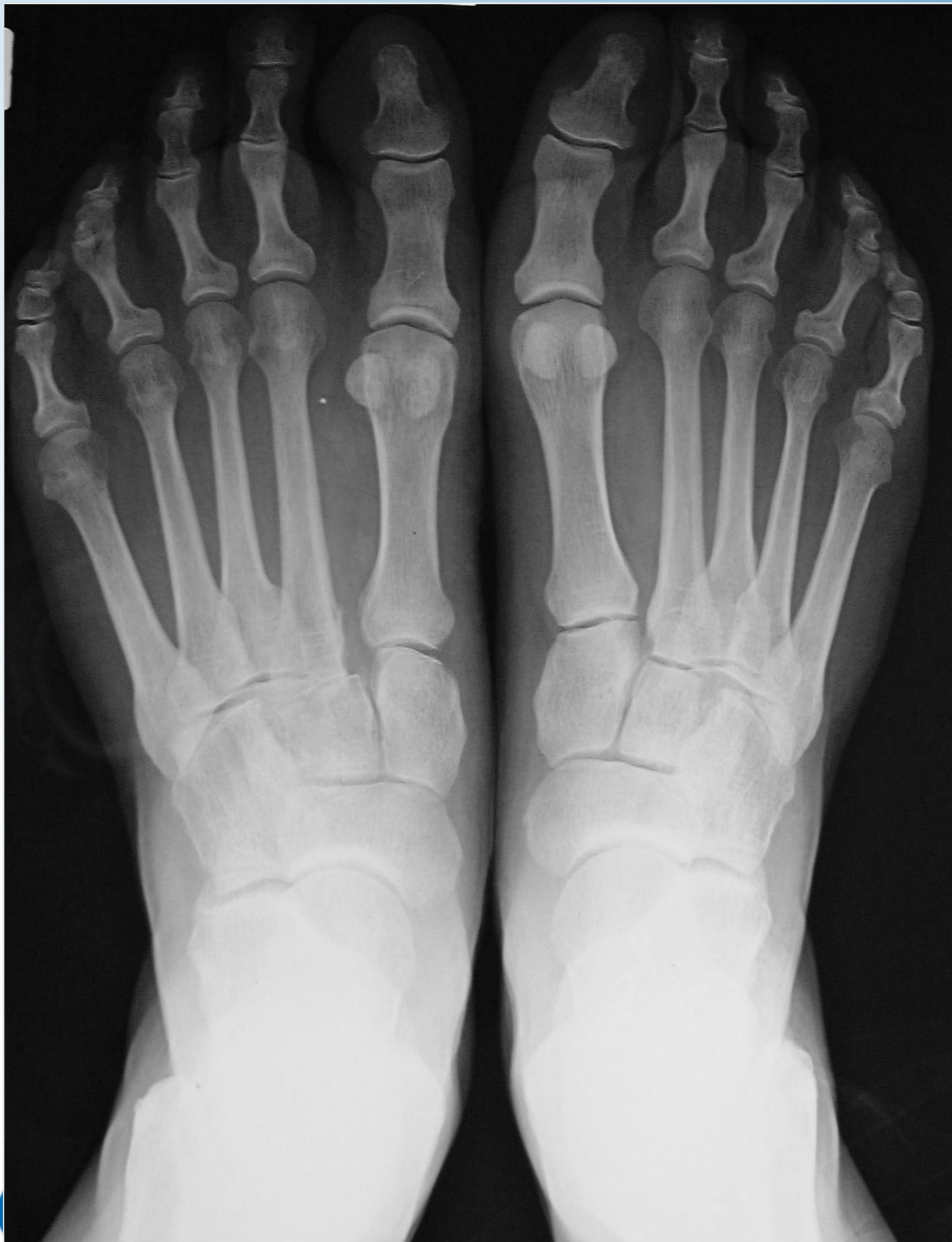- 34 feet
- 20 primary arthrosis, 9 posttraumatic, 3 inflammatory
- 9 TMT123, 4 TMT12, 14 TMT23, 5 TMT2, 1 TMT1, 1 TMT2345
- Autologous bone graft, TMT fixed with screws
- 1 neuroalgodystrophy, 2 nonunions
- 4 hardware removal

Take home message

- Denk aan middenvoetartrose
- Localiseer de arthrotische gewrichten.
- Geïsoleerde fusie geeft consistente, goede resultaten.





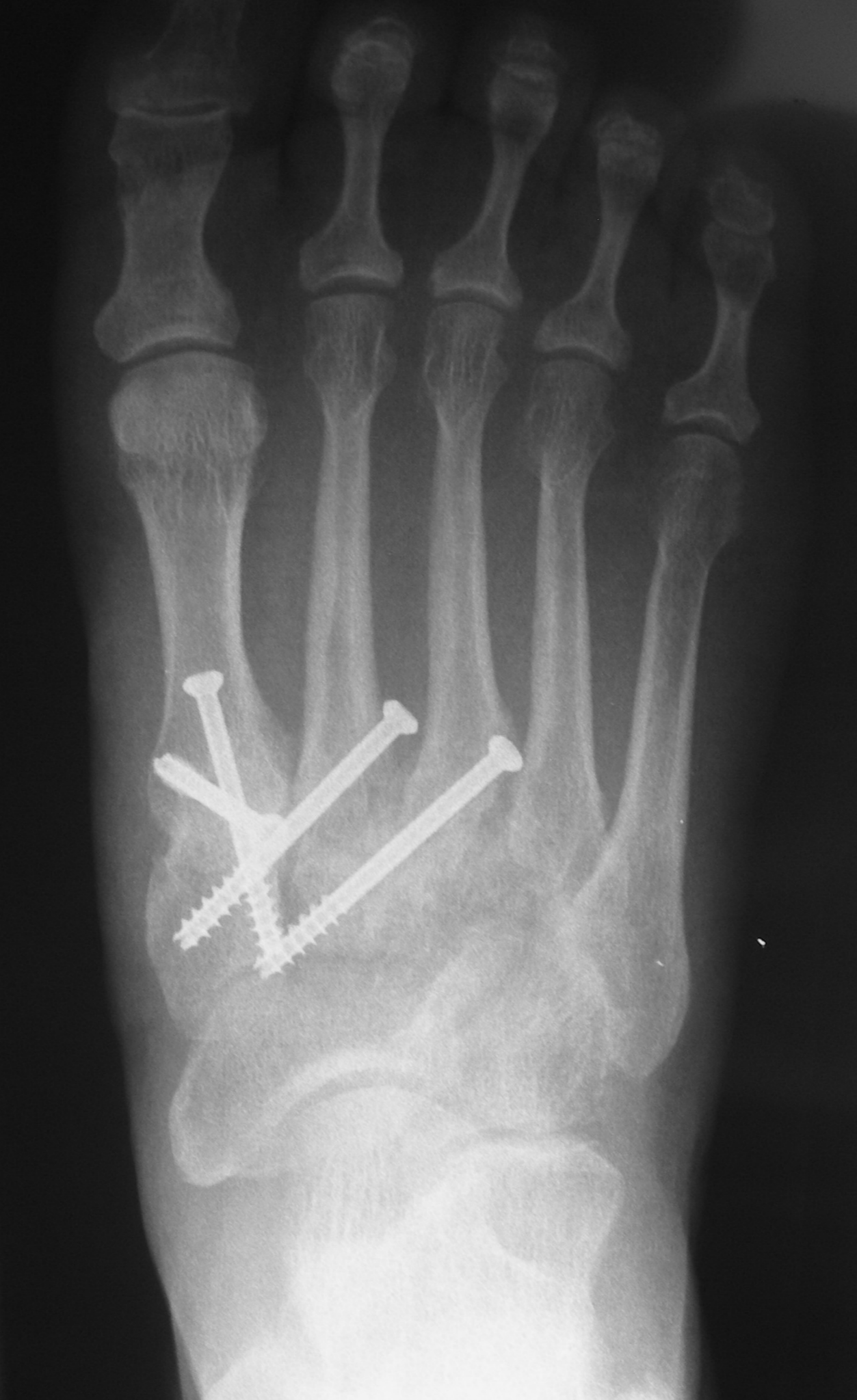


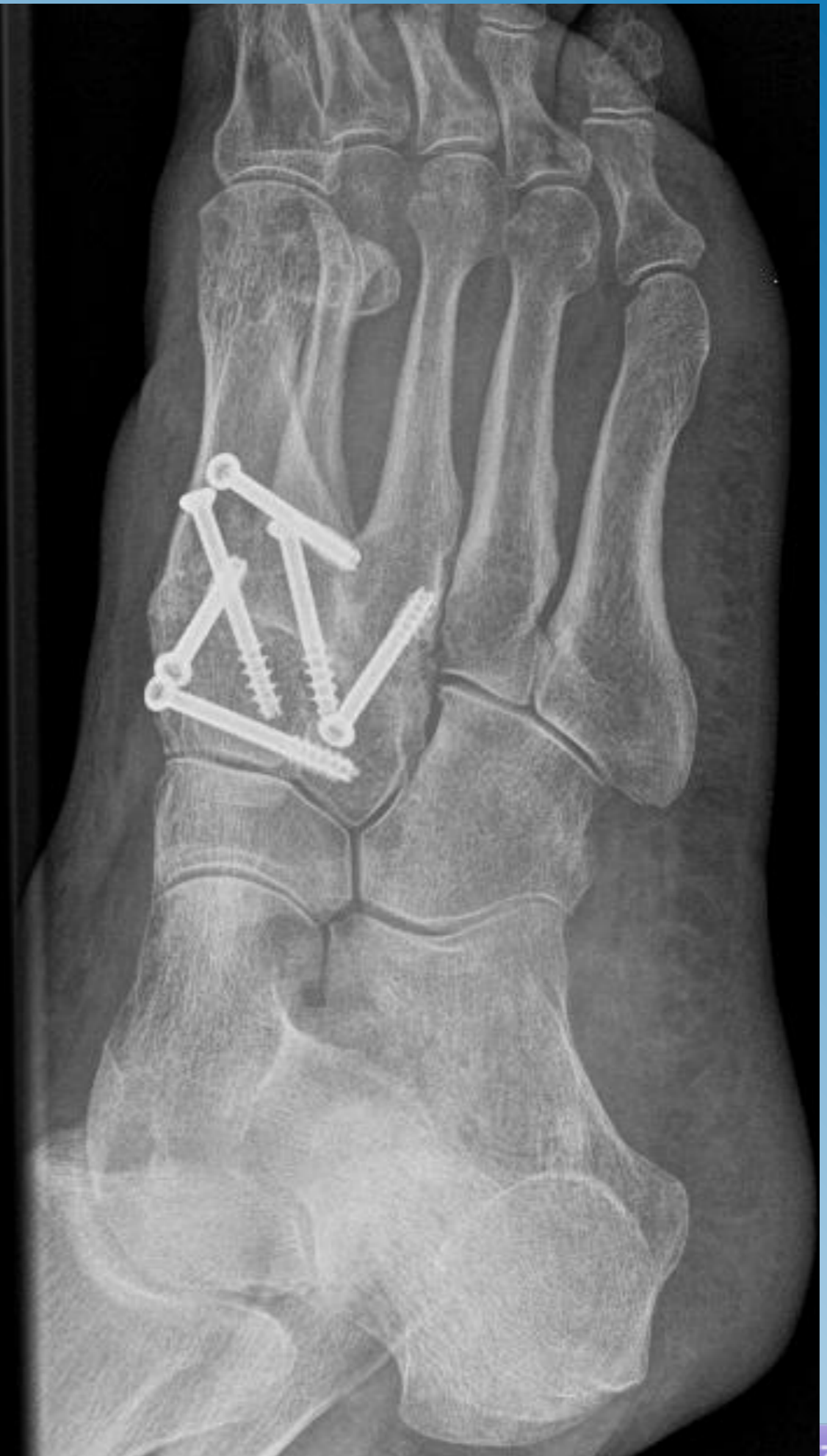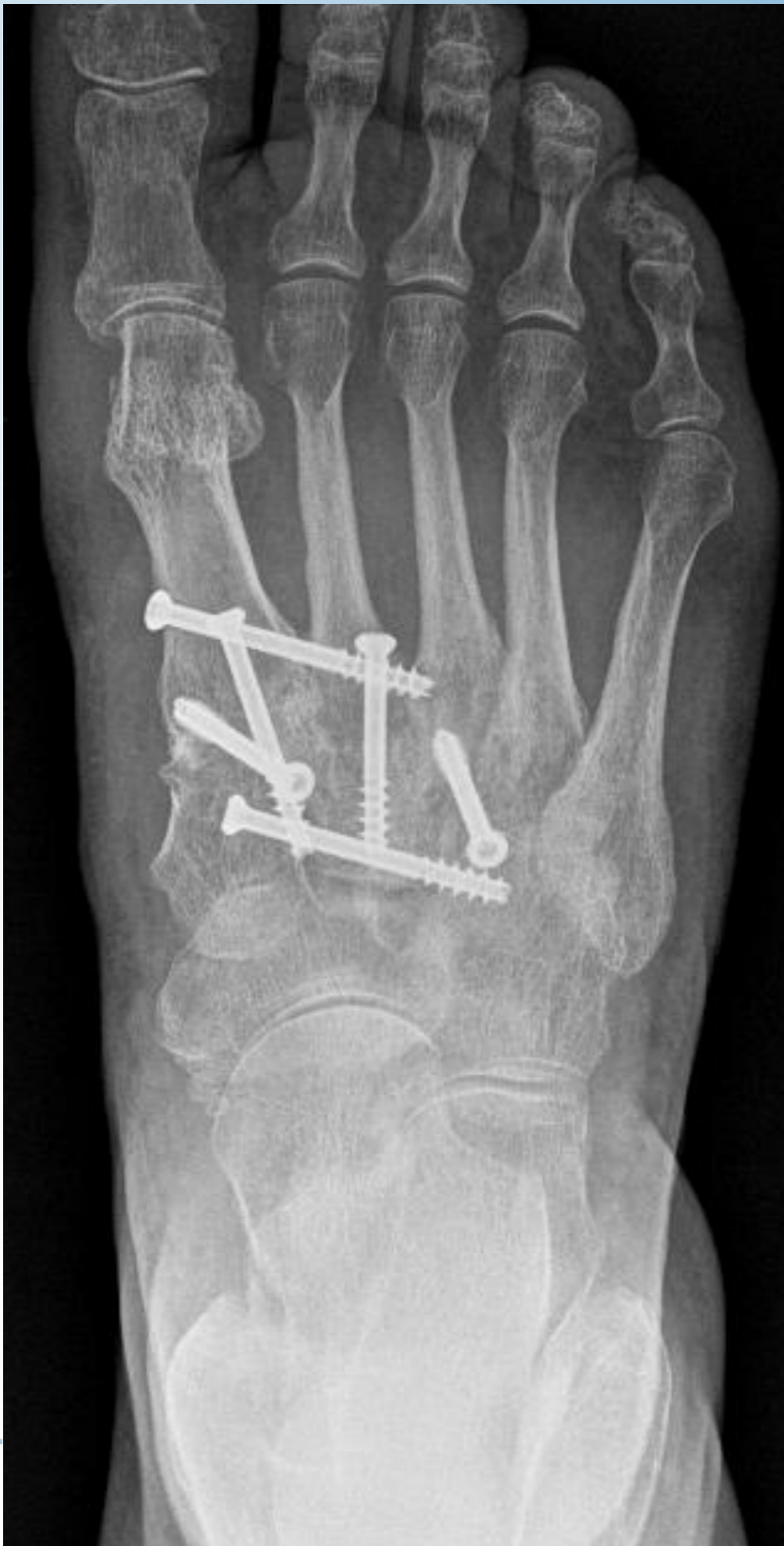Re

Voetzool

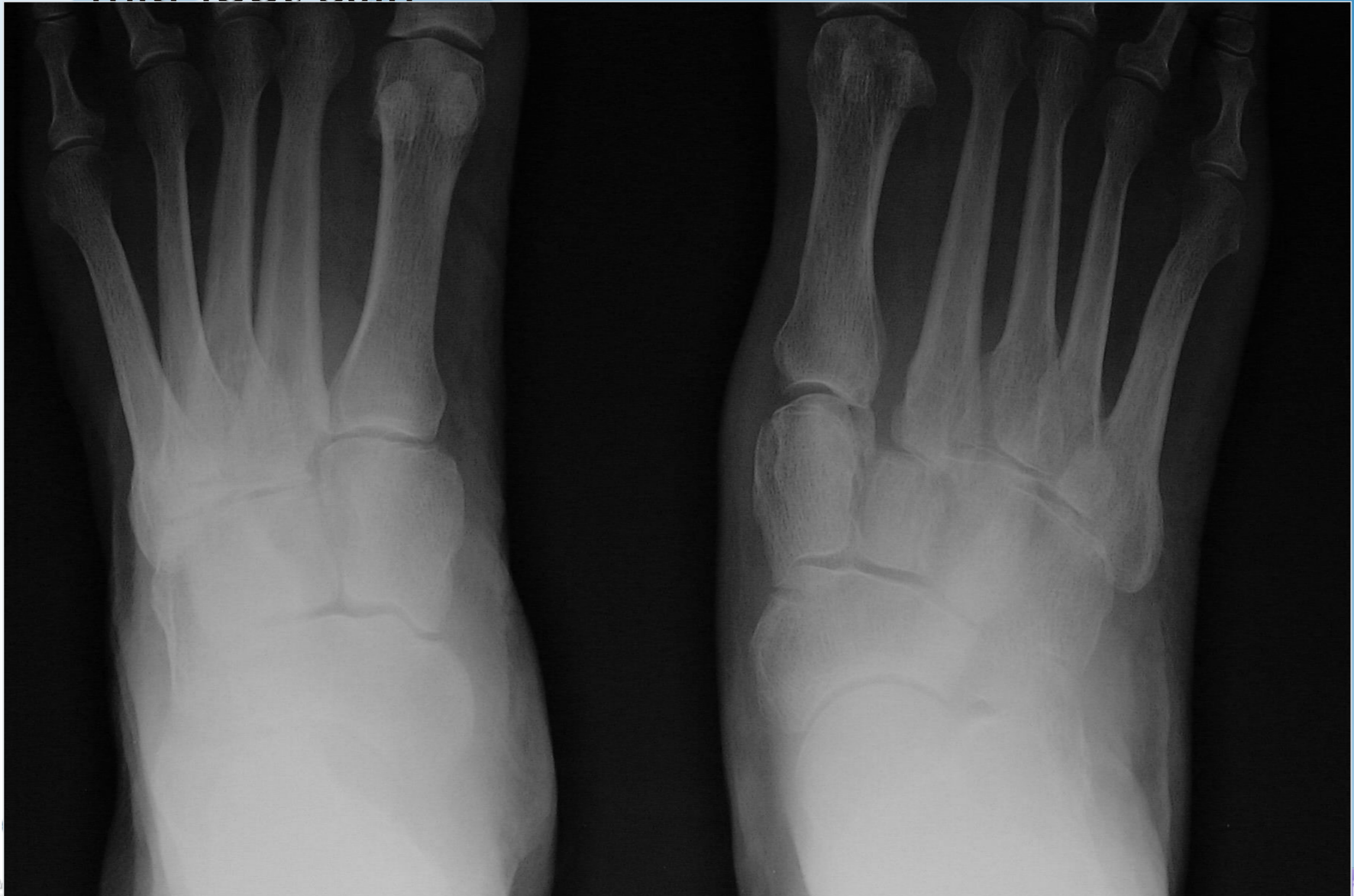Re

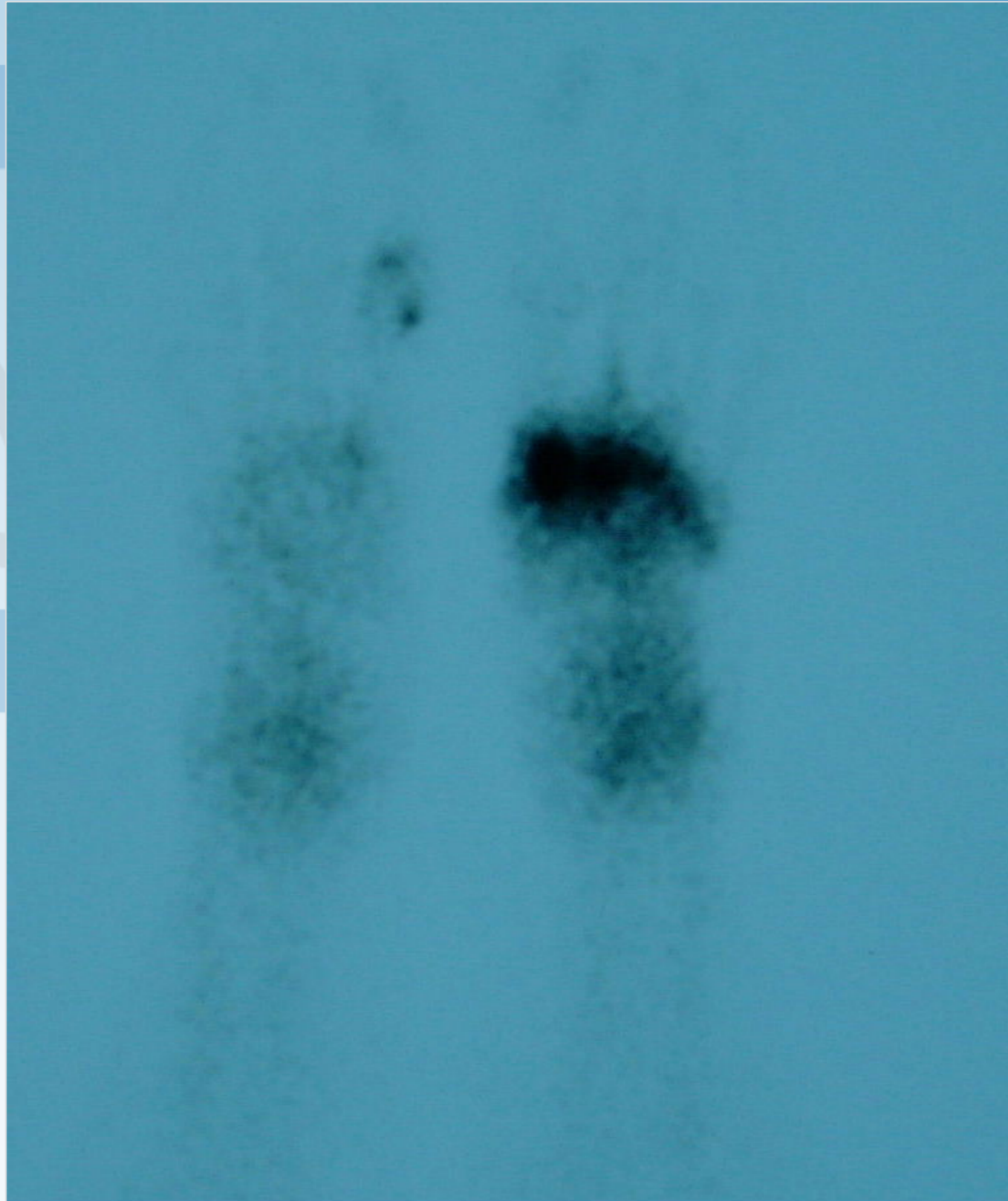
Uitwendige rotatie

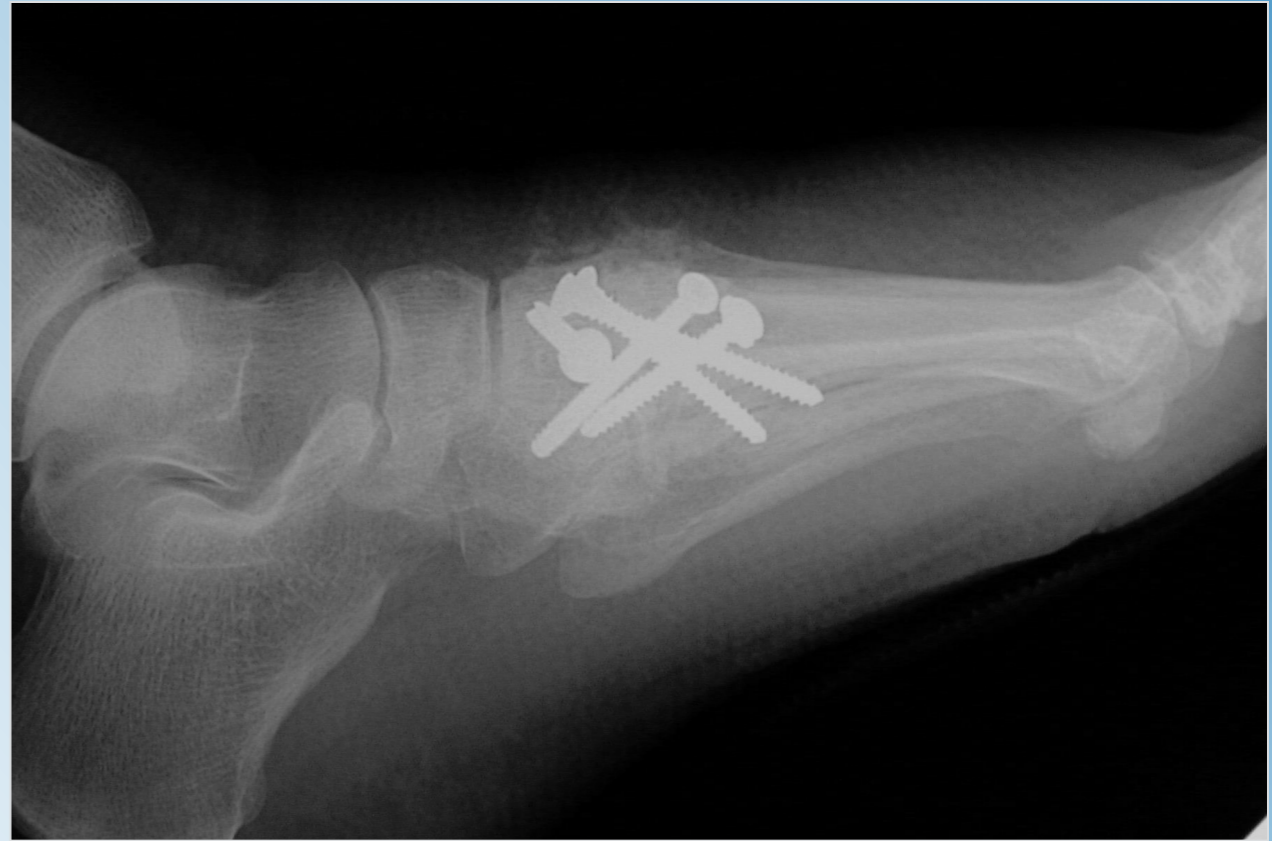
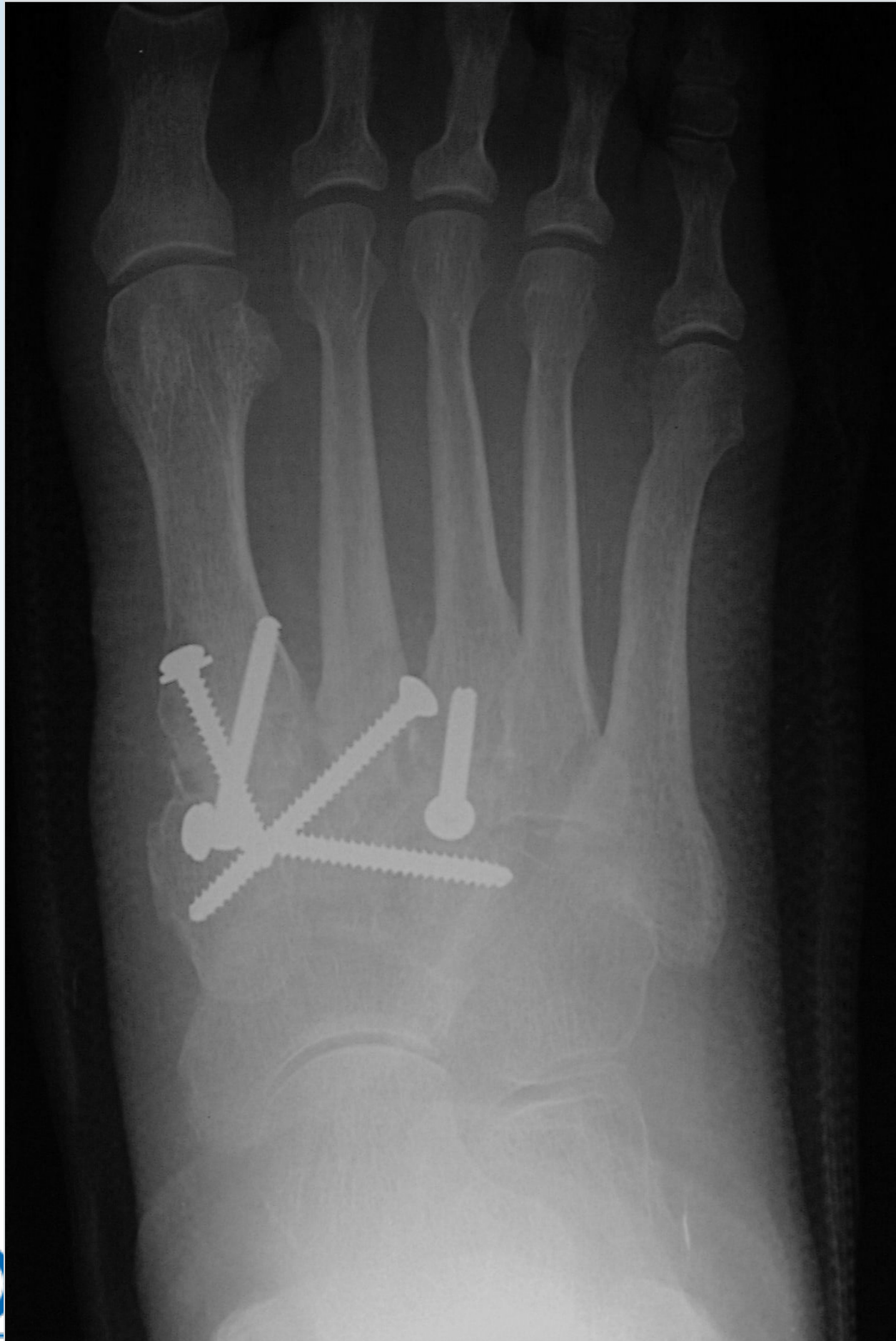


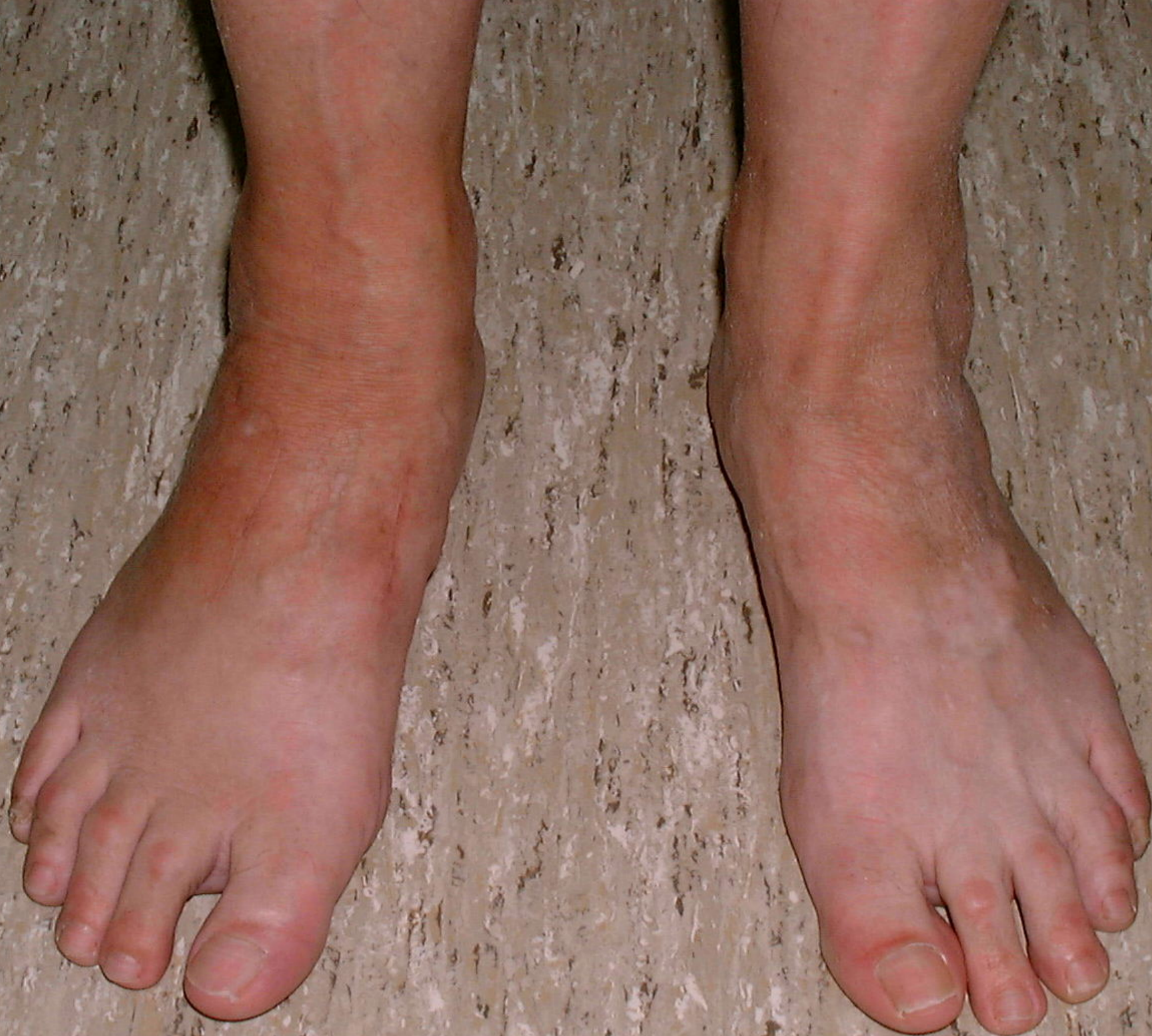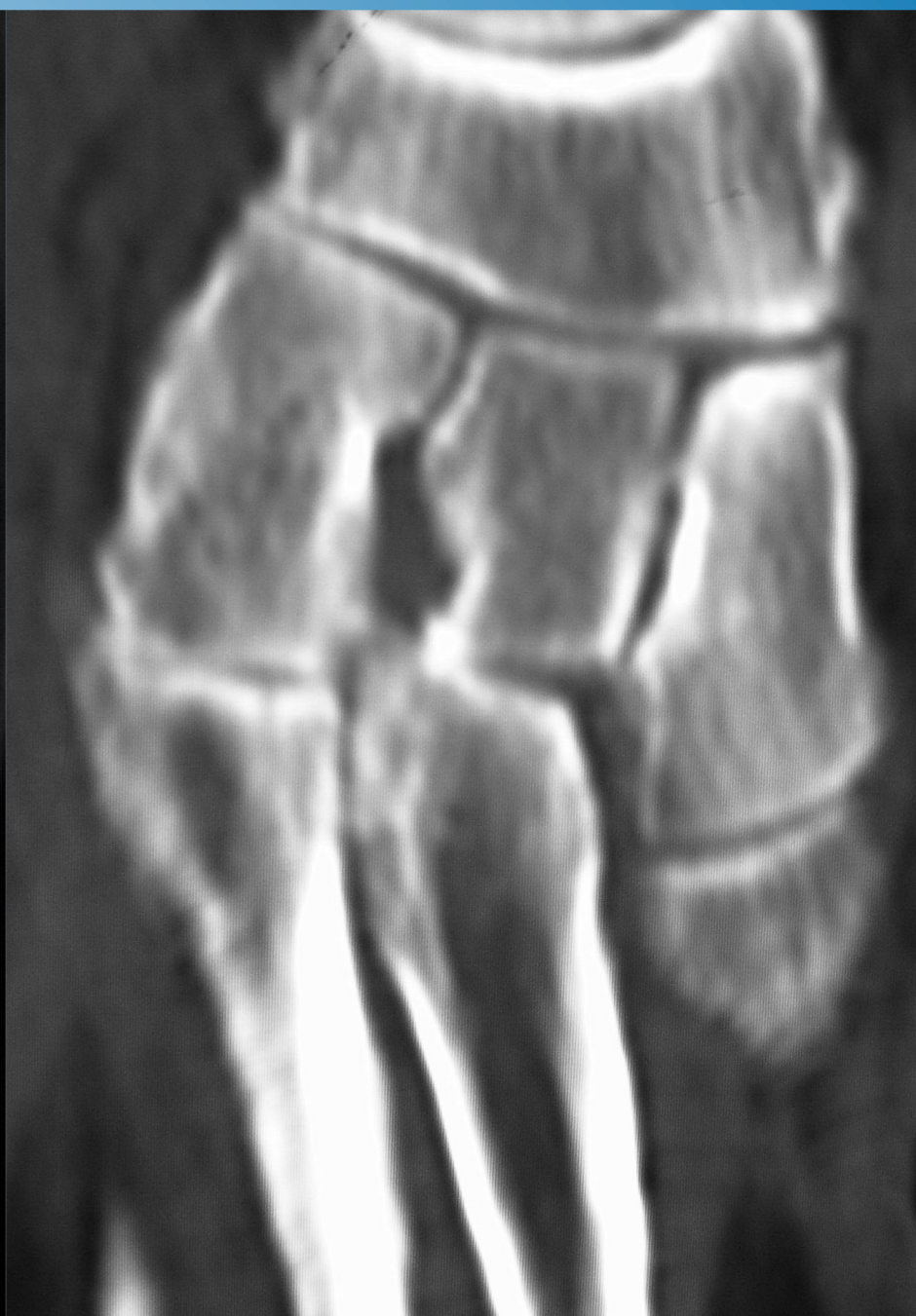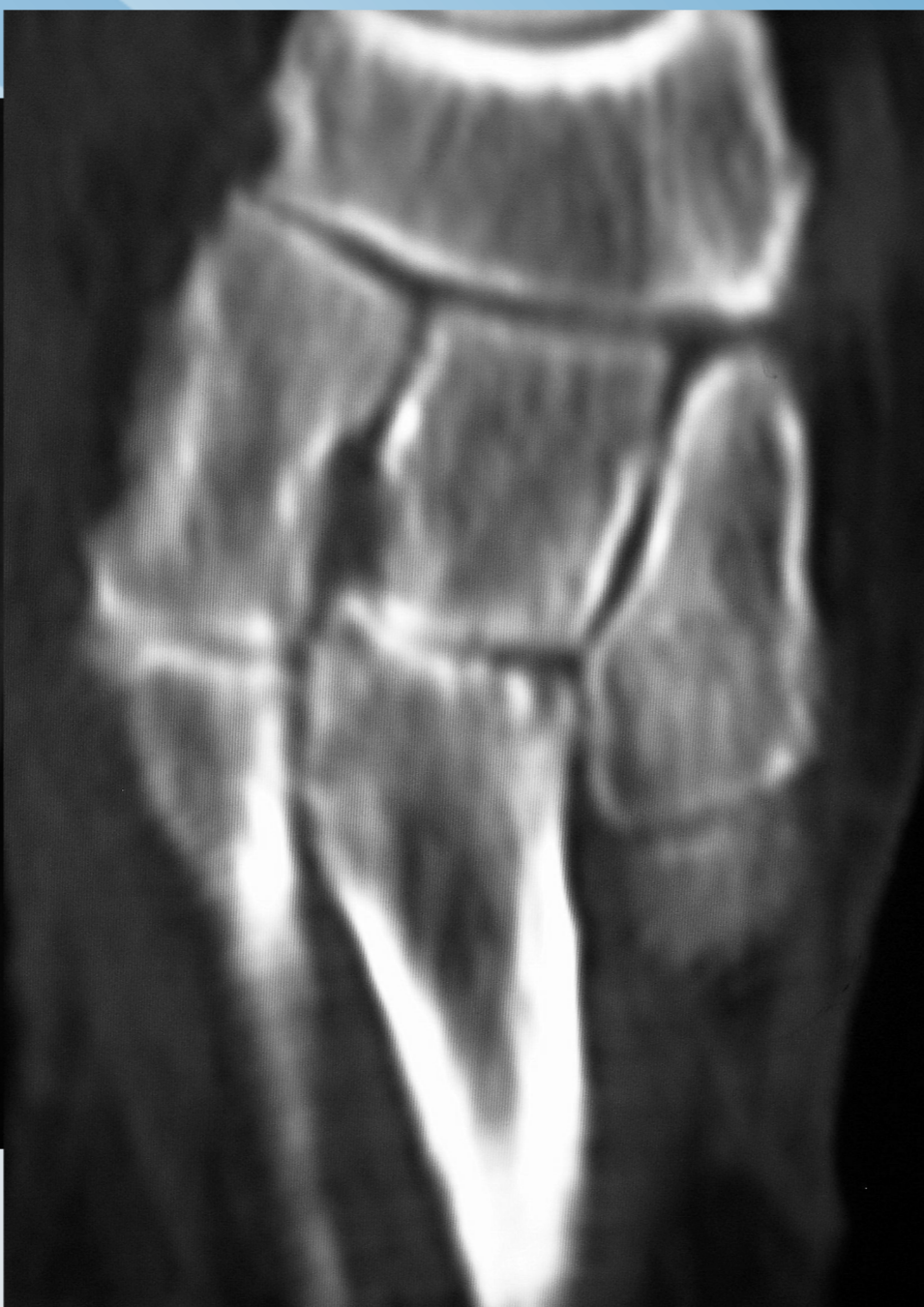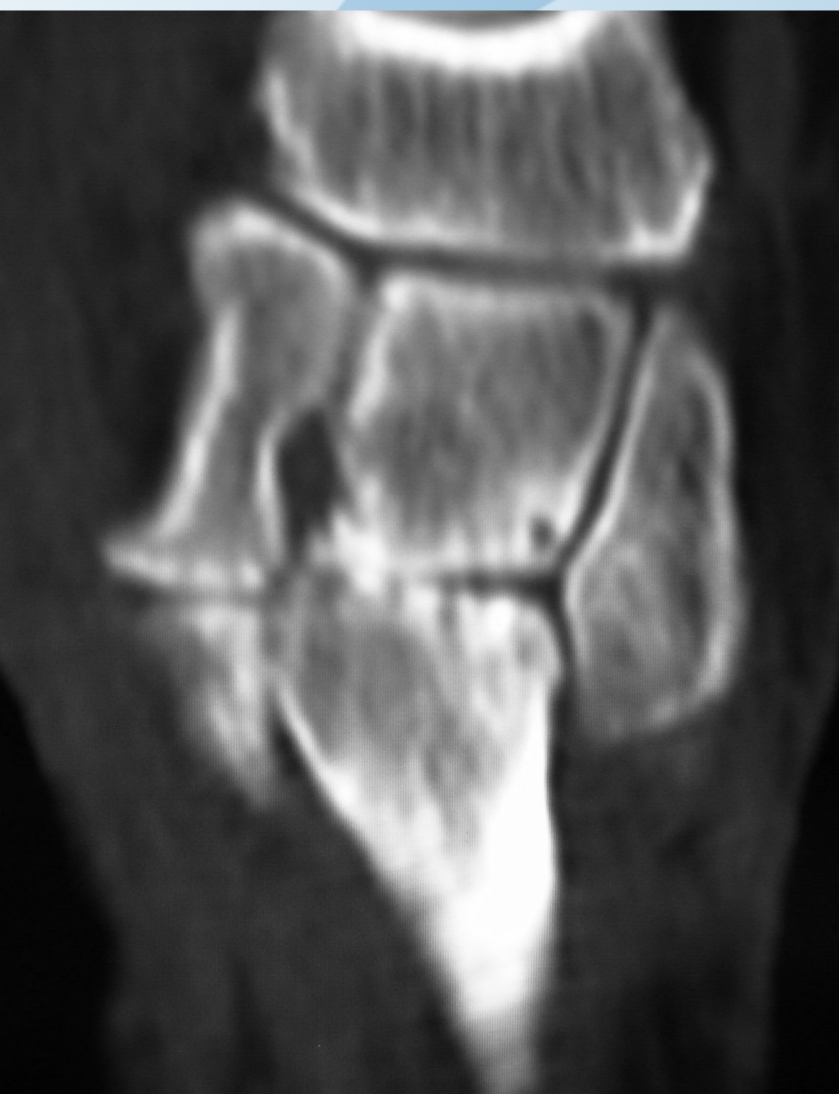- F 60y, foot inversion trauma 10 months ago
- mid-foot pain ++

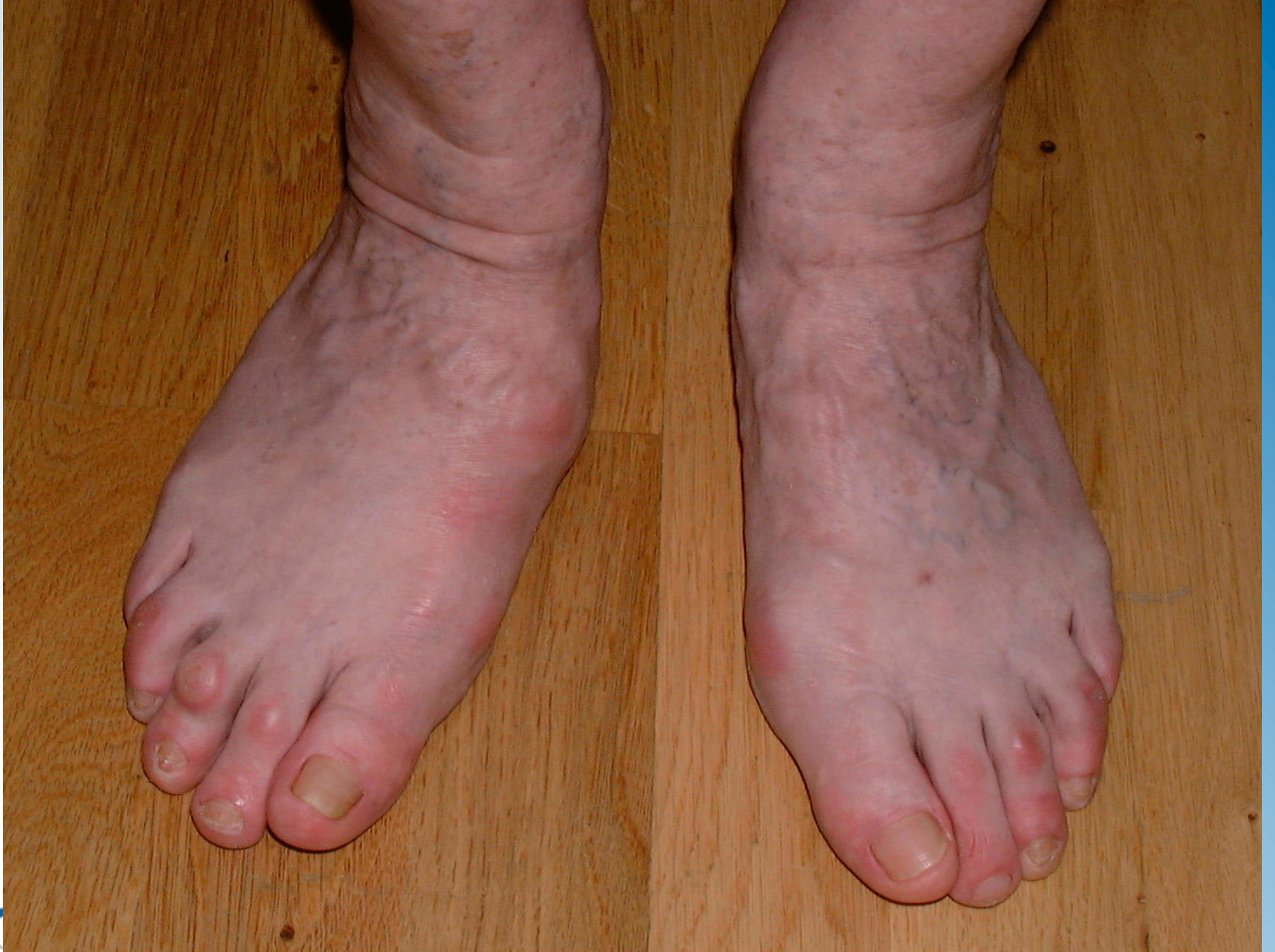


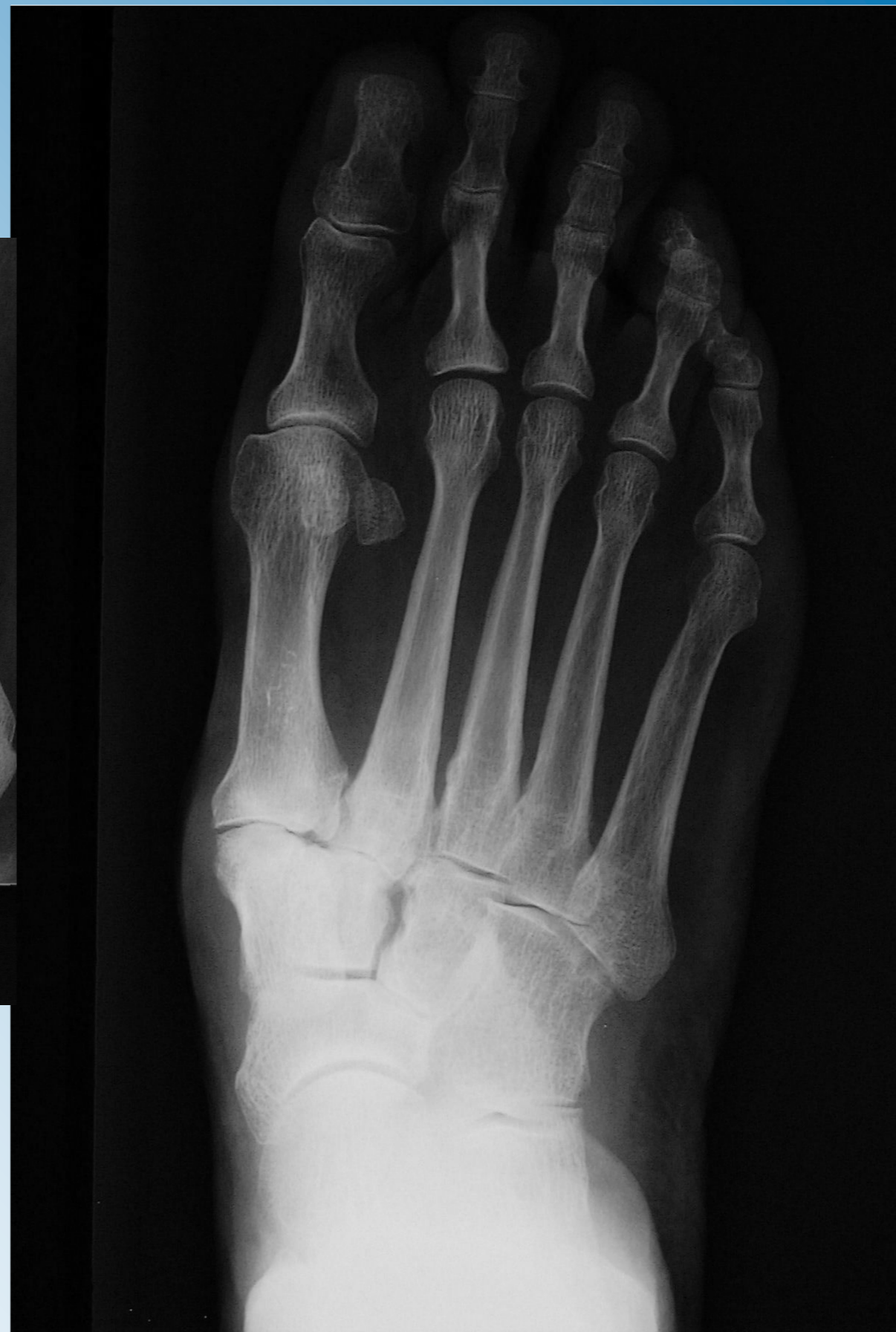
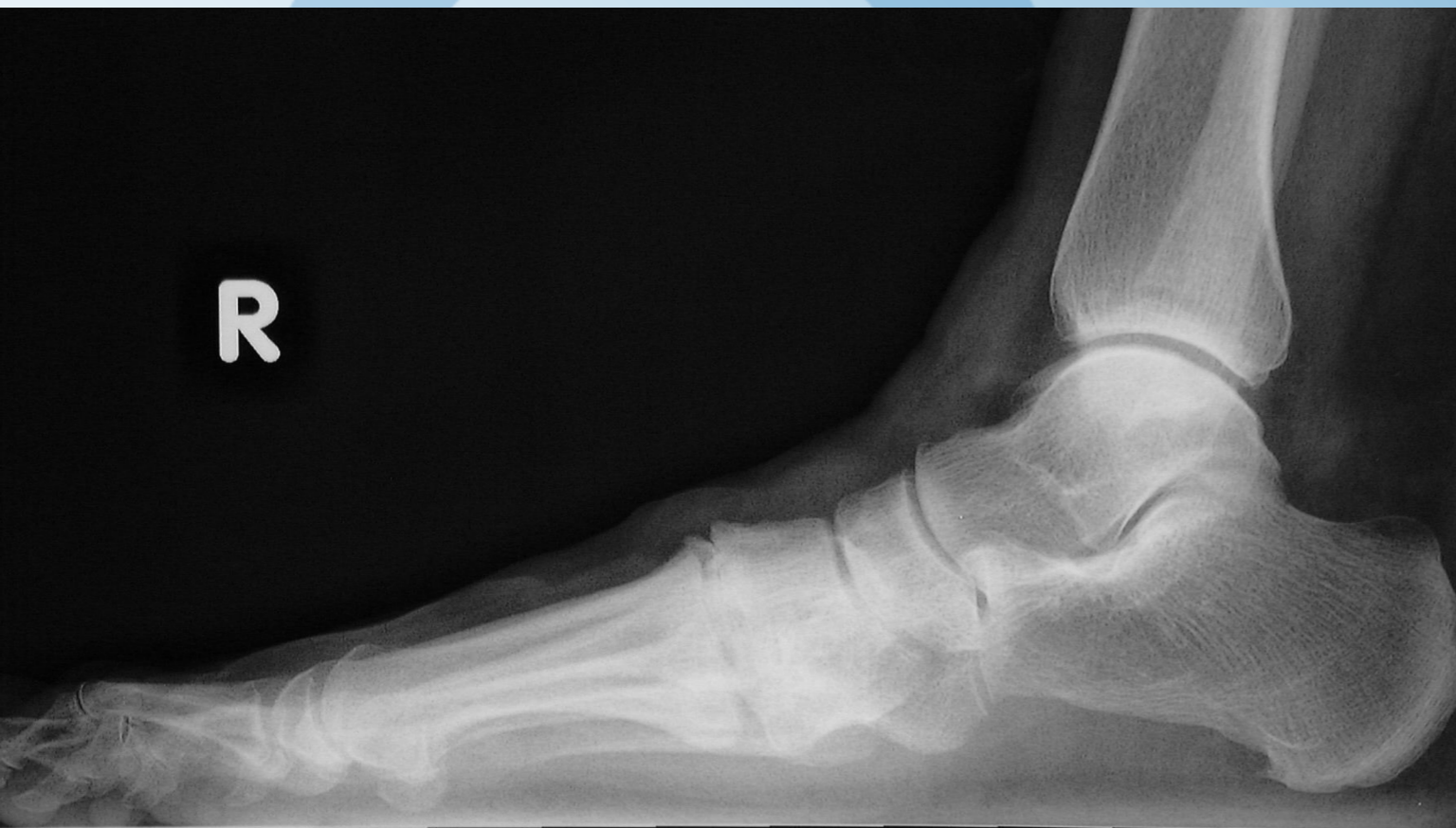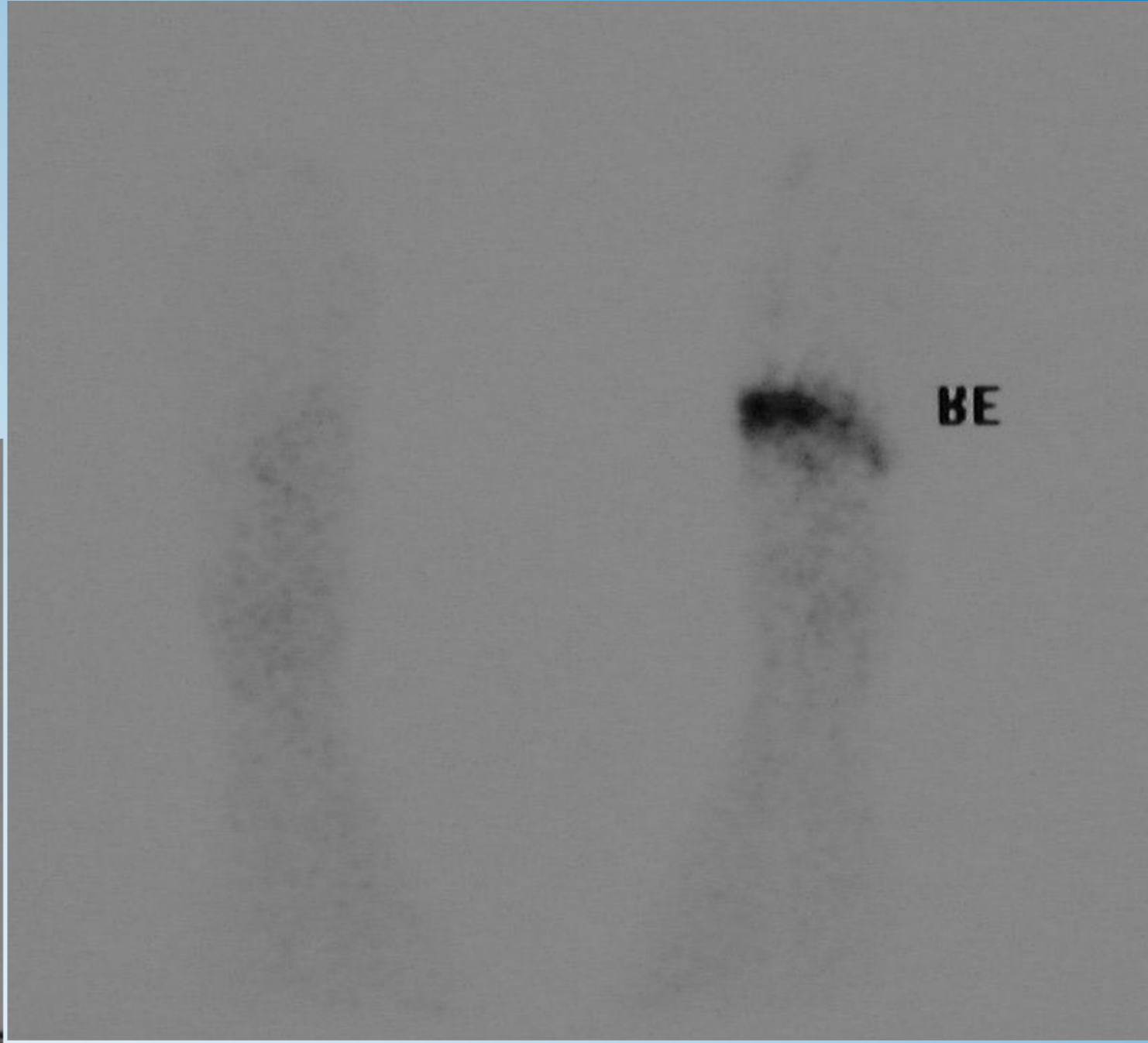
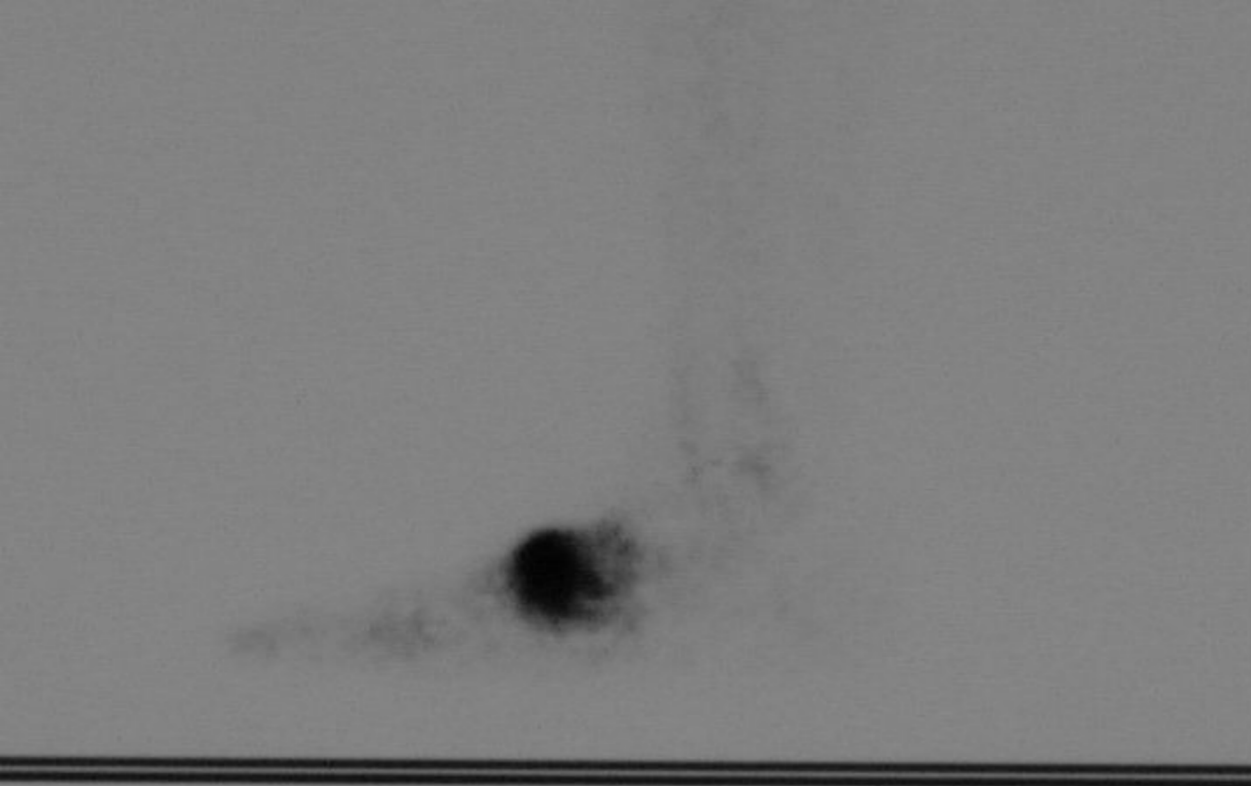




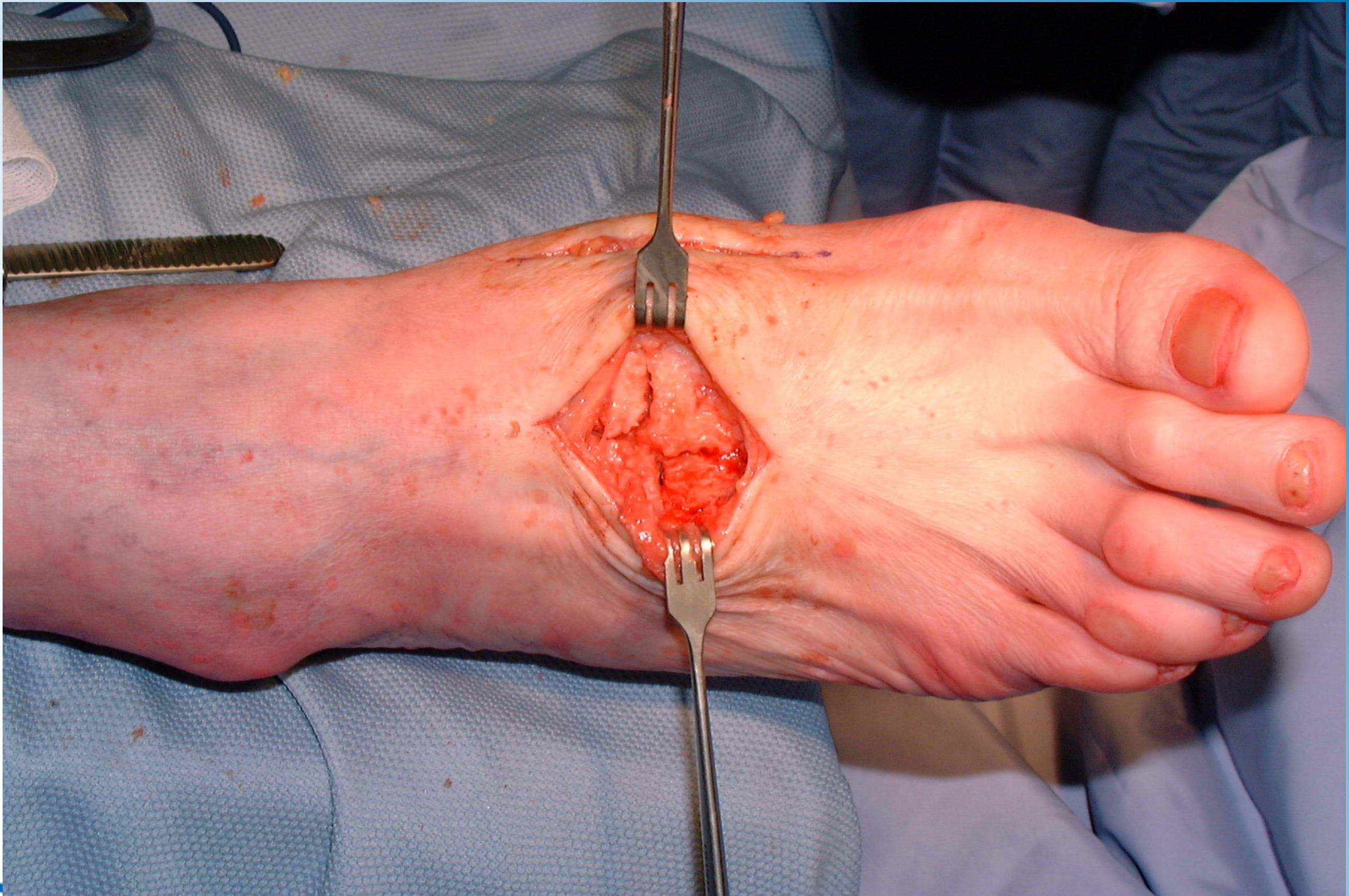





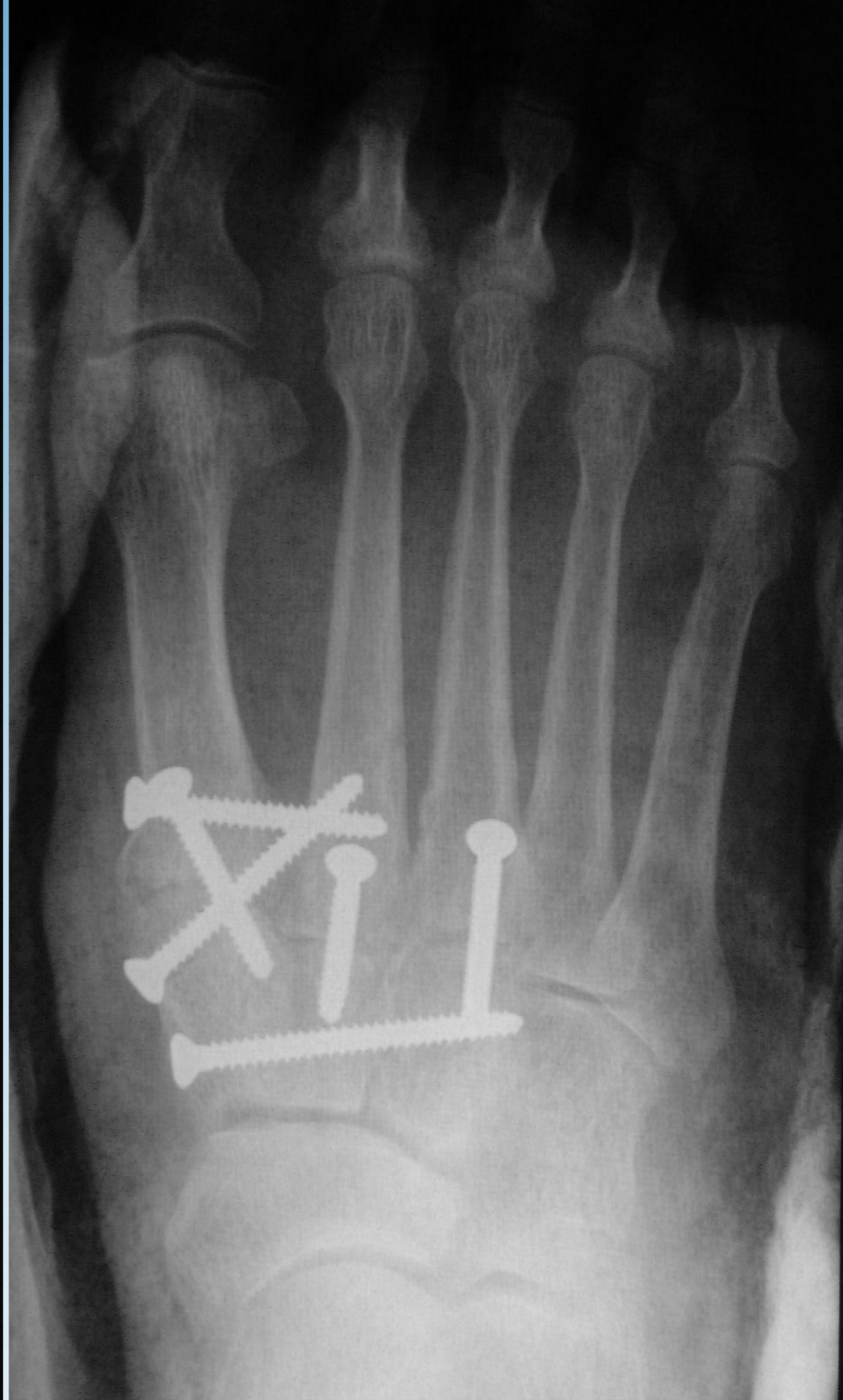
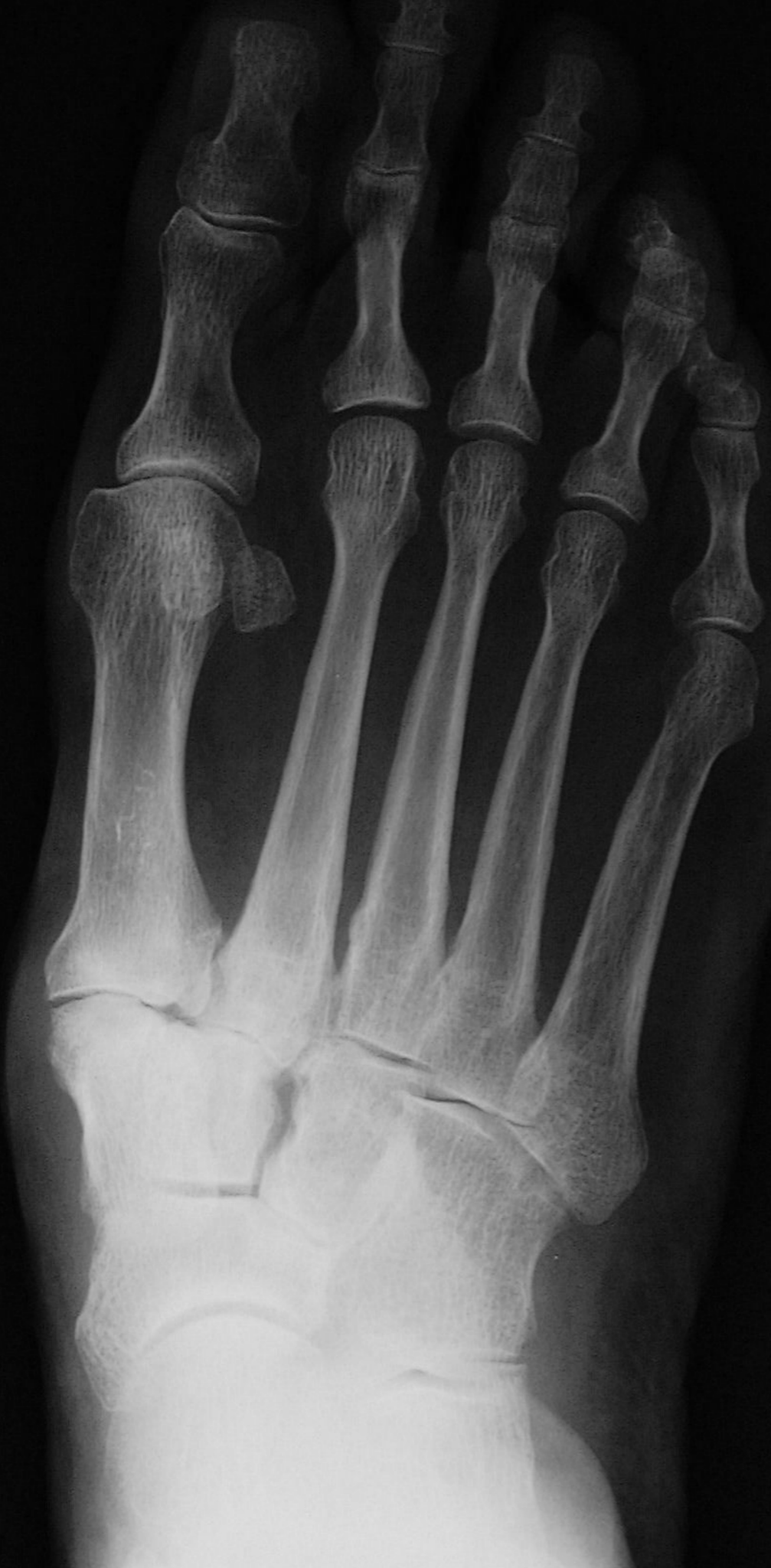

BE

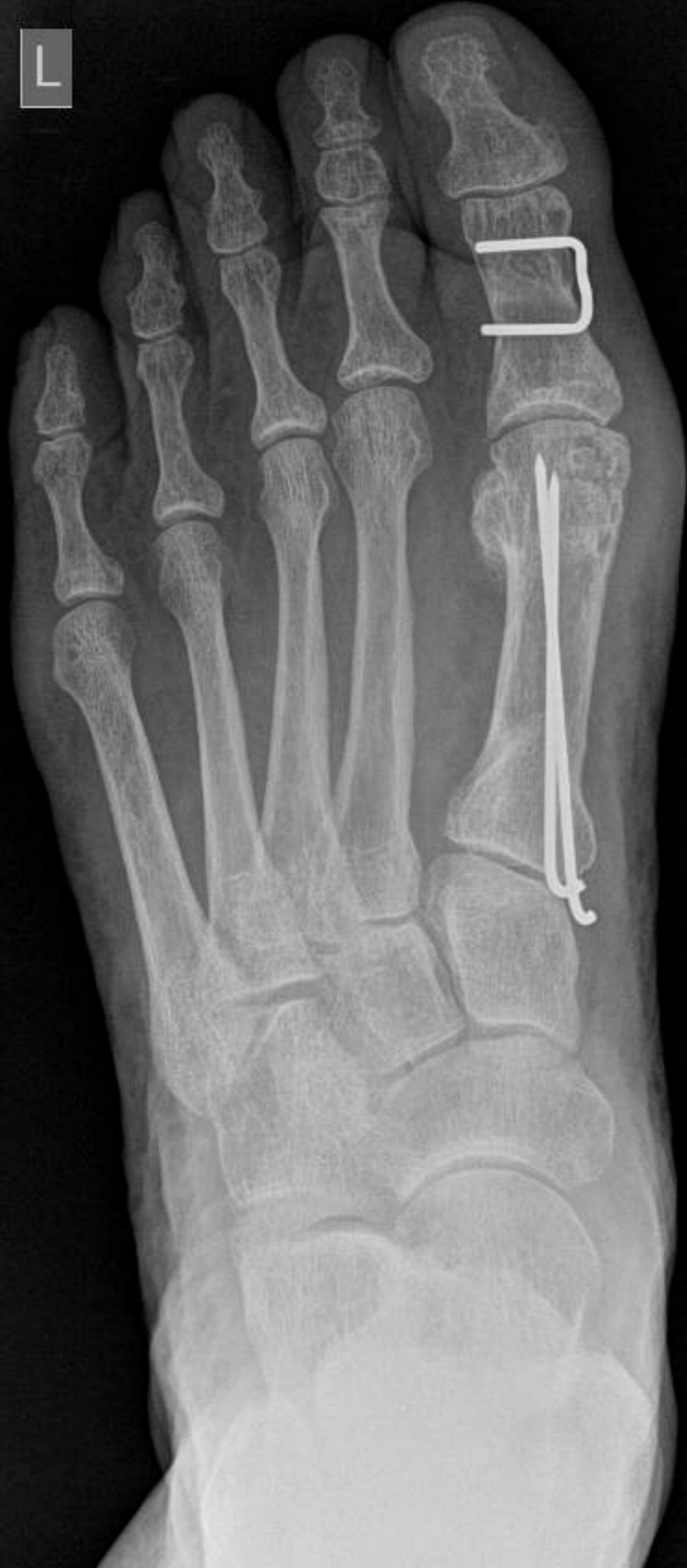




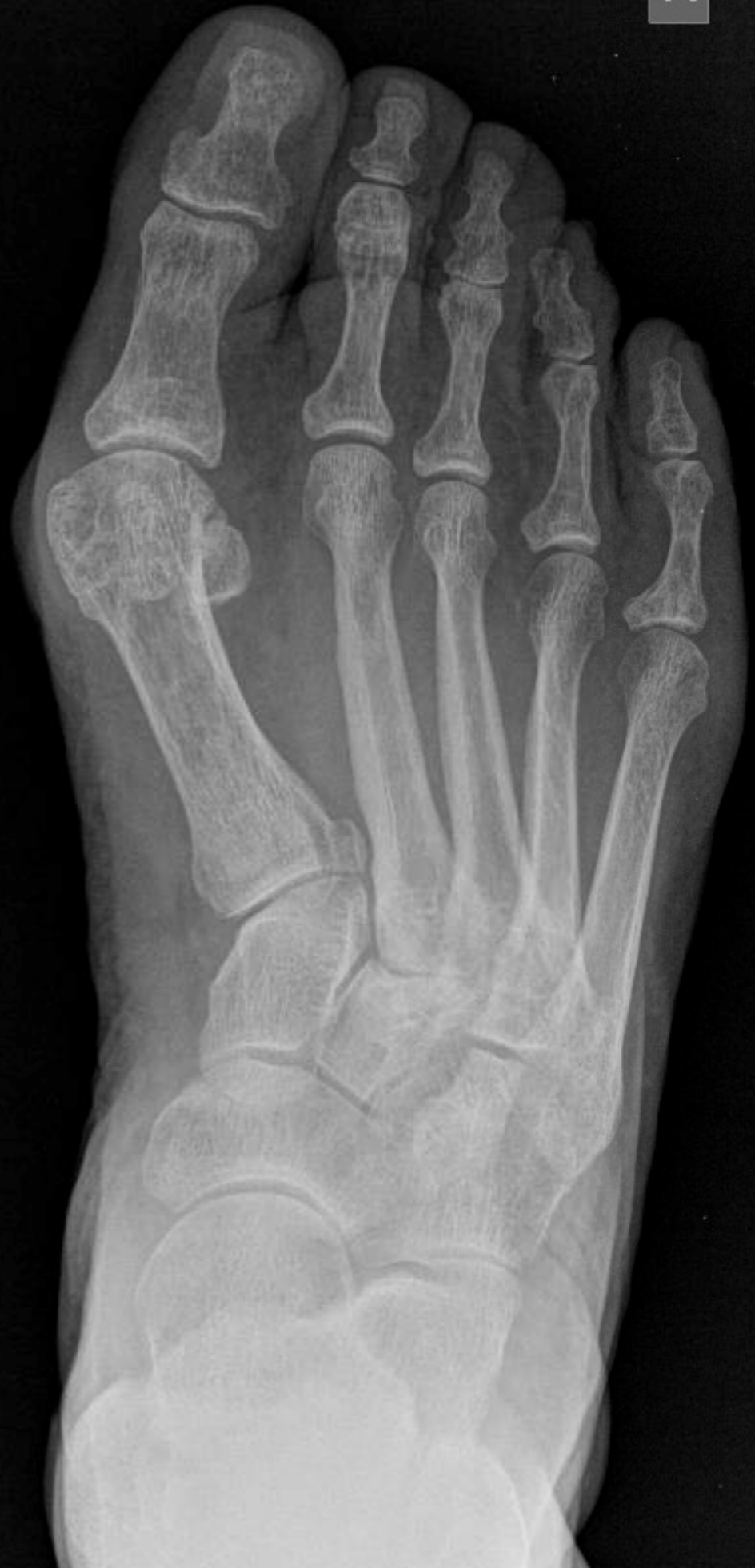


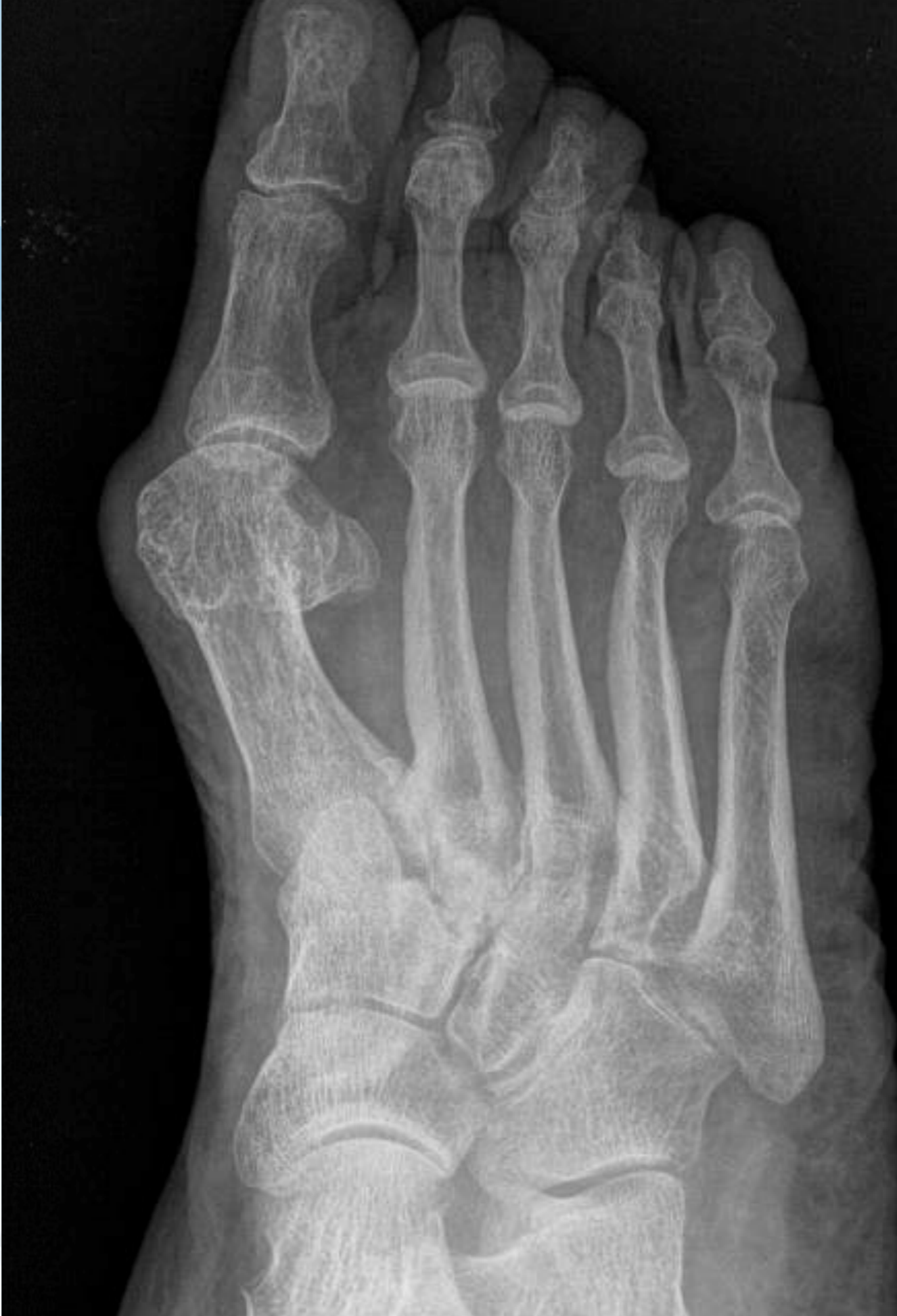L



R



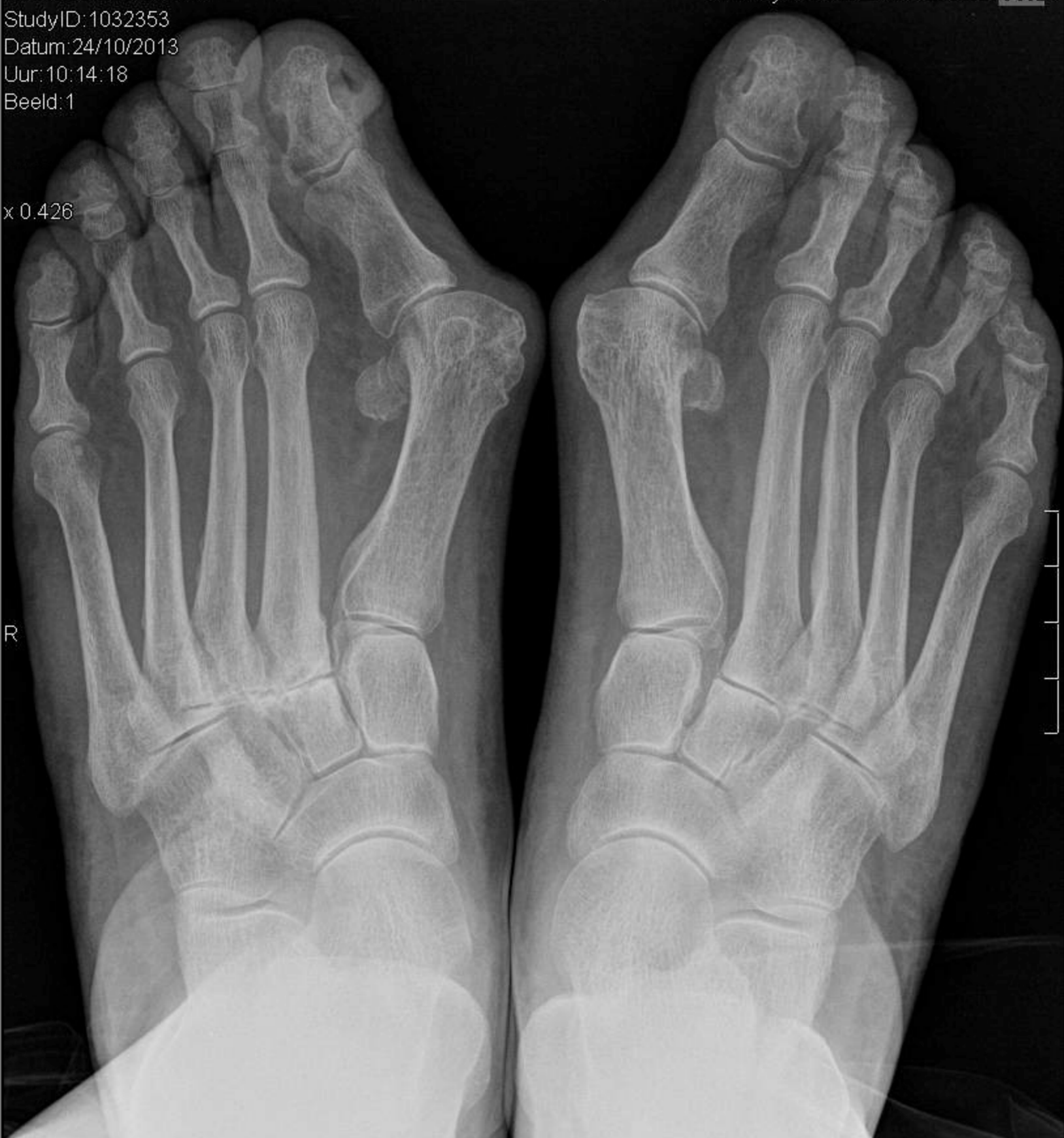Re



StudyID: 1032353
Datum: 24/10/2013
Uur: 10:14:18
Beeld: 1

x 0.426

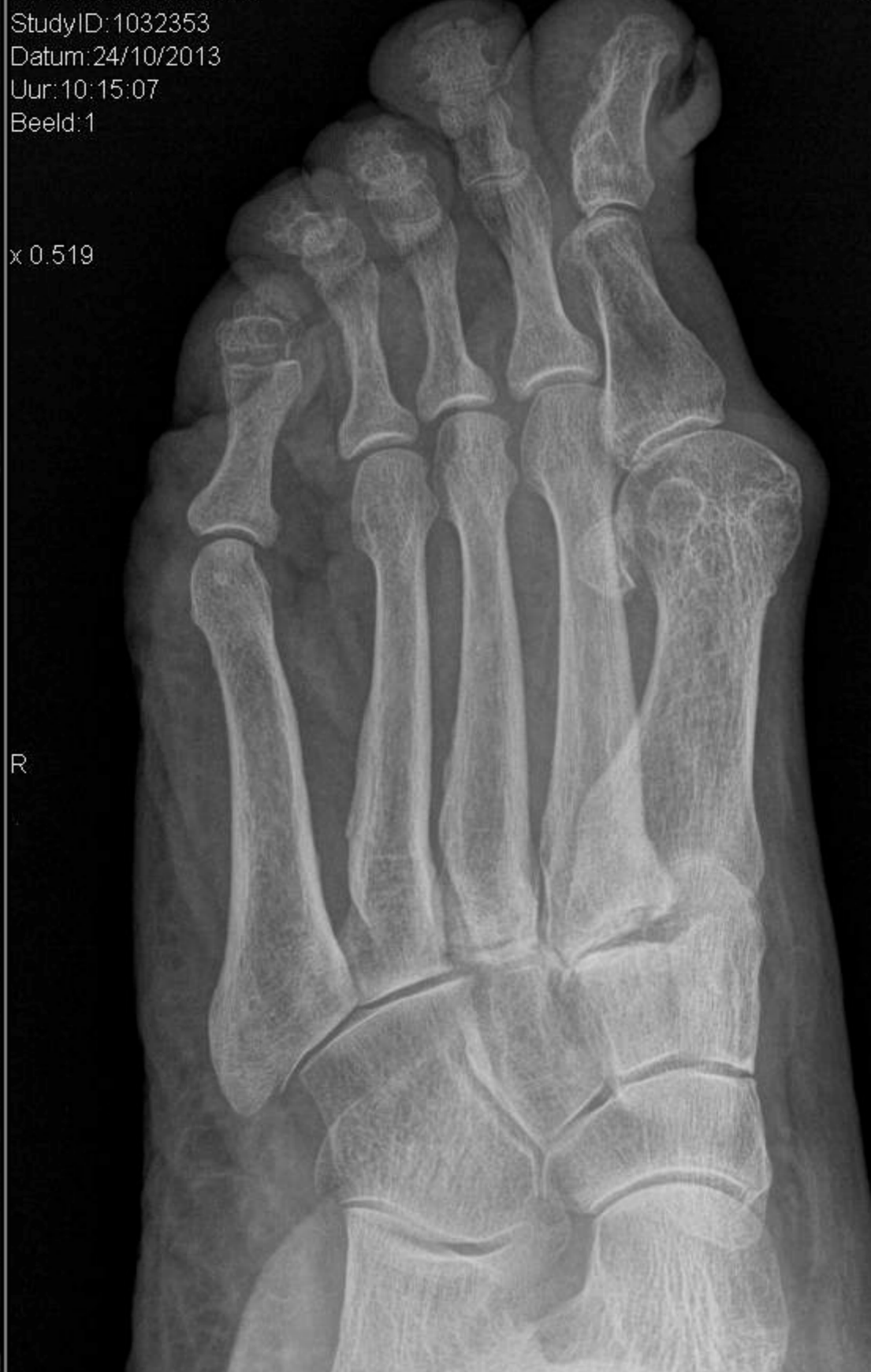R



StudyID: 1032353
Datum: 24/10/2013
Uur: 10:15:07
Beeld: 1

x 0.519

R



nr: 1064902
64902
03/2014
06

RefPhys:VANDEPUTTE





