
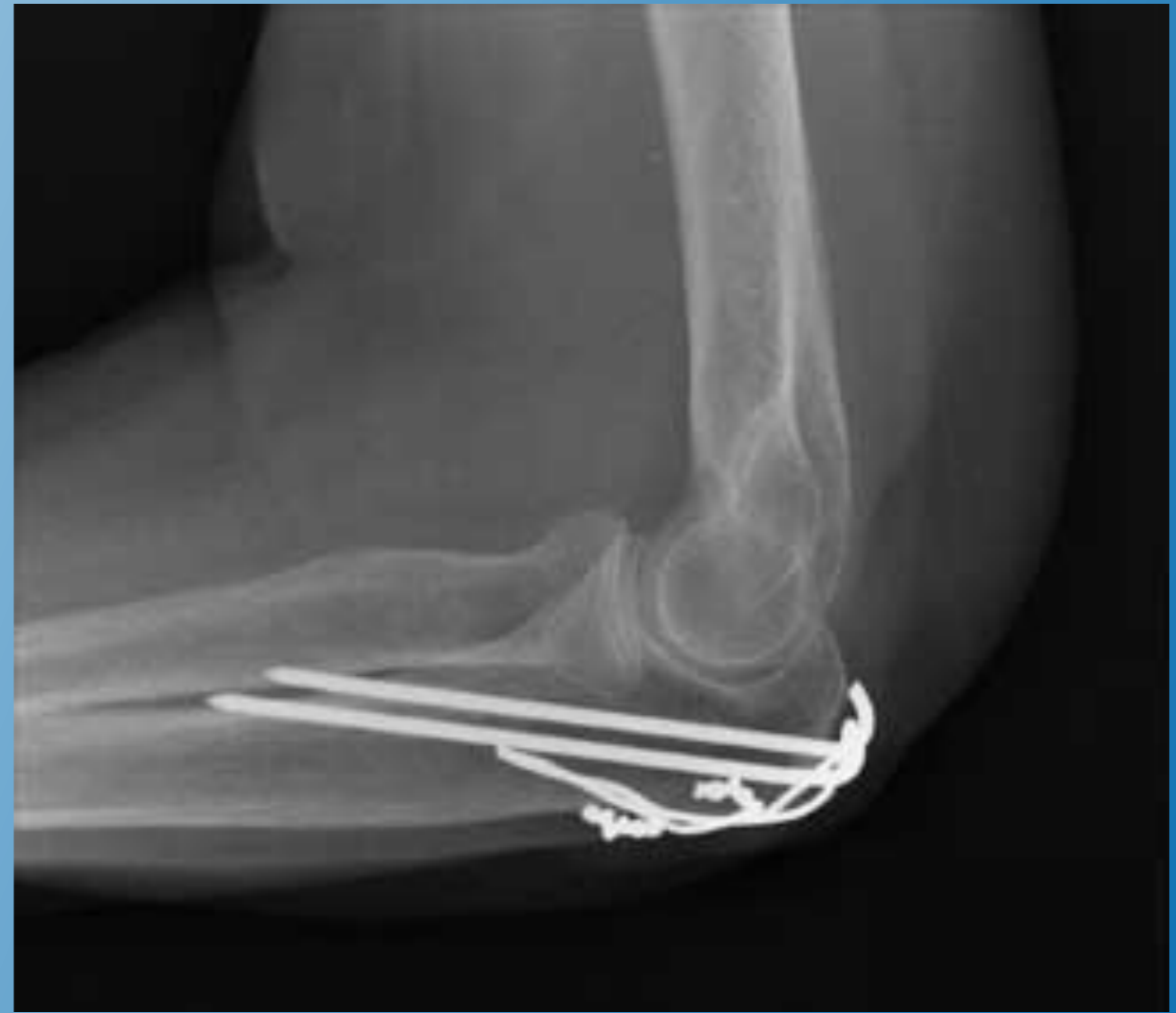
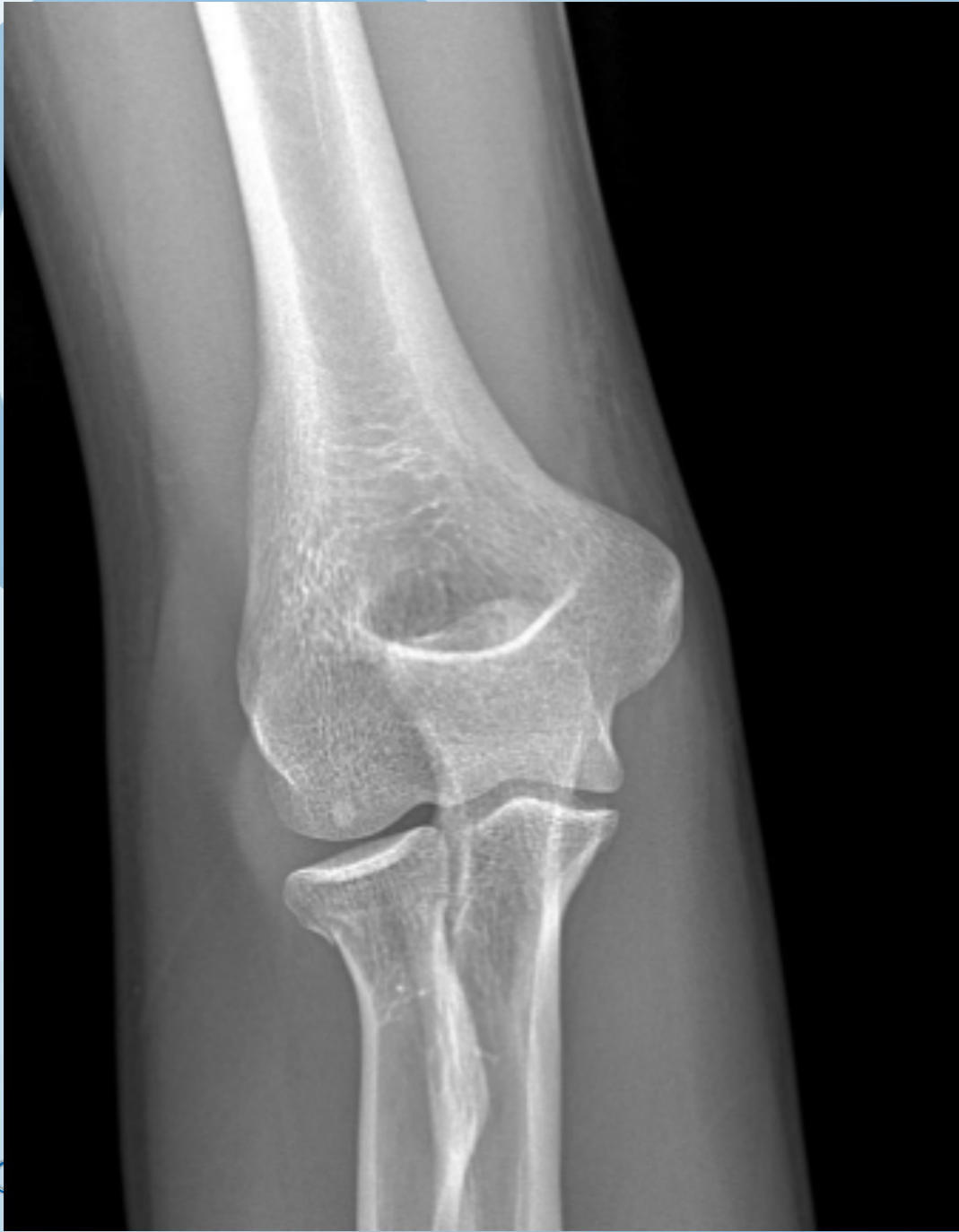A stylized tree logo with a light blue trunk and branches, and a large, light blue circular canopy. The tree is positioned on the left side of the slide, partially overlapping the main title text.

Elleboogletsels: meer dan breuken alleen

Dr. Ruben JACOBS

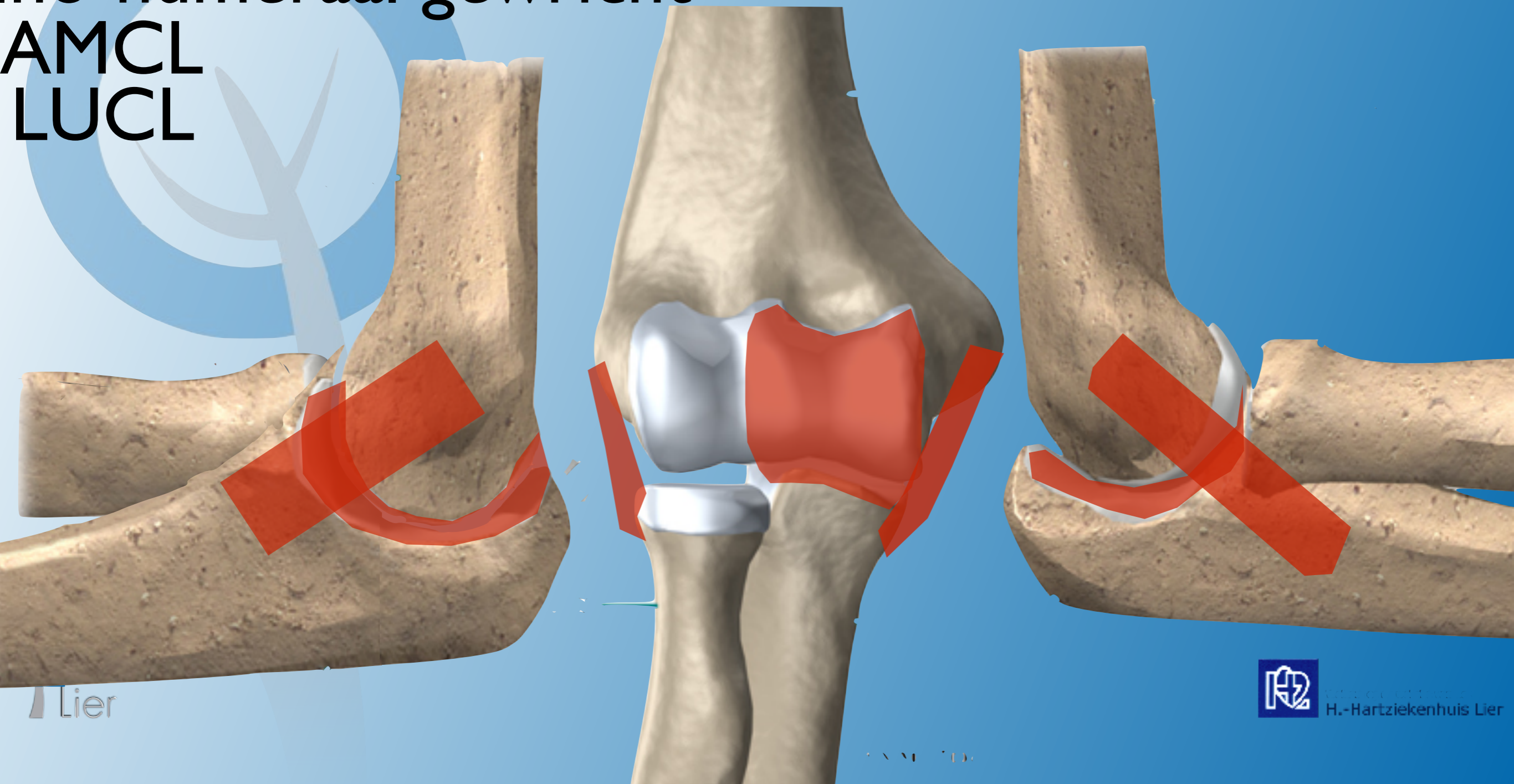


Primaire stabilisatie

Ino-humeraal gewricht

AMCL
LUCL

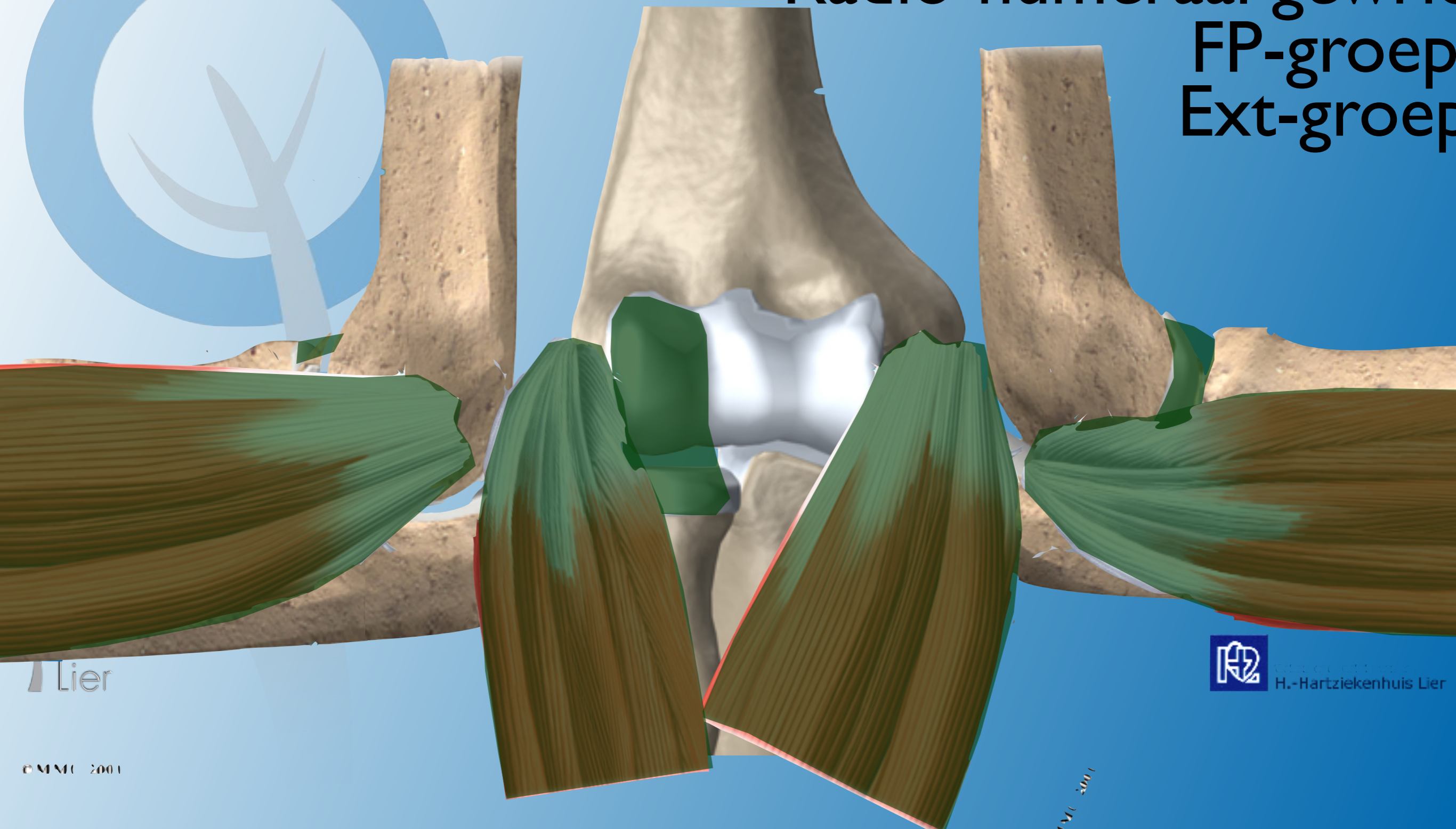
Secundaire stabilisatie



Primaire stabilisatie

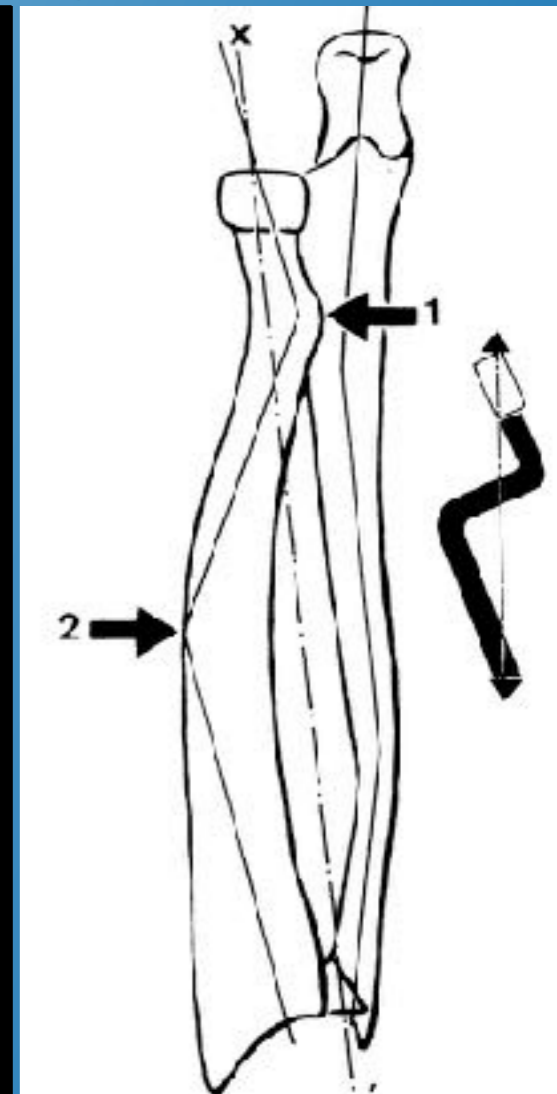
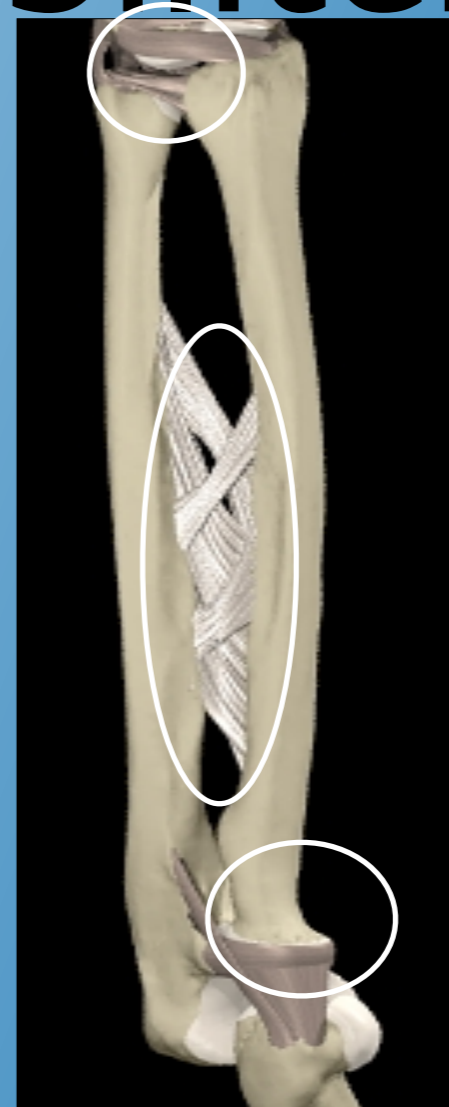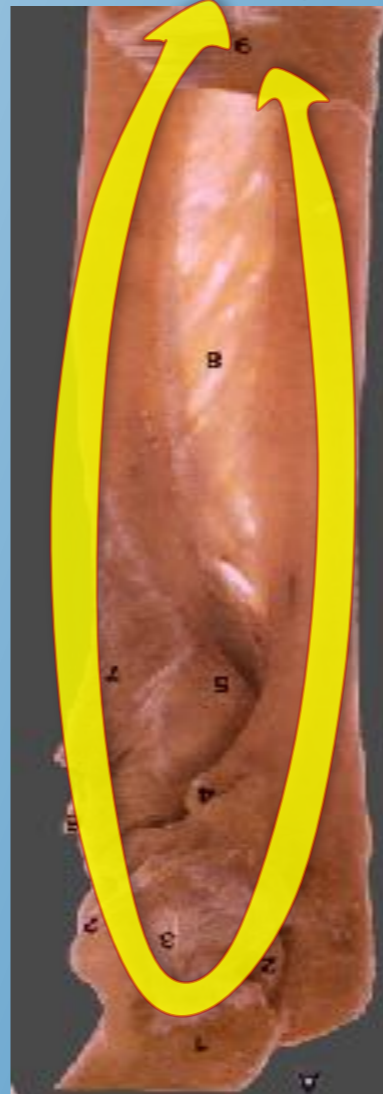
Secundaire stabilisatie

Radio-humeraal gewricht
FP-groep
Ext-groep



Onderarm stabiliteit

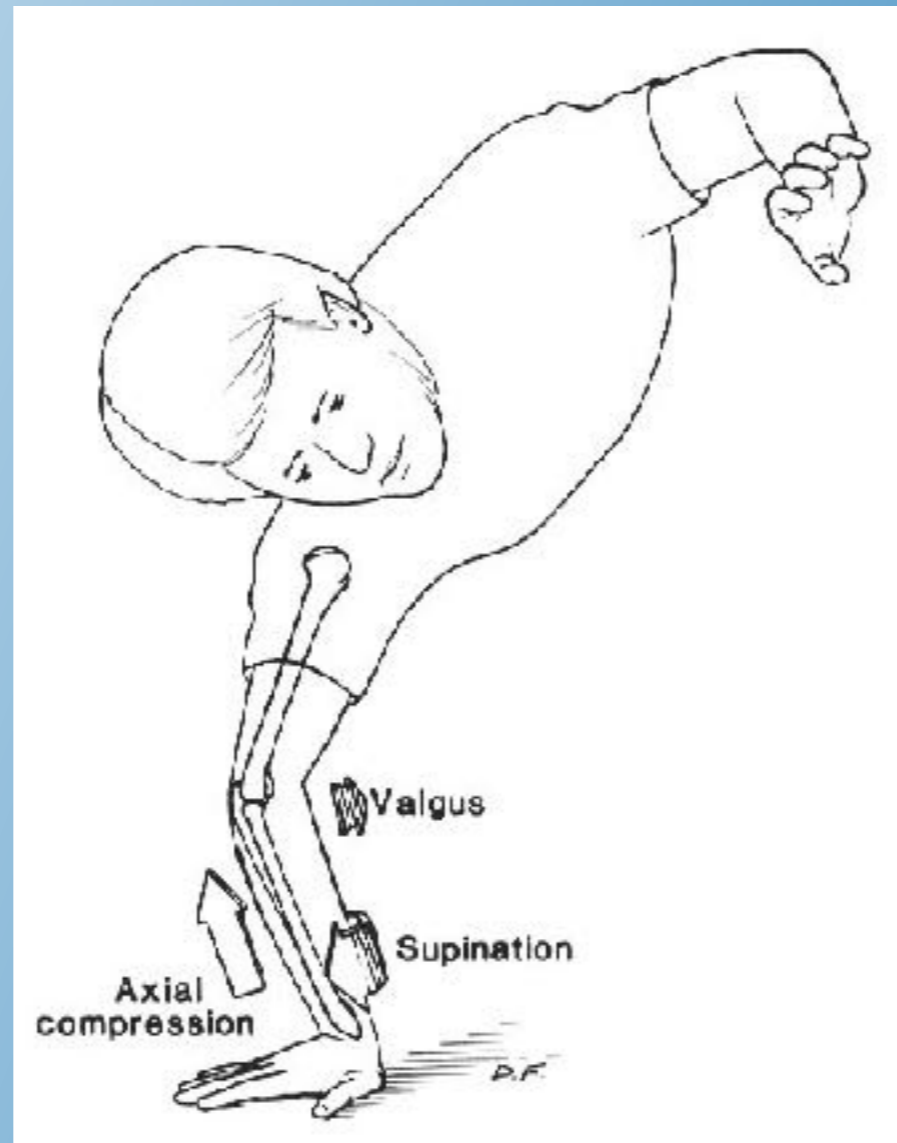
- Onderarm ring concept
- sleutelrol:
 - radiuskop
 - MIO
 - TFCC
- Dubbele of multiple letsel aan deze ring zijn frequent



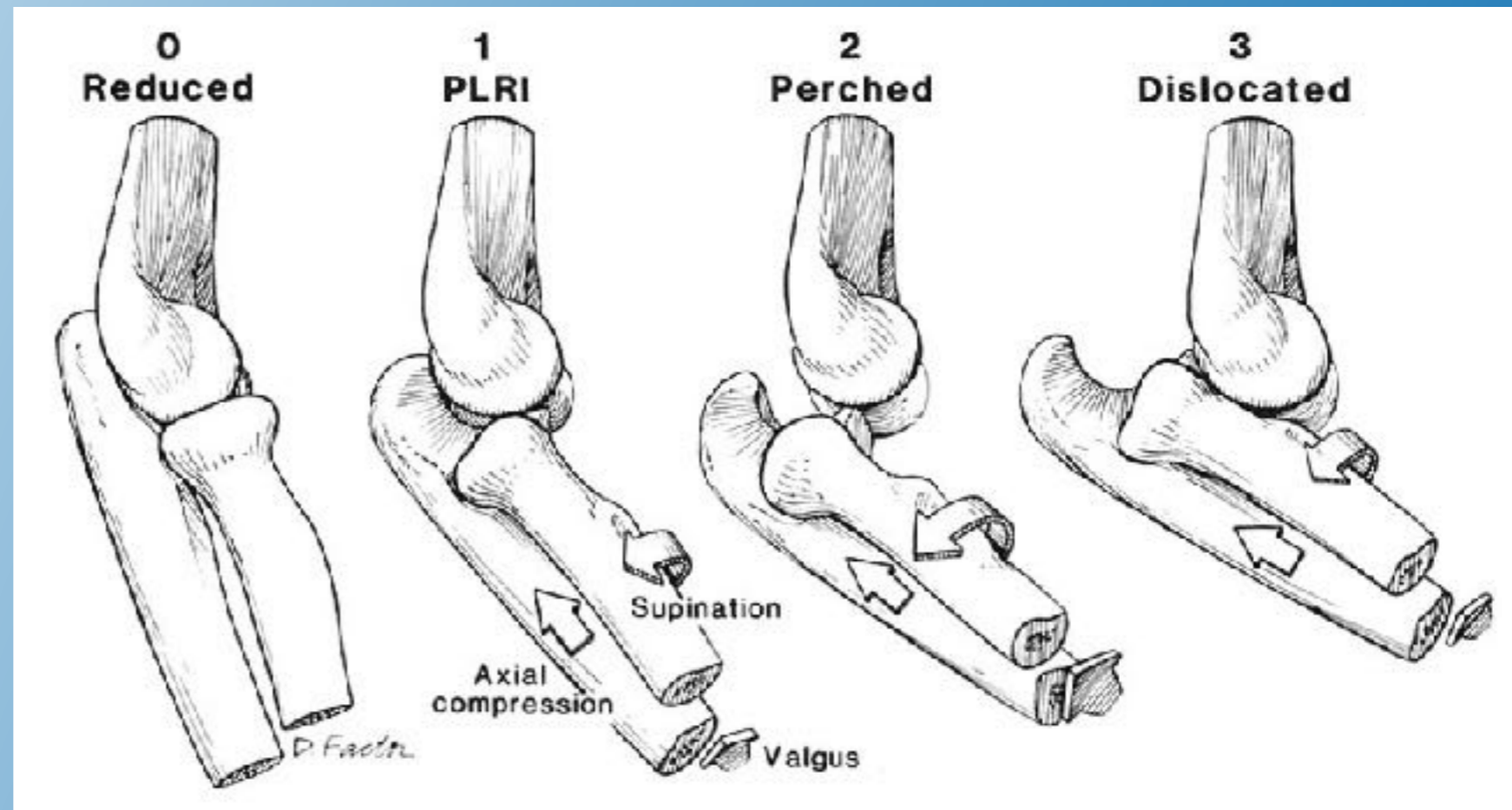
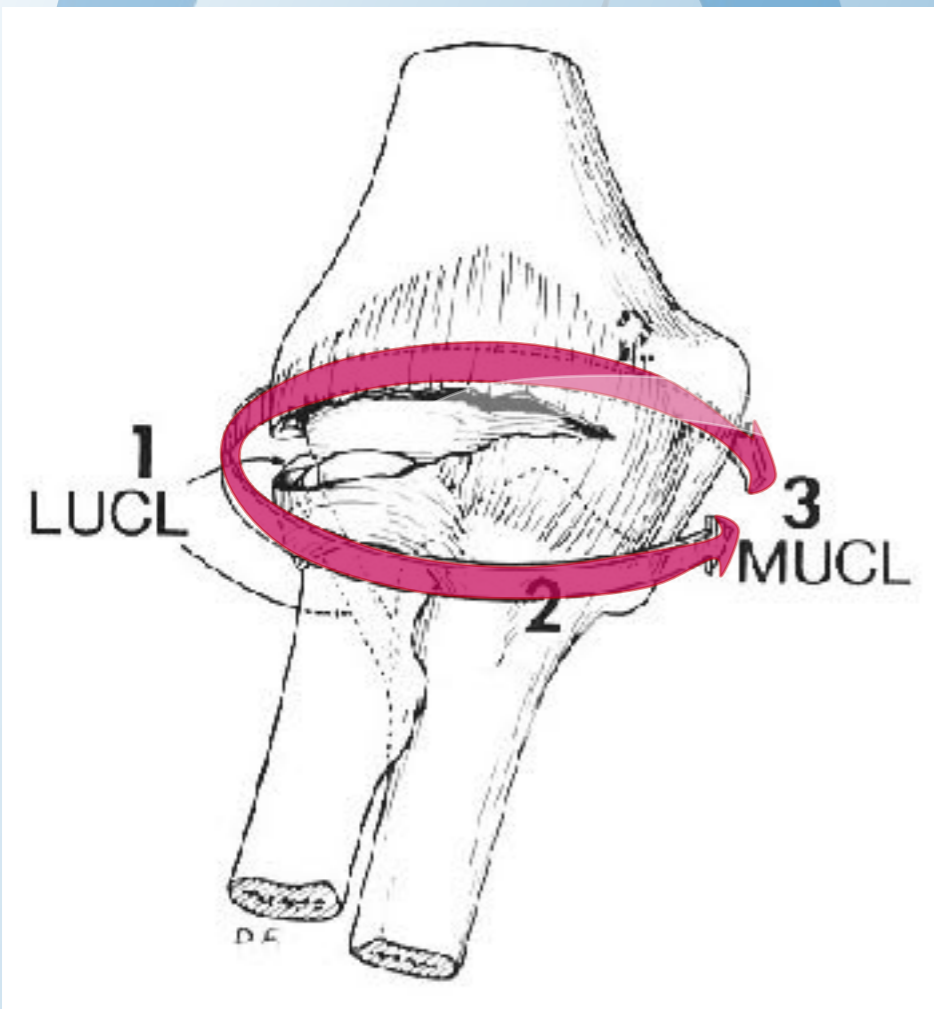
Elleboogfracturen met instabiliteit:

- **Terrible Triad**
- Transolecranon Fractuur Luxaties,
Posterieure Monteggia letsels
- Essex-Lopresti letsels

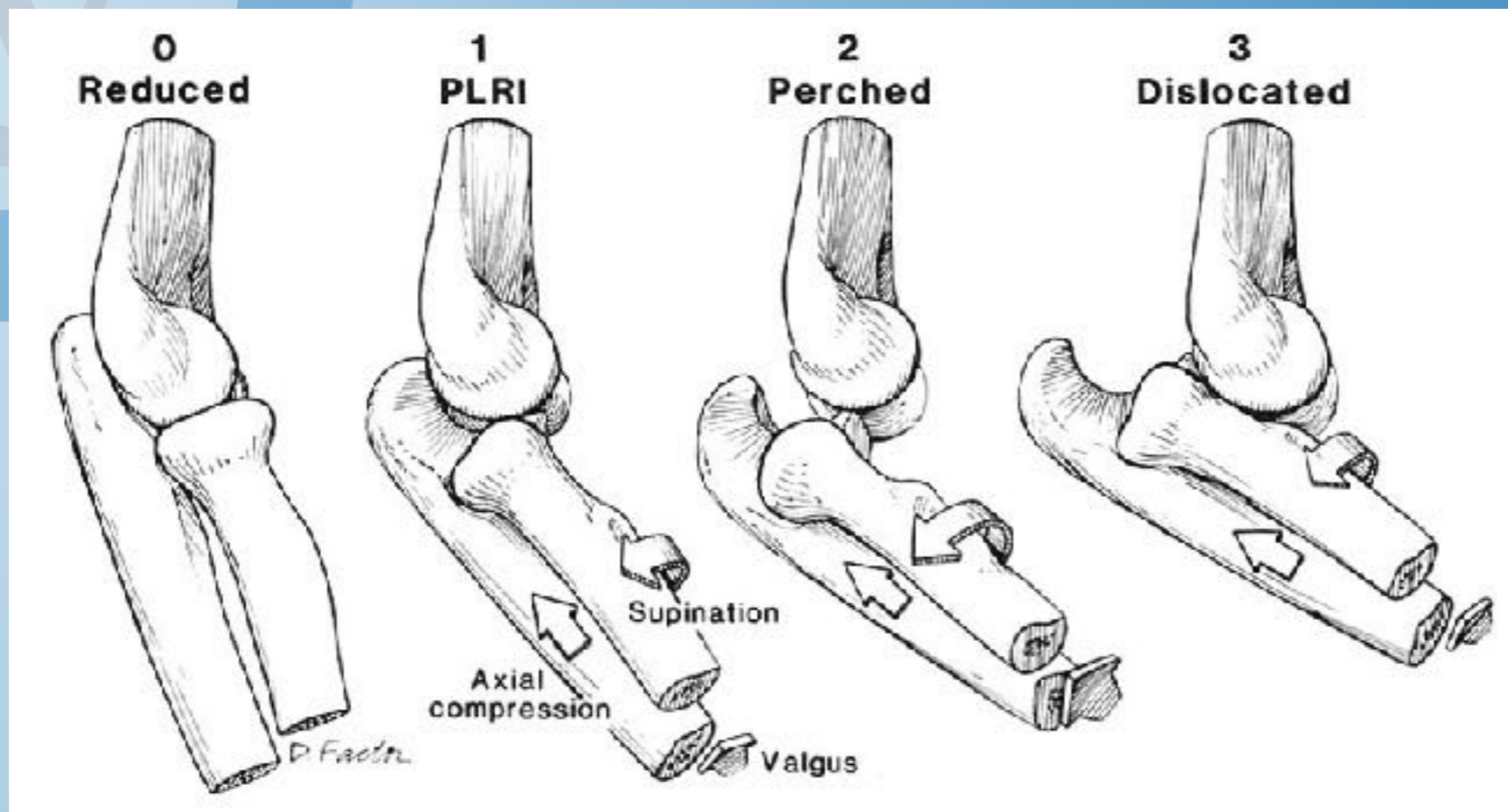
Terrible triad

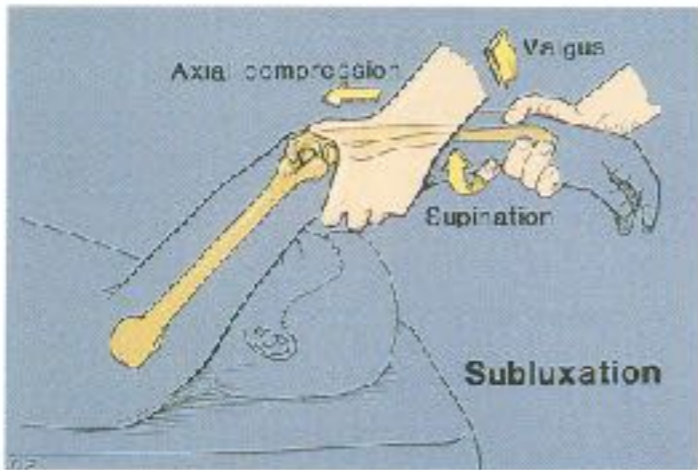


Pathoanatomy

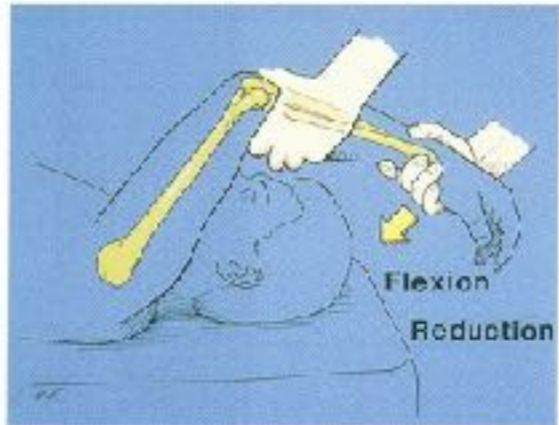


Posterolaterale rotationele instabiliteit (PLRI)

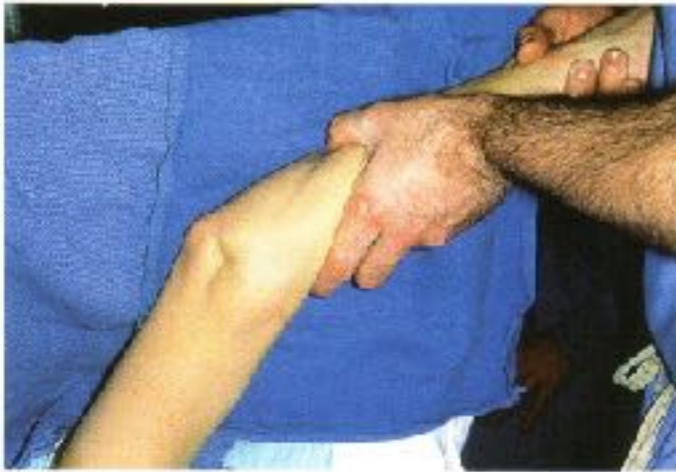



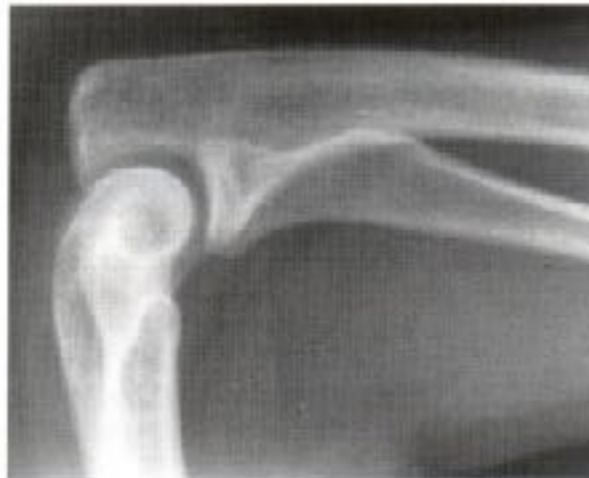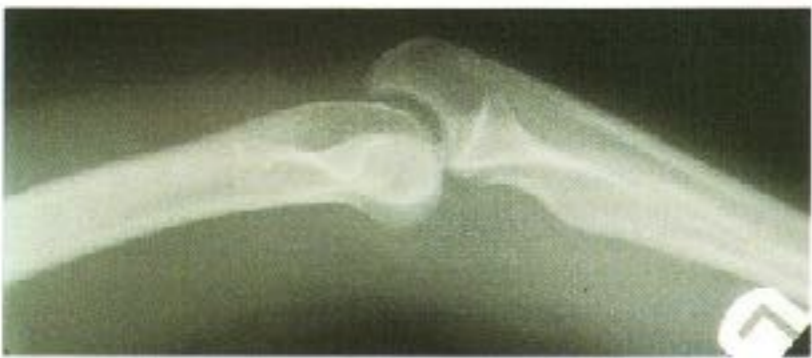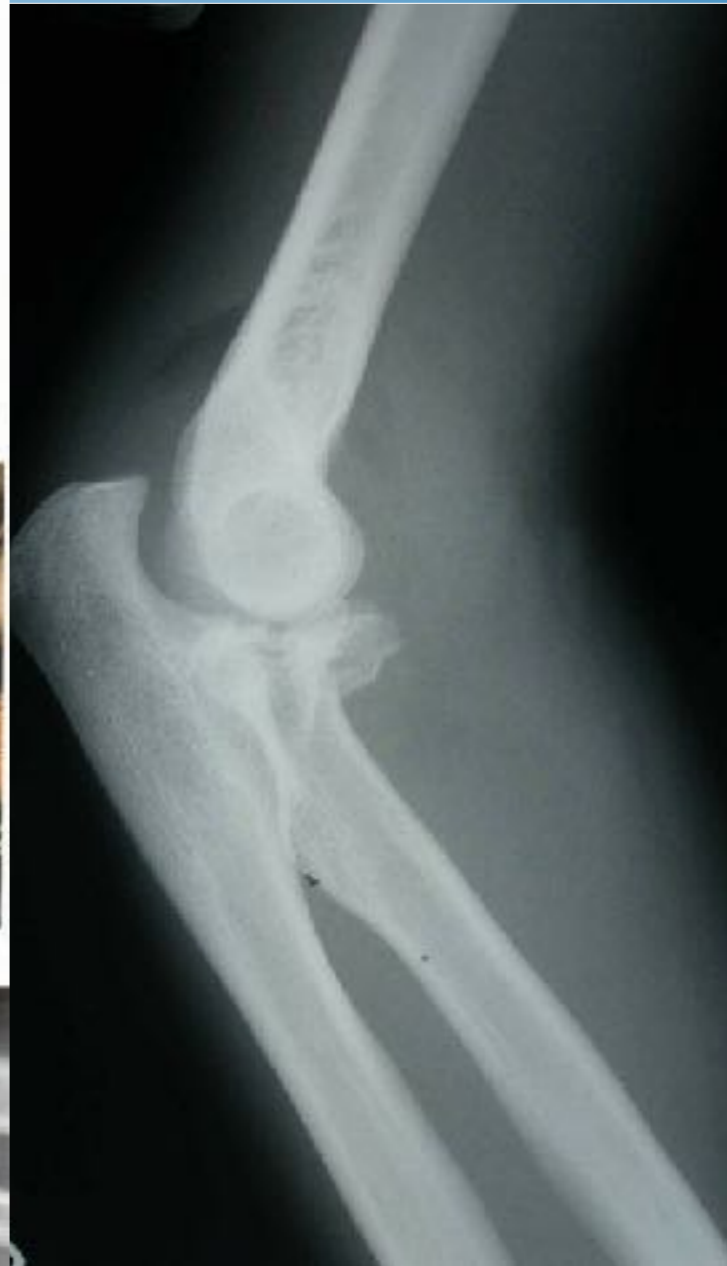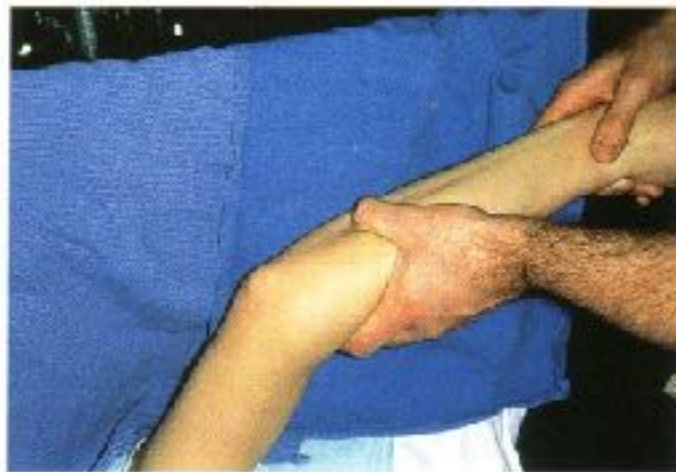A1



B1

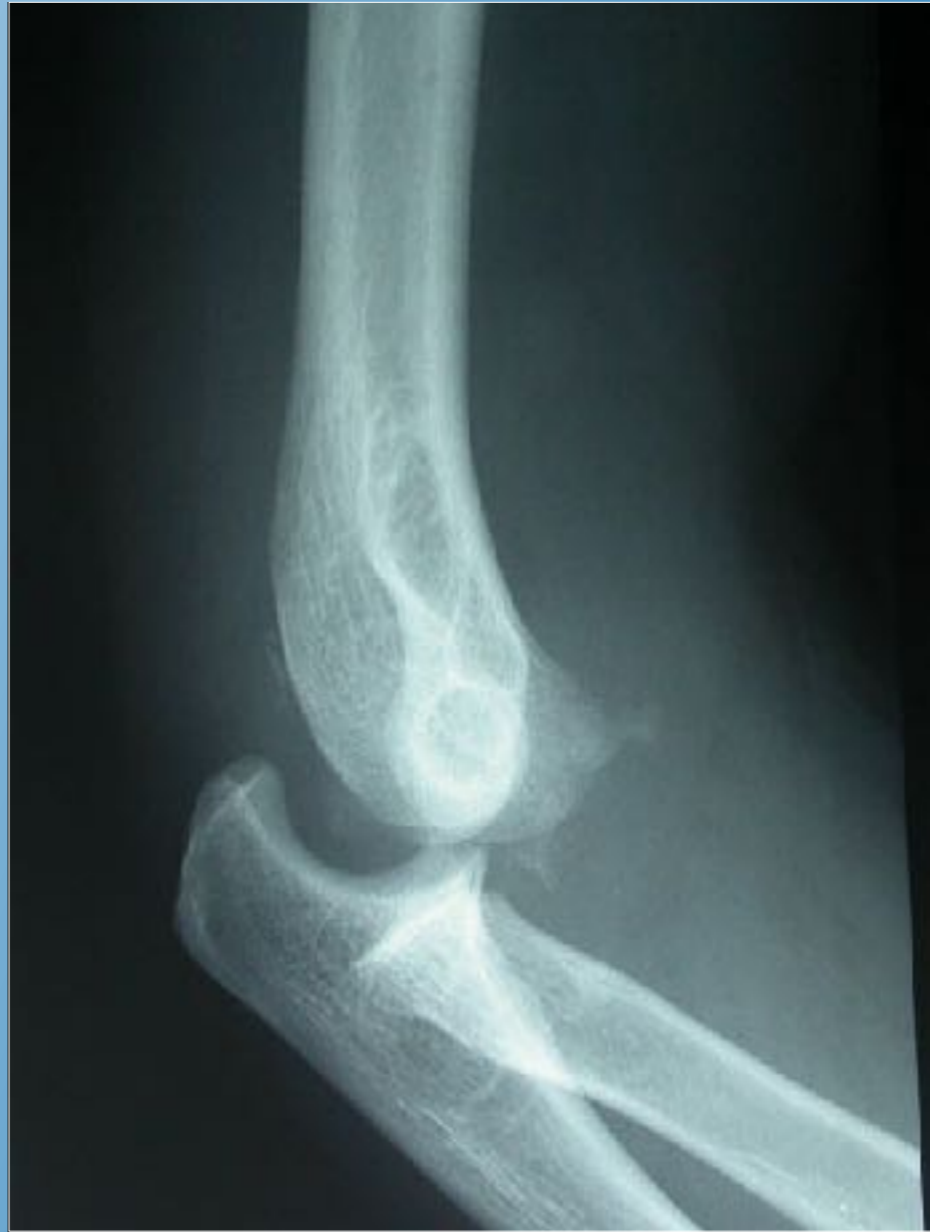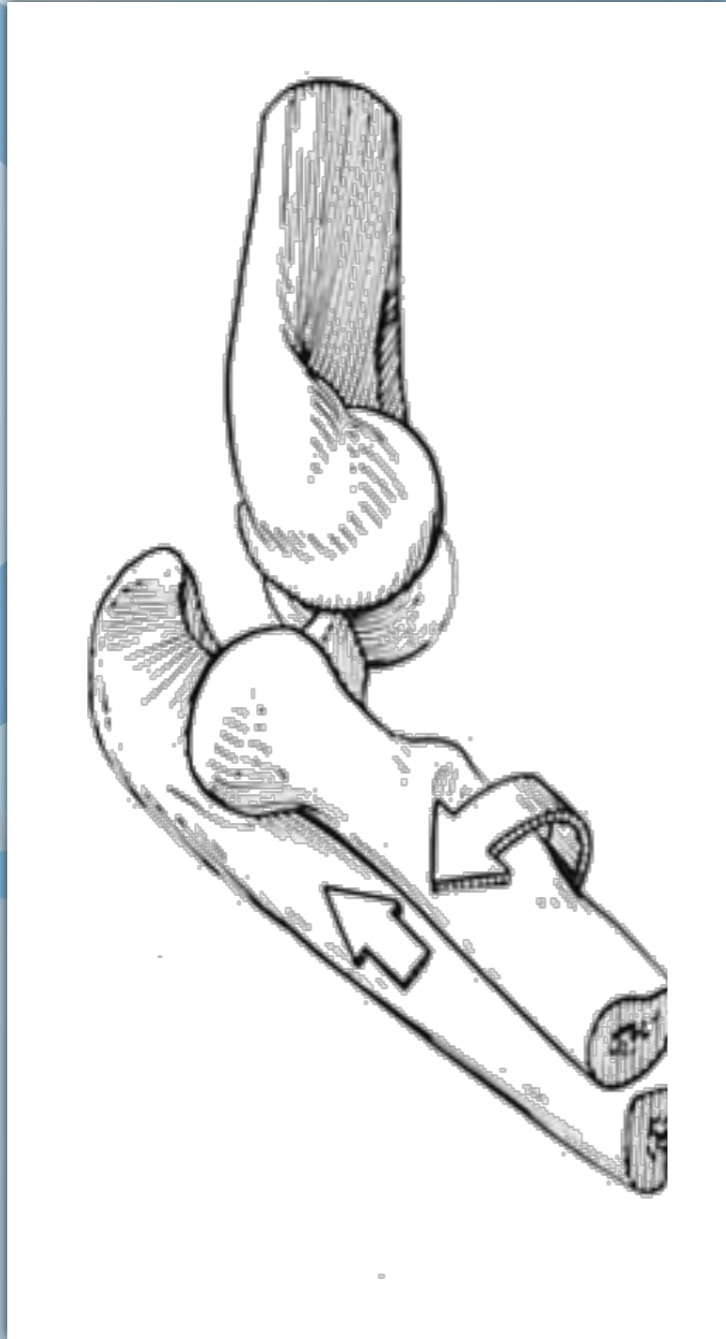


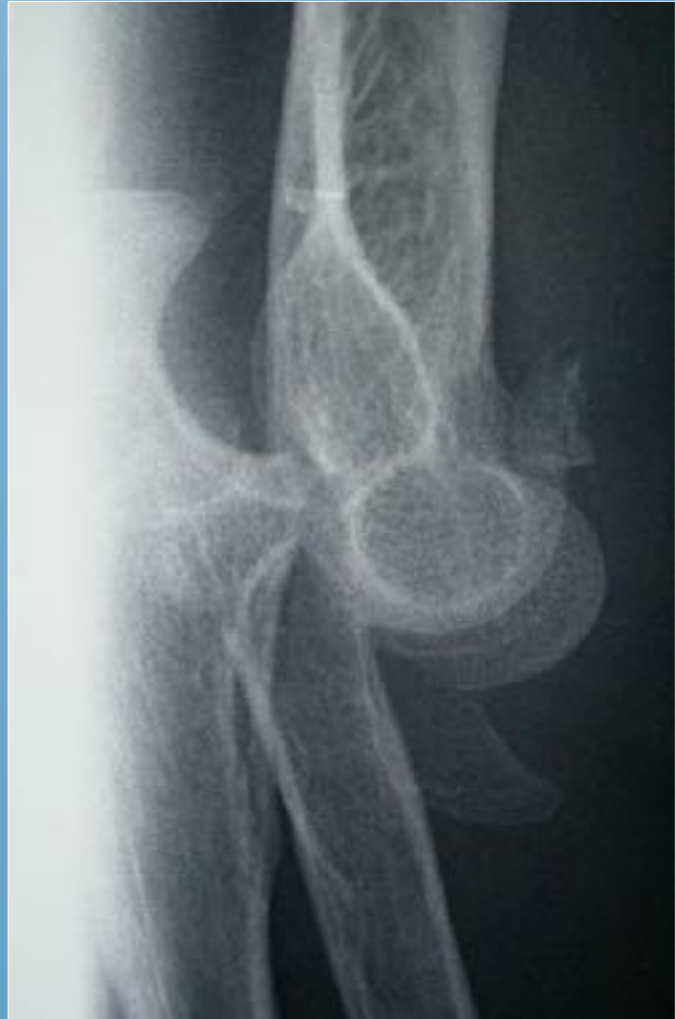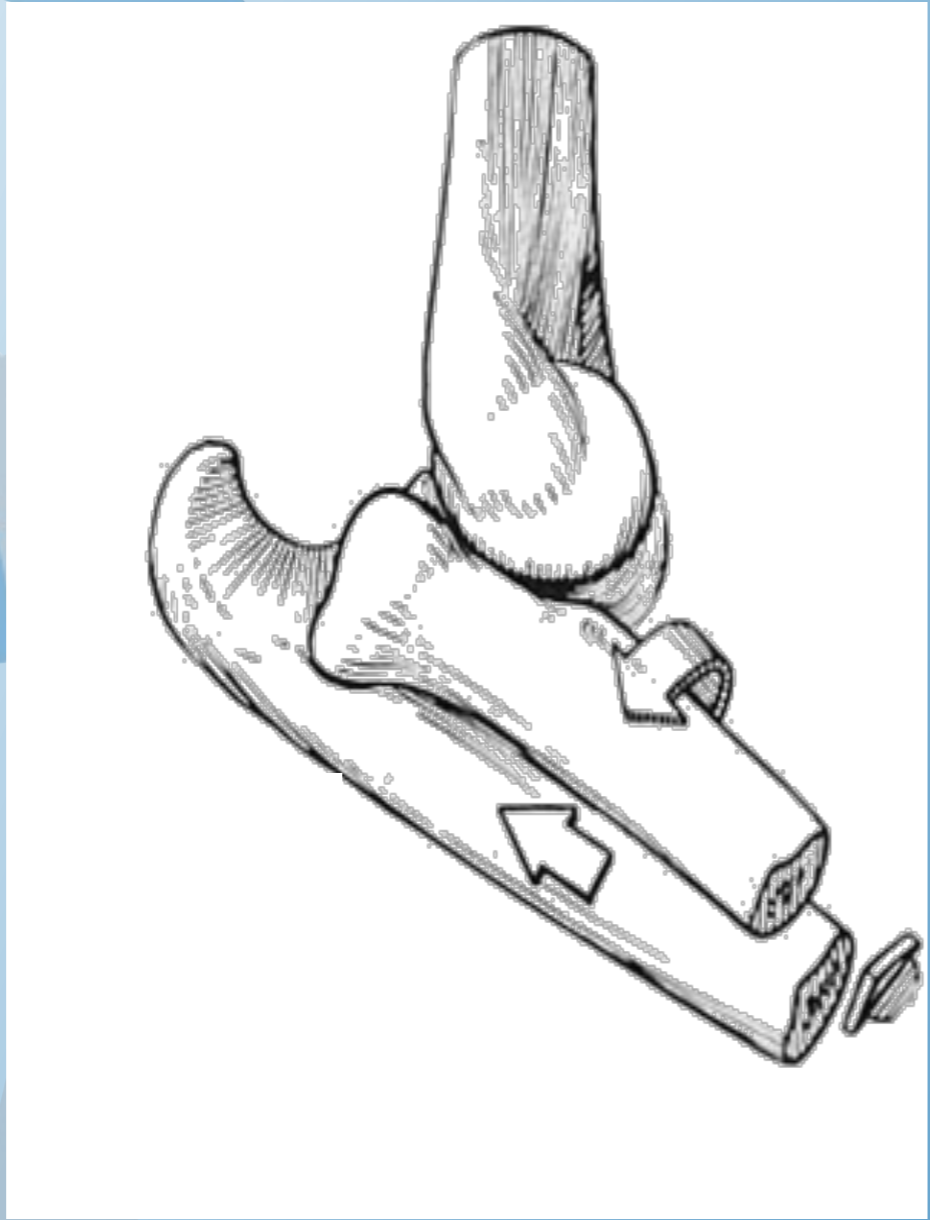
A2



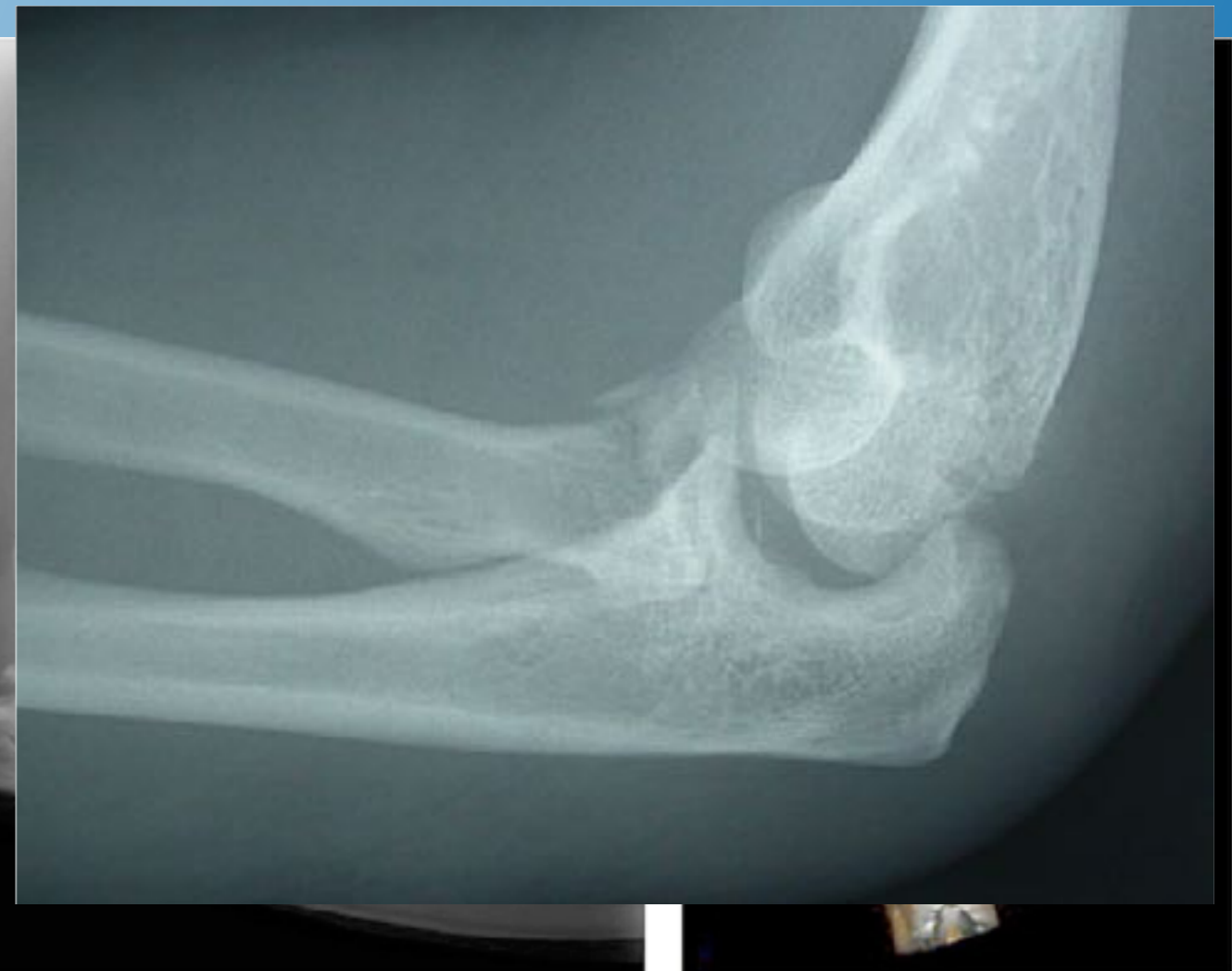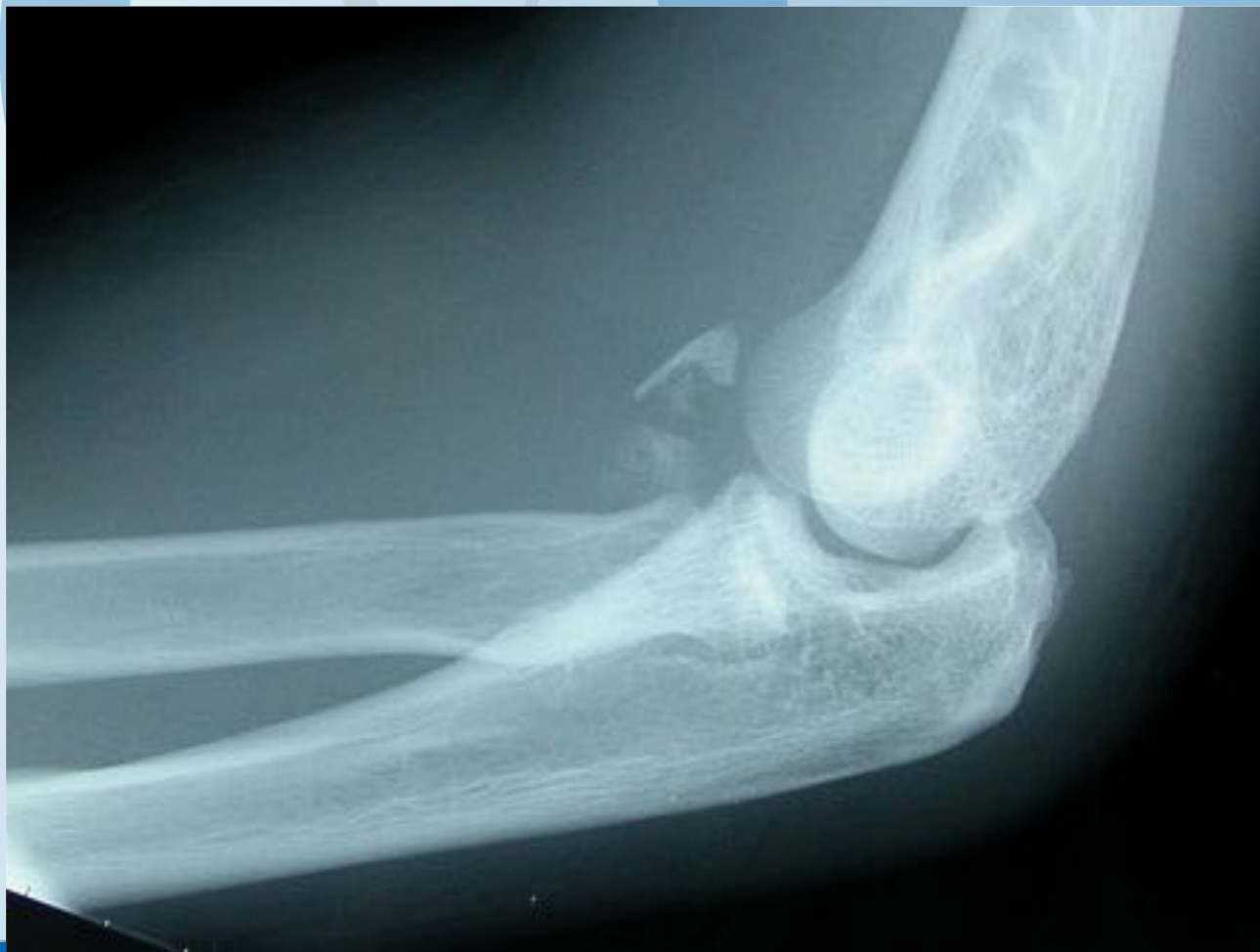A3





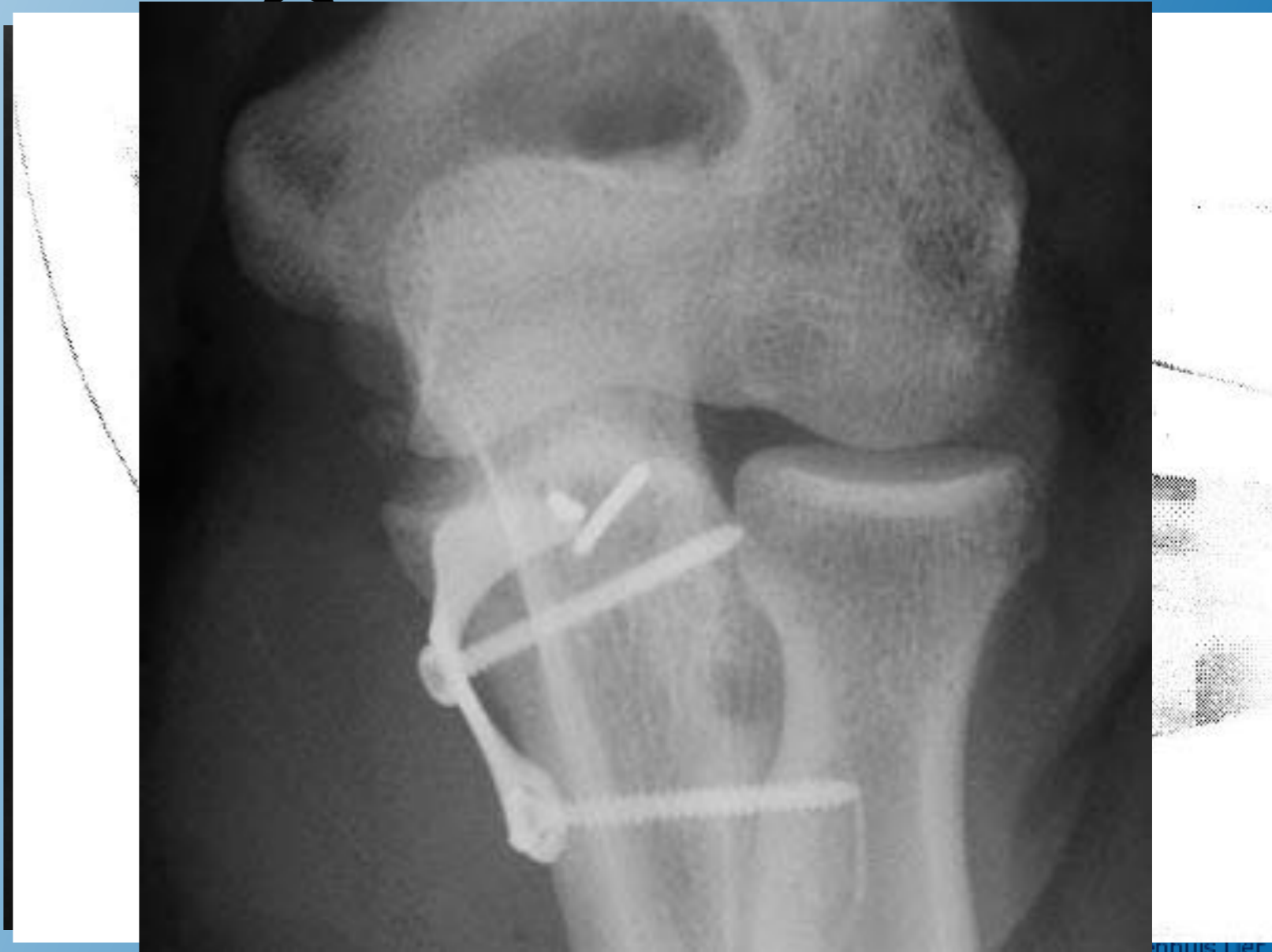

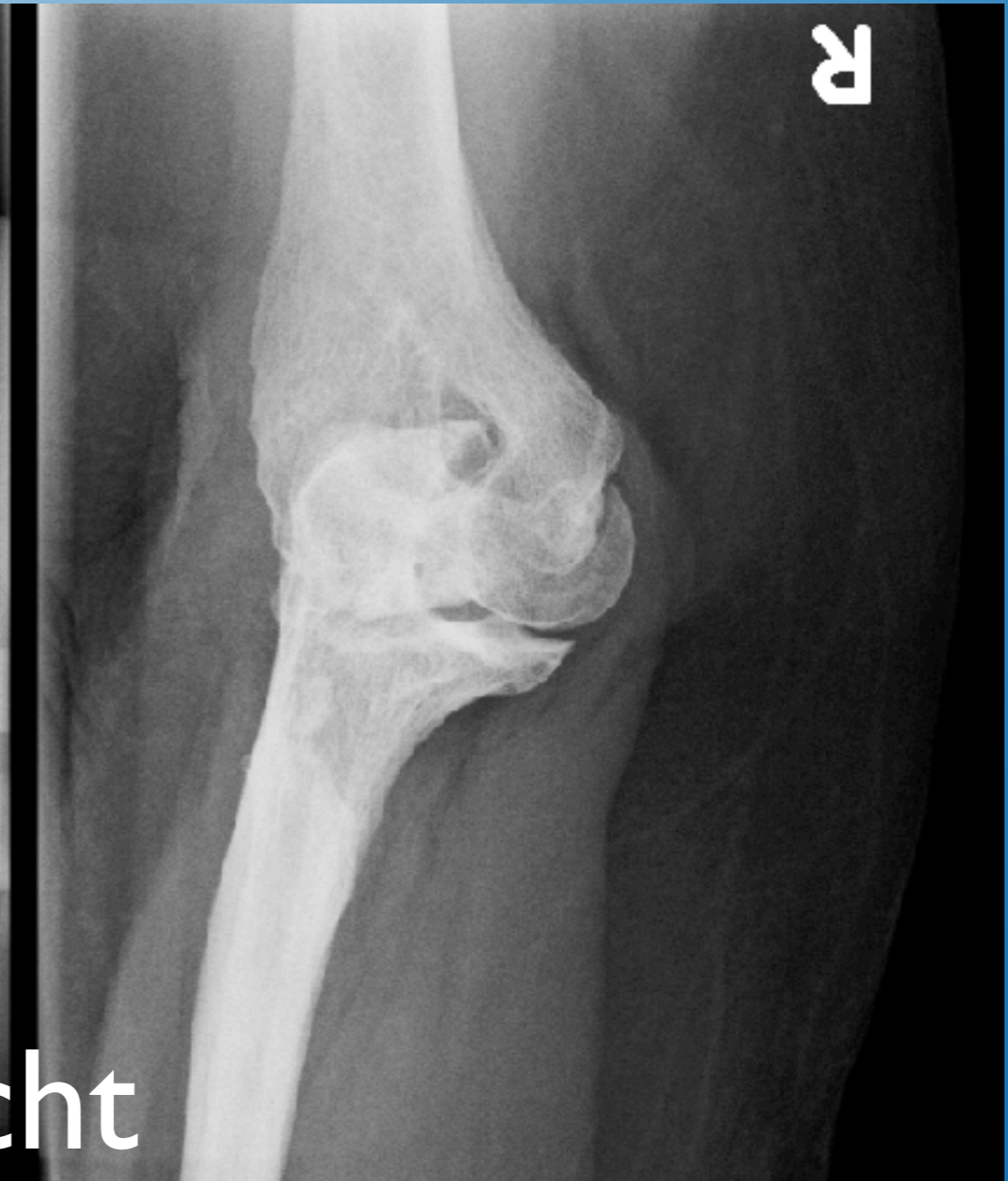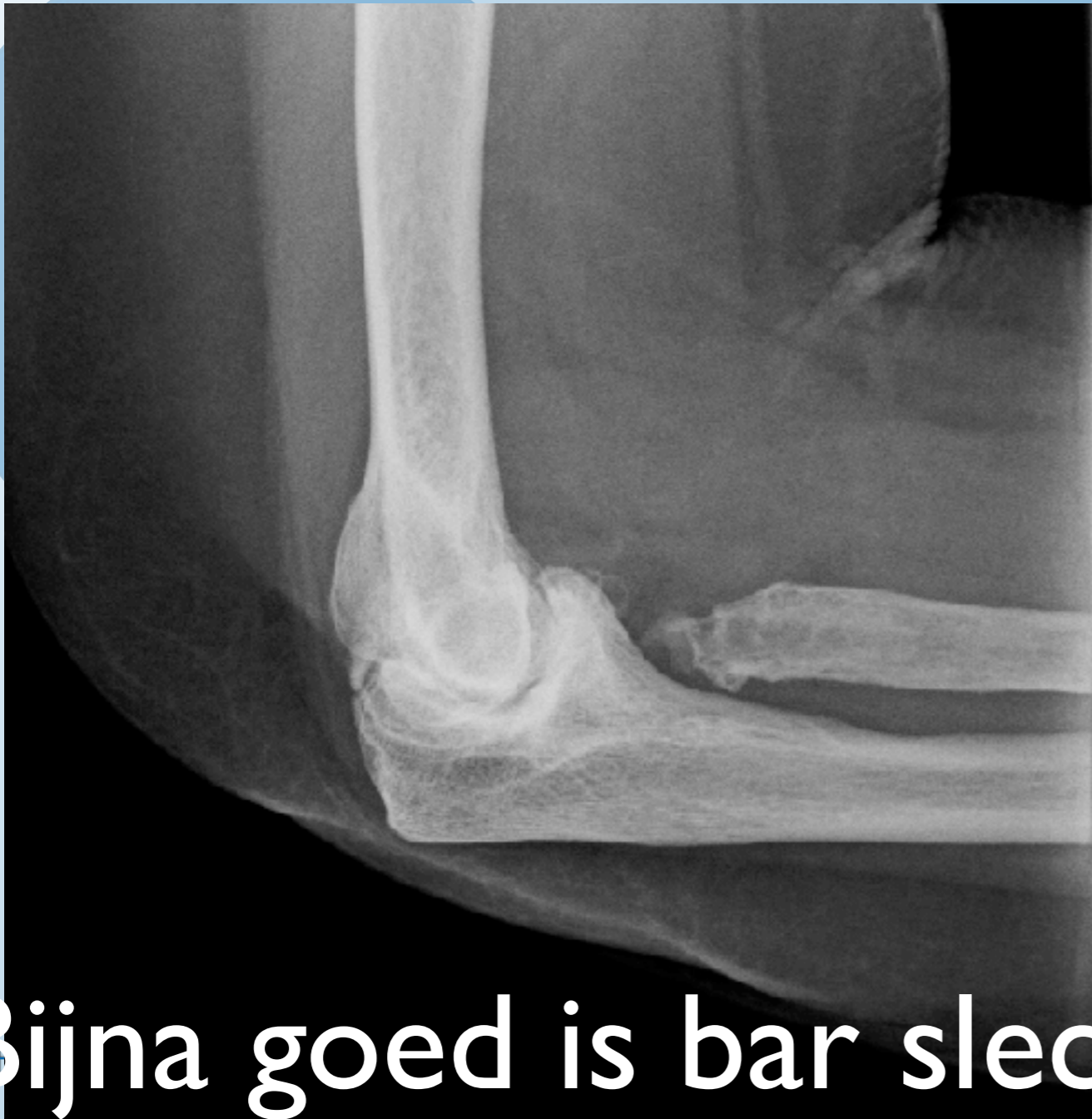Terrible Triad



Behandeling Terrible

- Herstell radiuskop
- osteosynthese of prothese
- Herstell LUCL: botanker



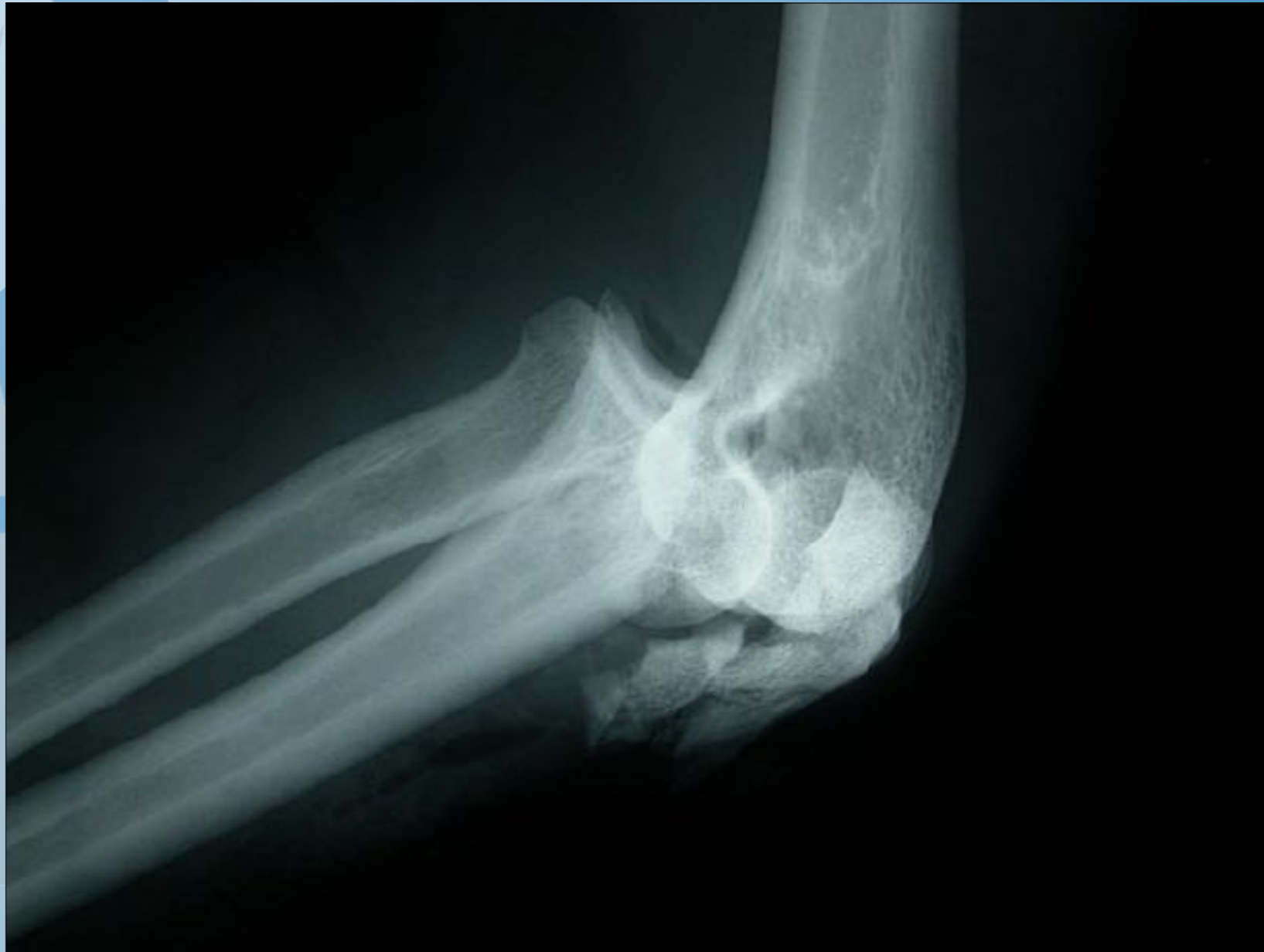

 **Bijna goed is bar slecht**

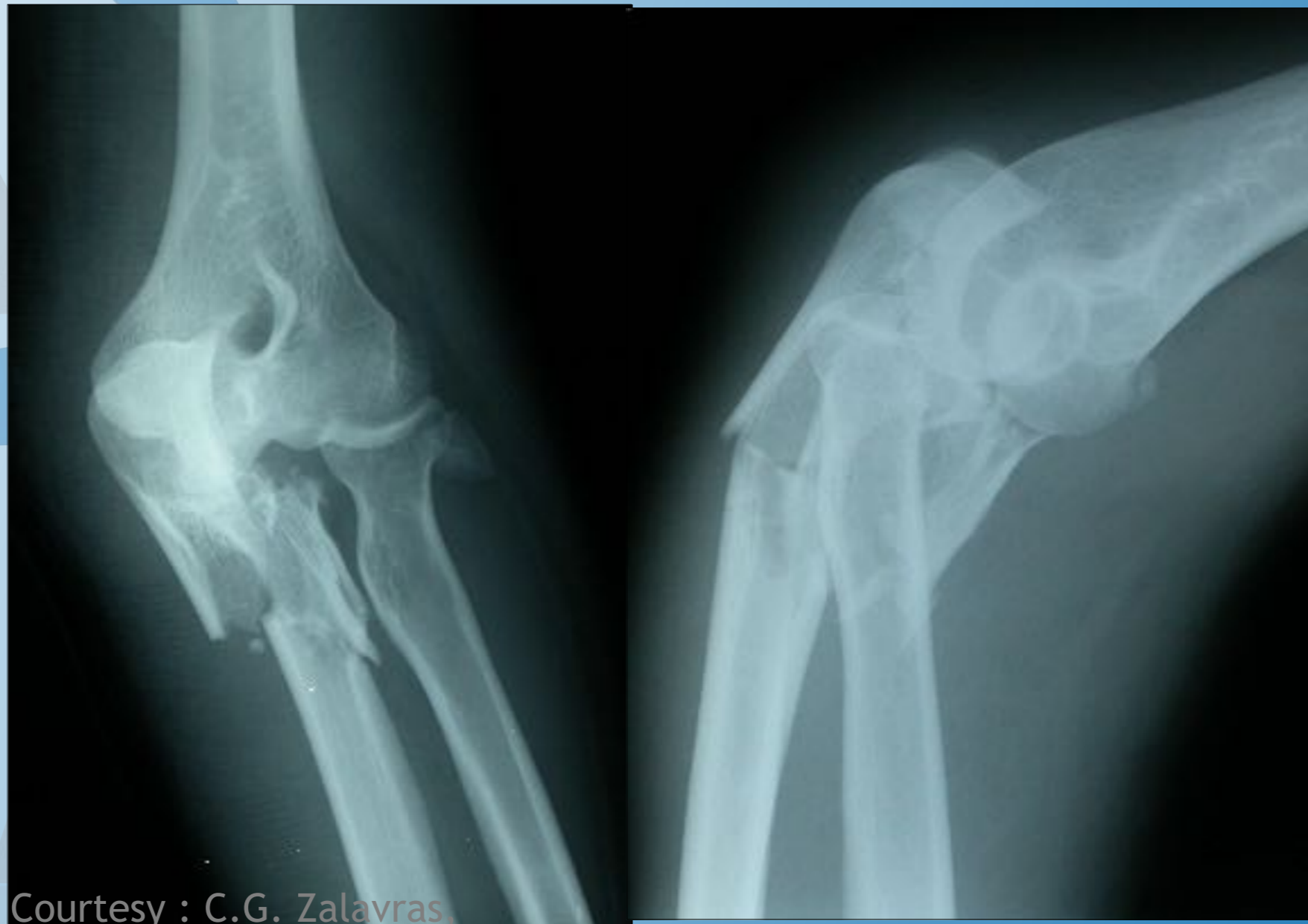Elleboogfracturen met instabiliteit:

- Terrible Triad
- Transolecranon Fractuur Luxaties, Posterieure Monteggia letsels
- Essex-Lopresti letsels

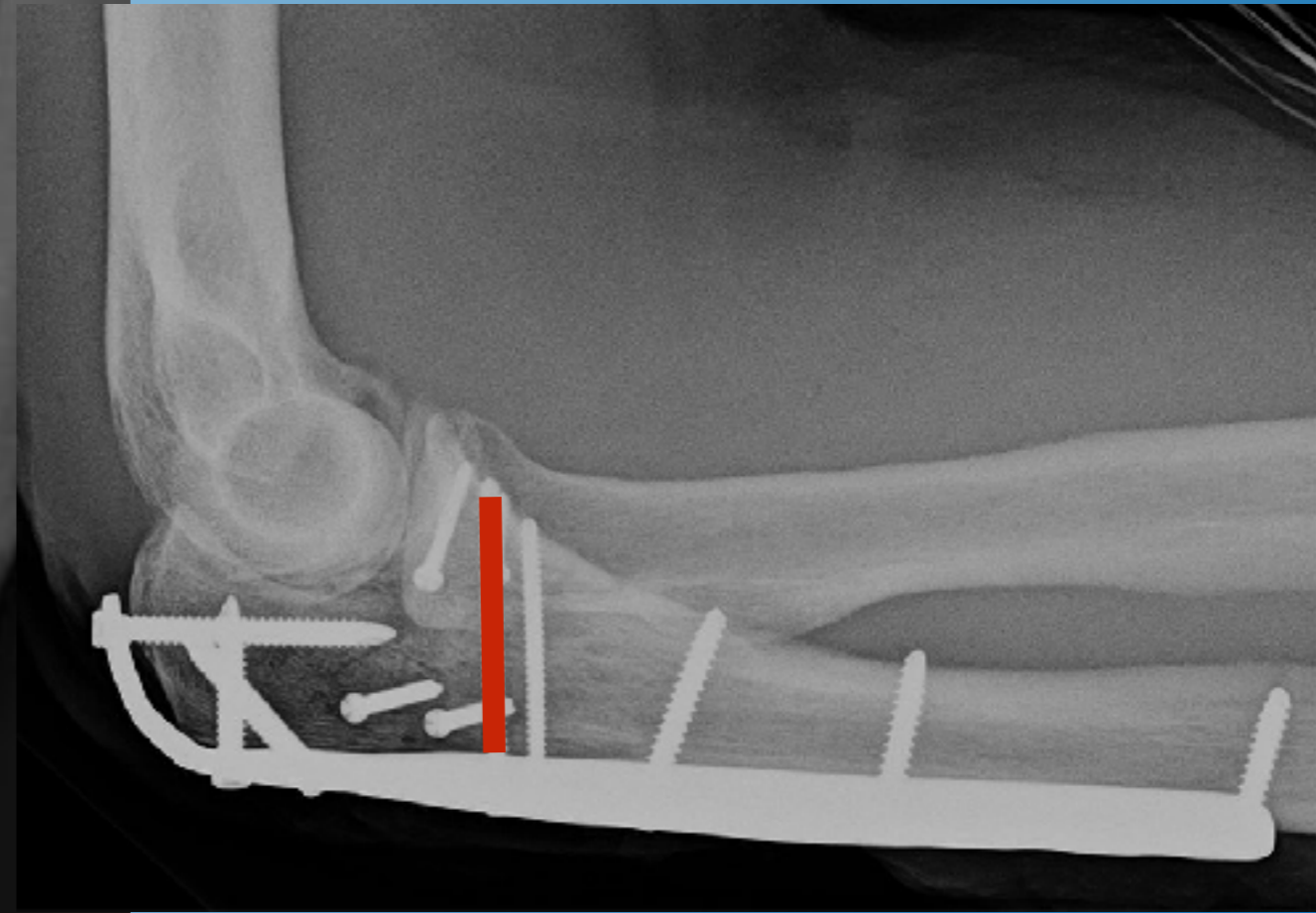
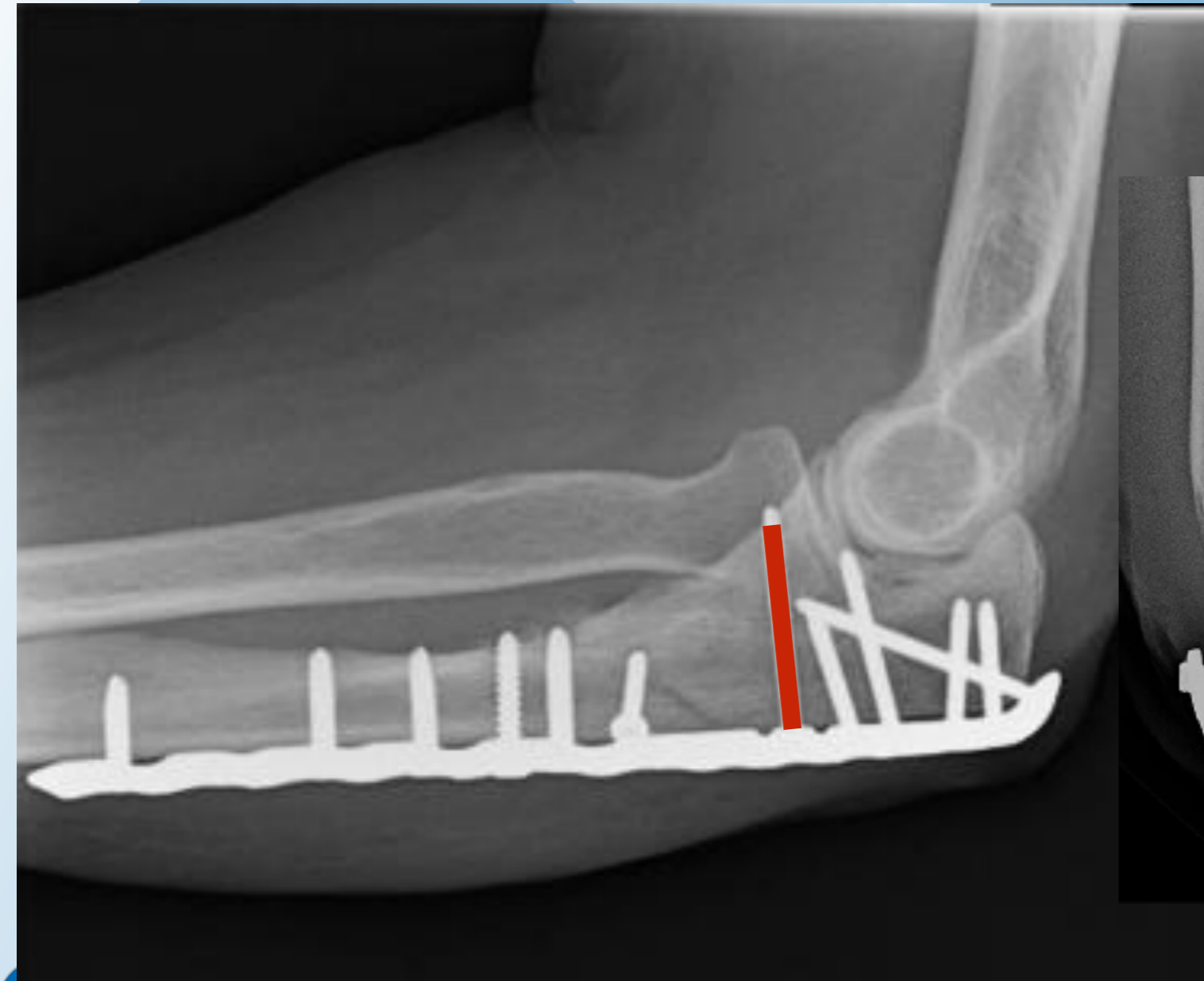
Transolecranon fractuur-luxatie



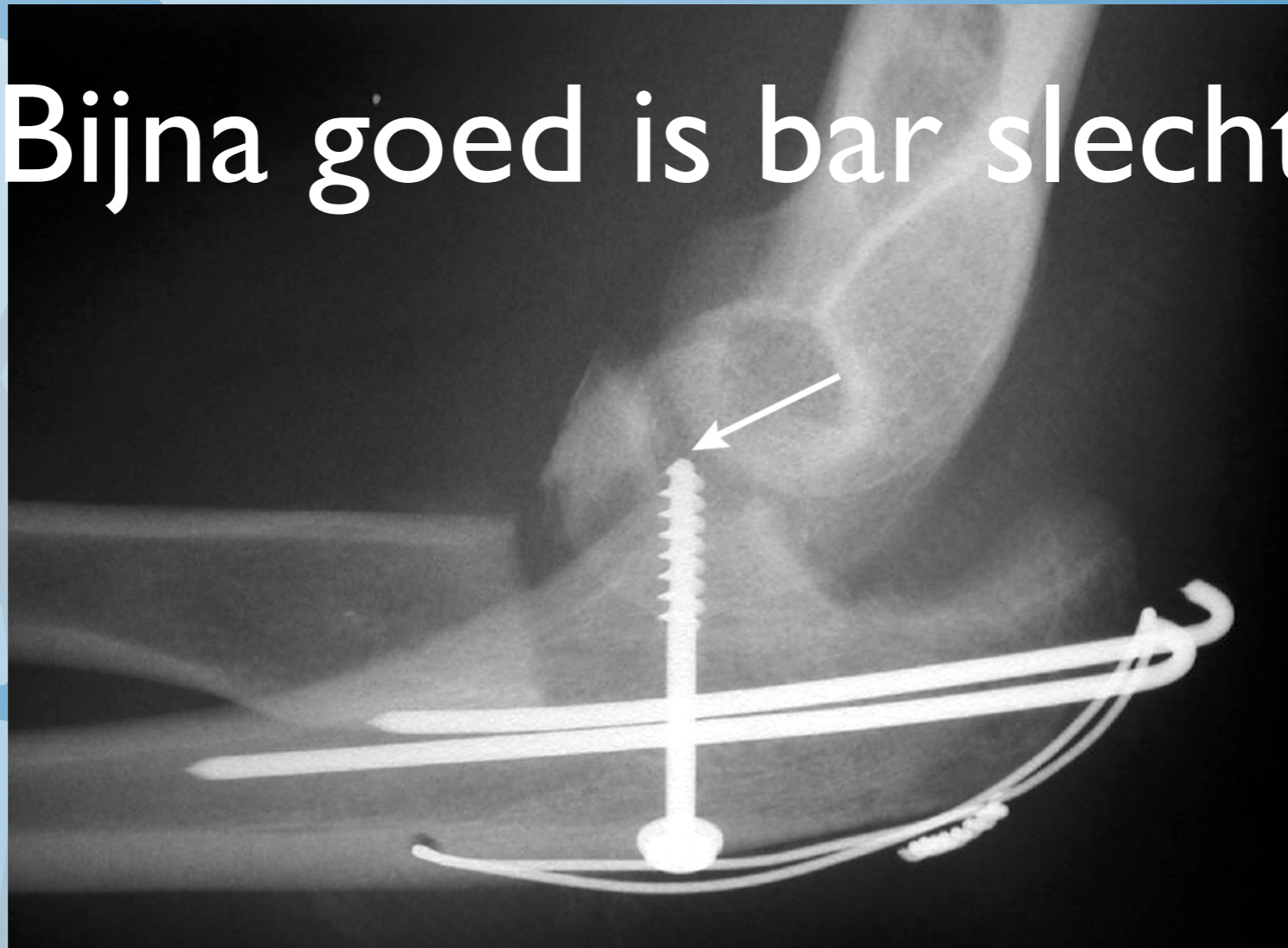
Posterieur Monteggia letsel



Courtesy : C.G. Zalavras,
MD



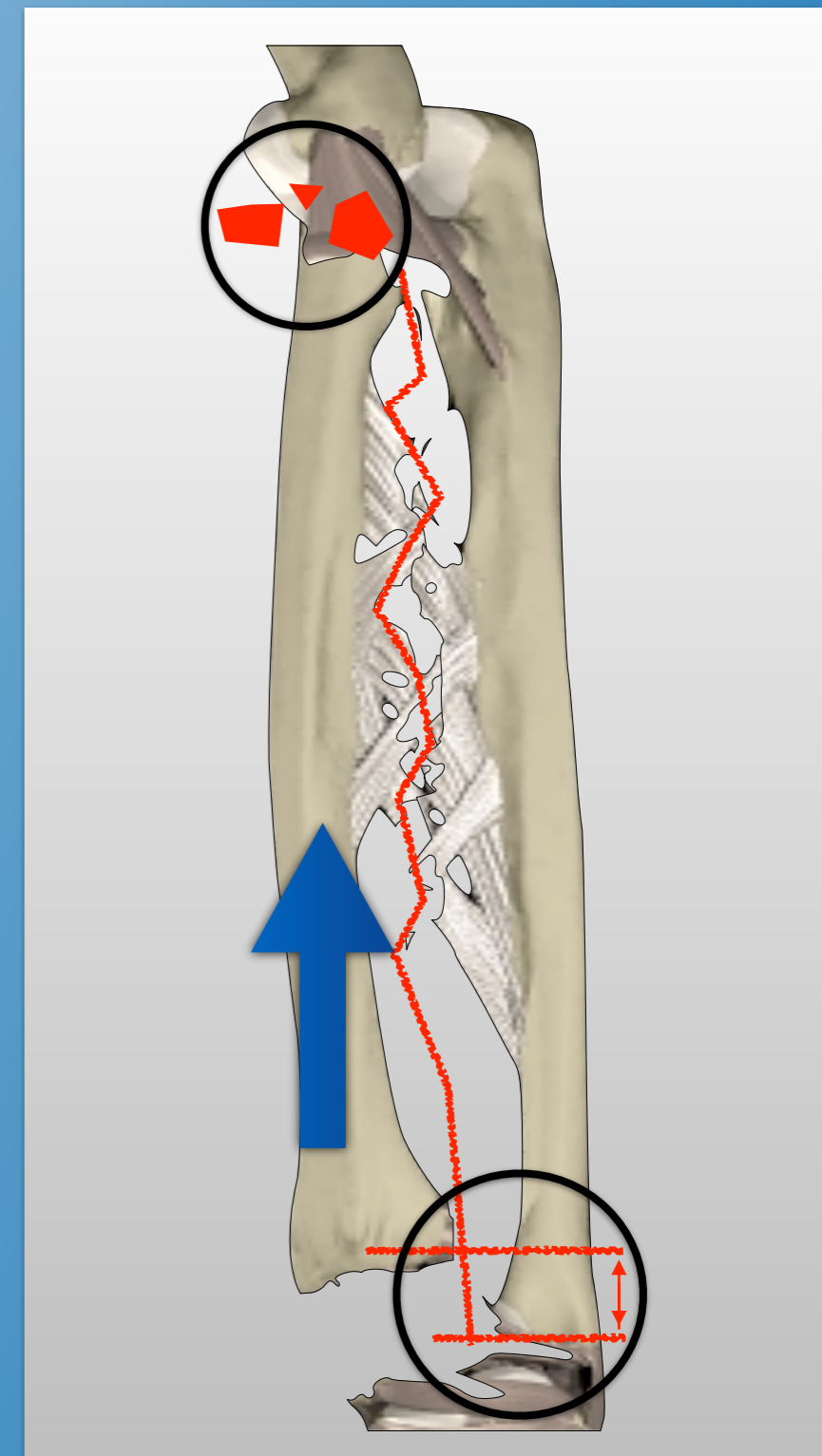
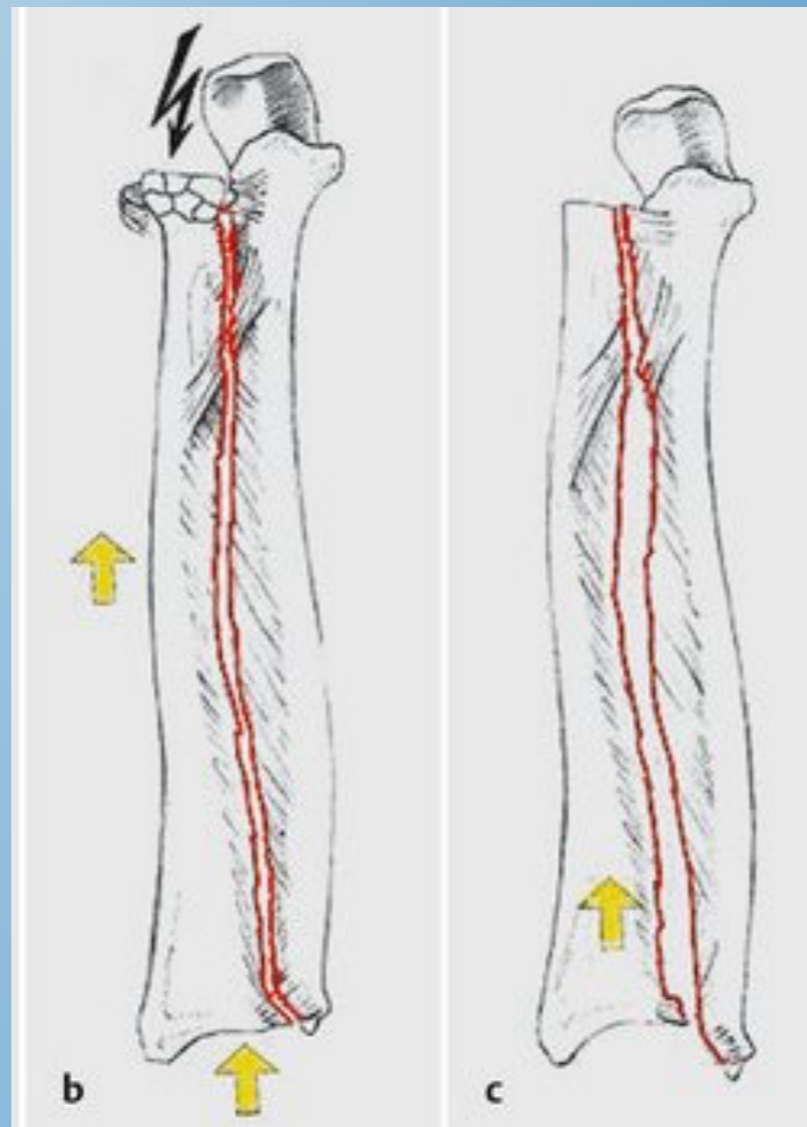
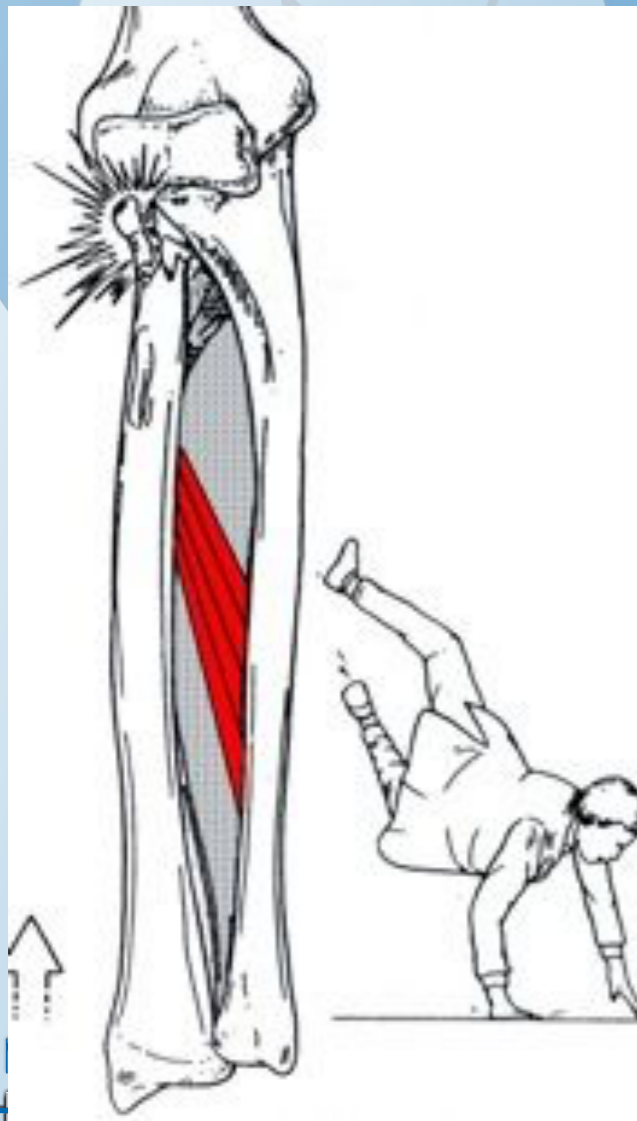
Bijna goed is bar slecht



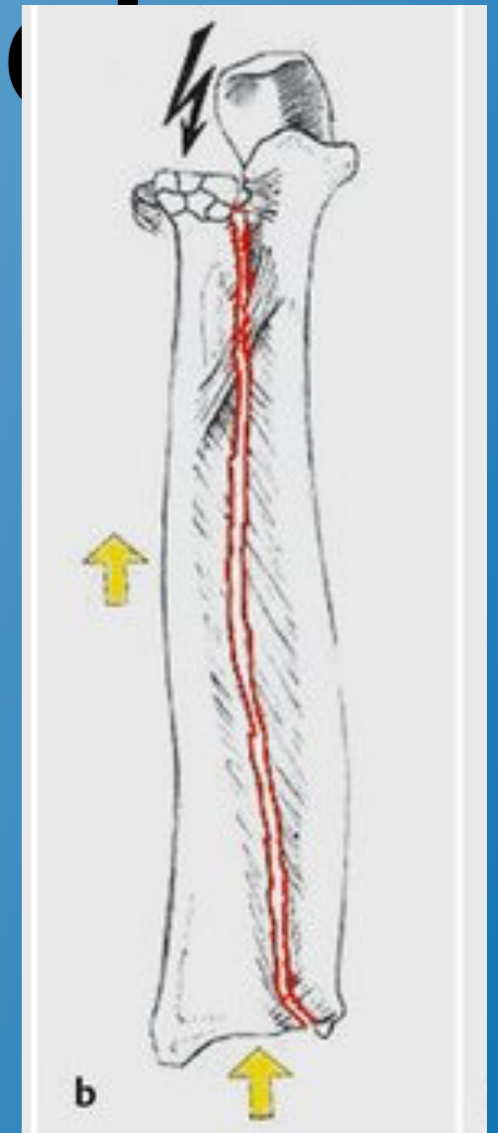
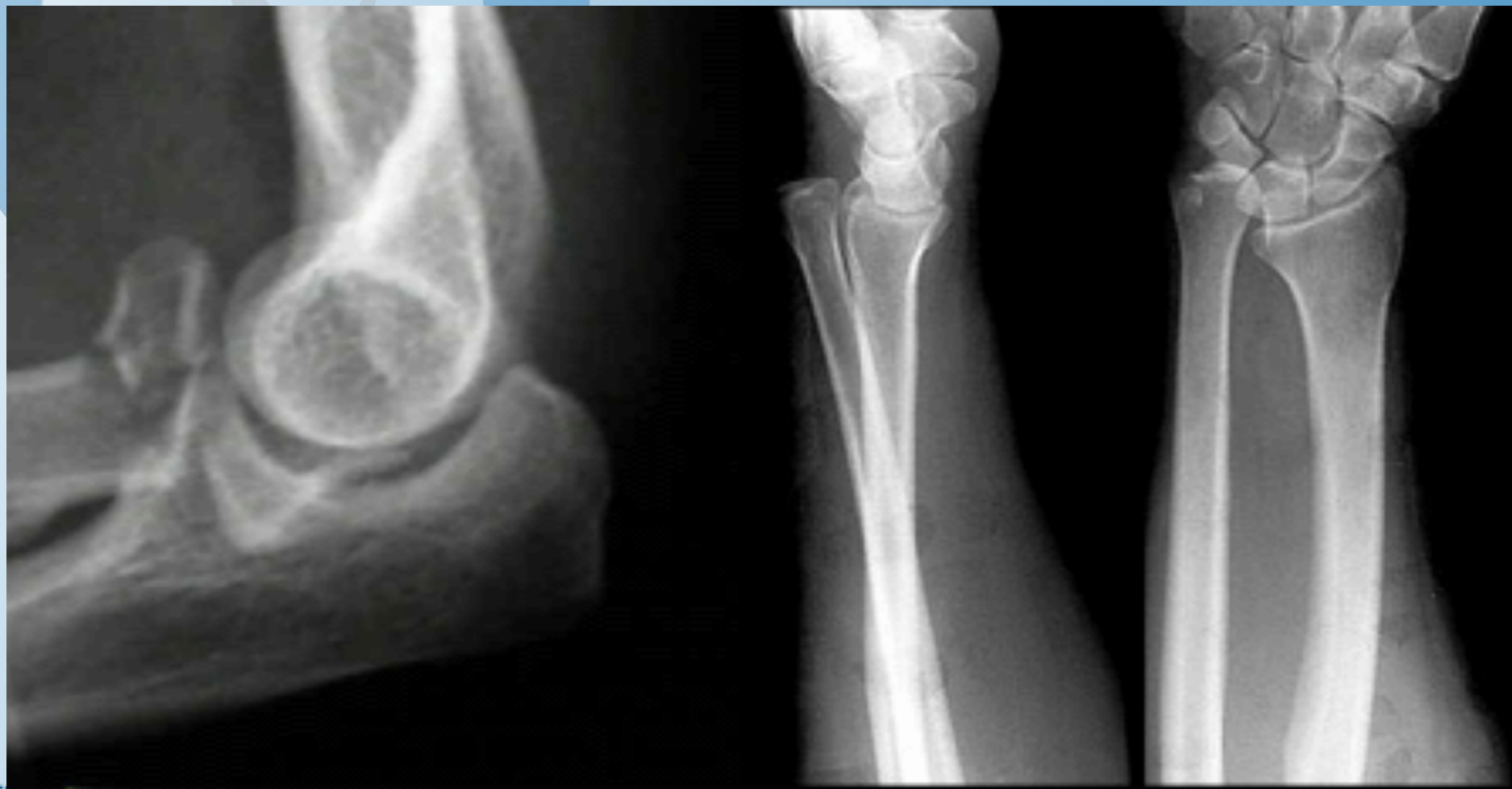Elleboogfracturen met instabiliteit:

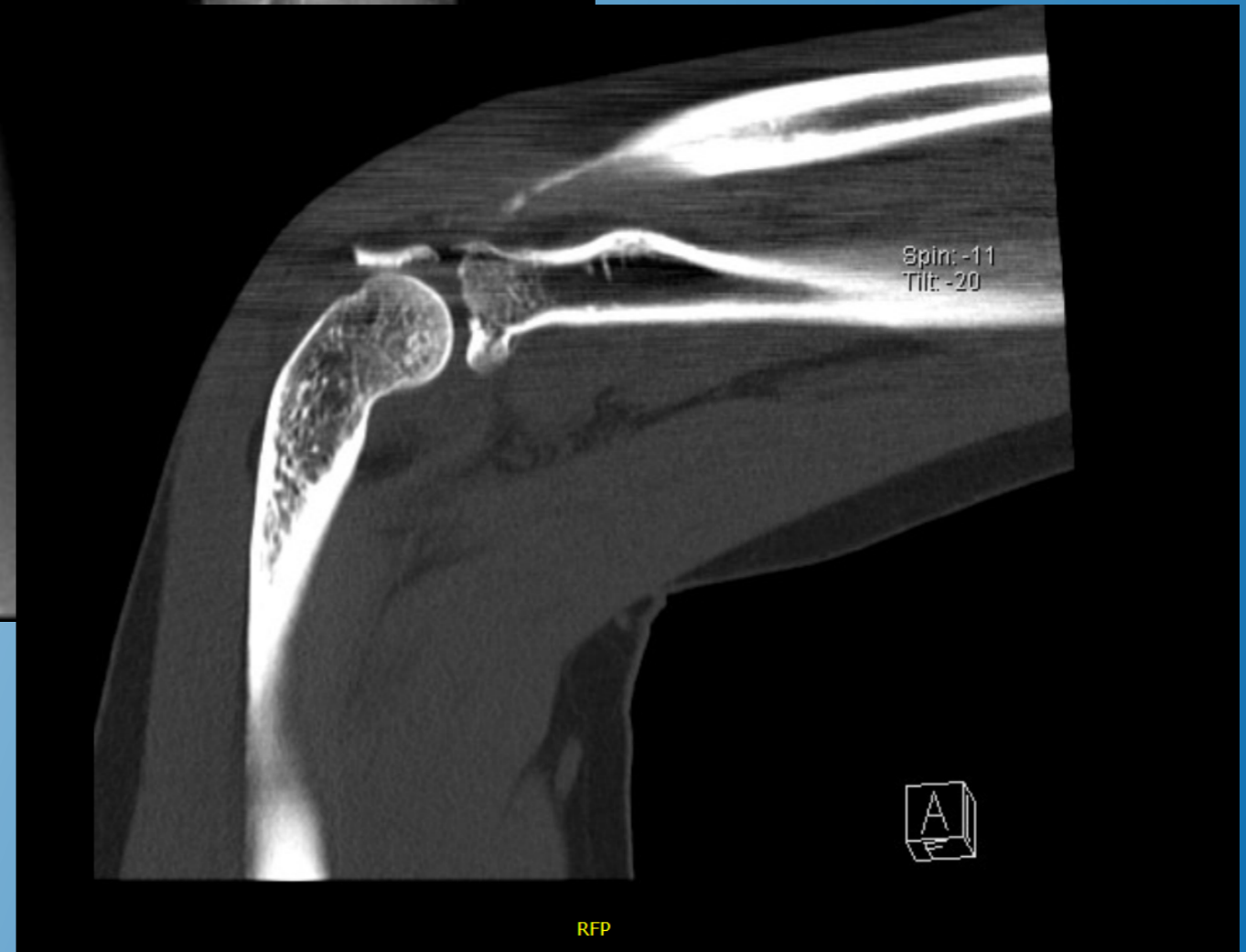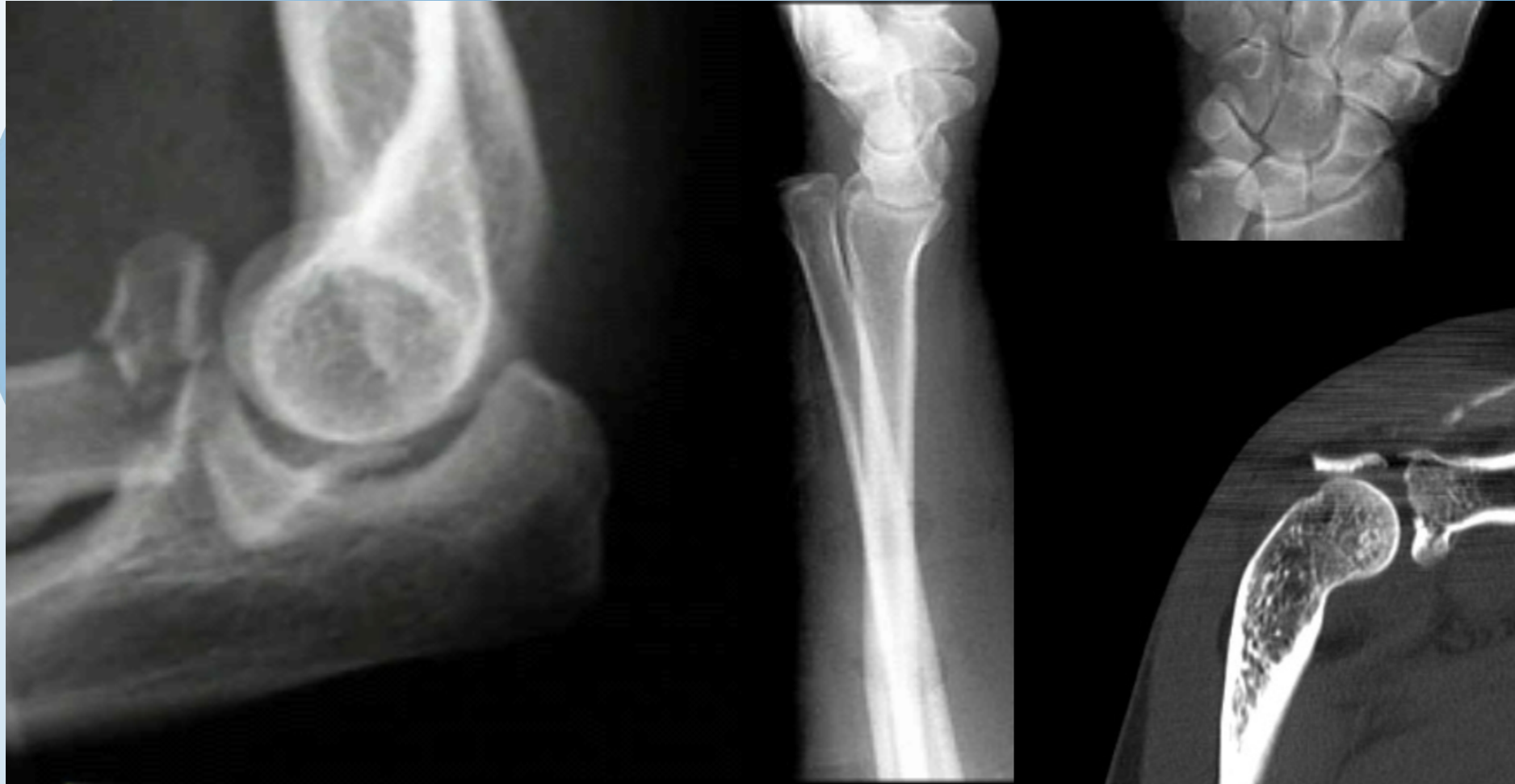- Terrible Triad
- Transolecranon Fractuur Luxaties,
Posterieure Monteggia letsels
- Essex-Lopresti letsels

Essex-Lopresti Letsel



Essex-Lopresti Letsso





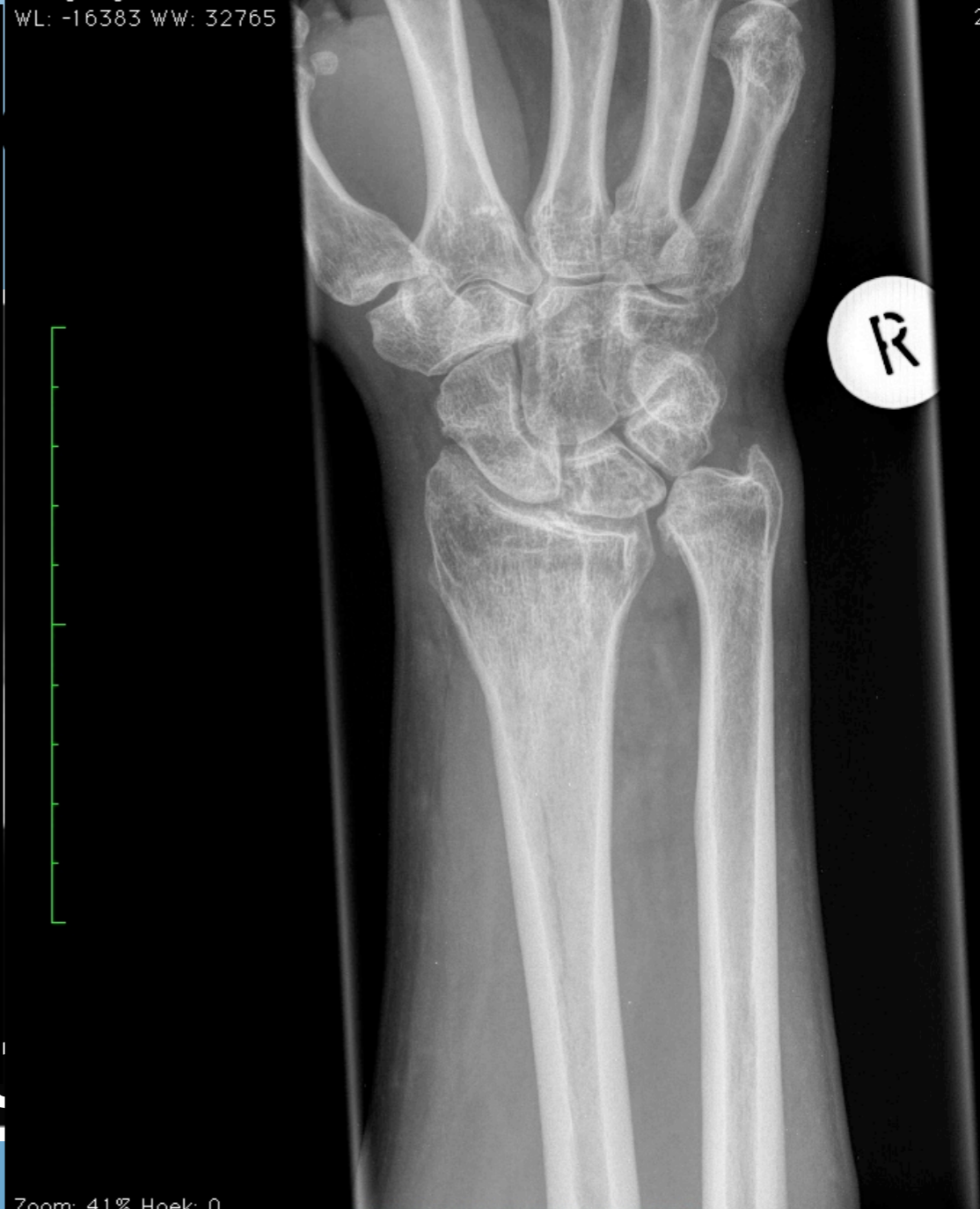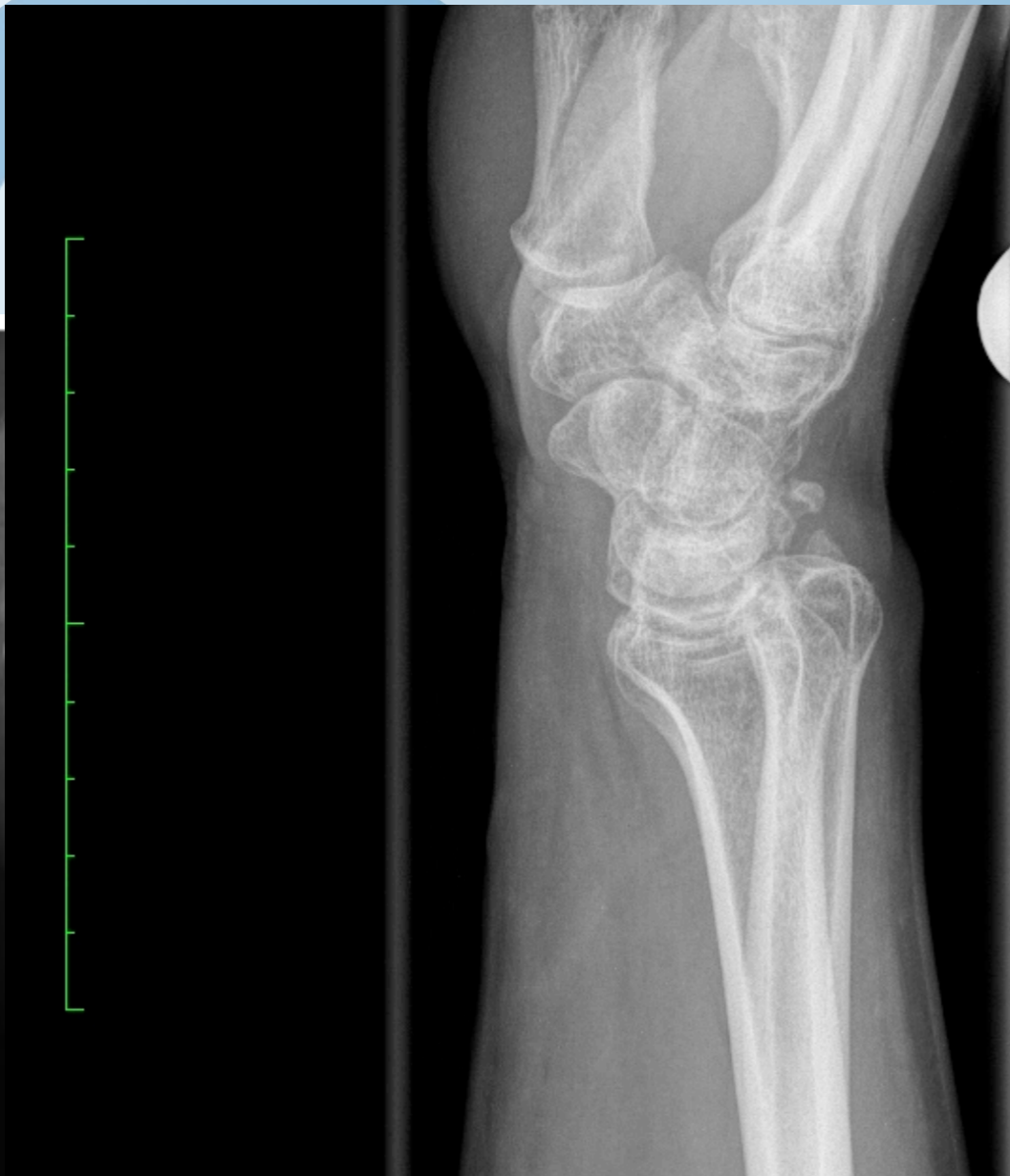Beeldgrootte: 1656 x 2280
Weergavegrootte: 681 x 938
WL: -16383 WW: 32765

VOILUT Applied

8209121154 (34 j, 33 j)

Rx Polis Rechts

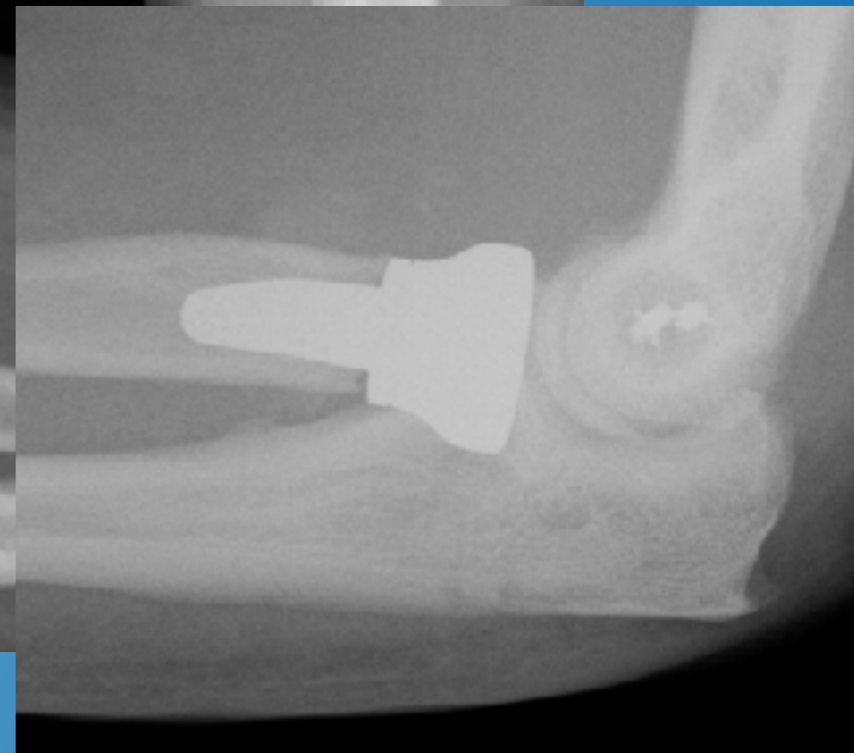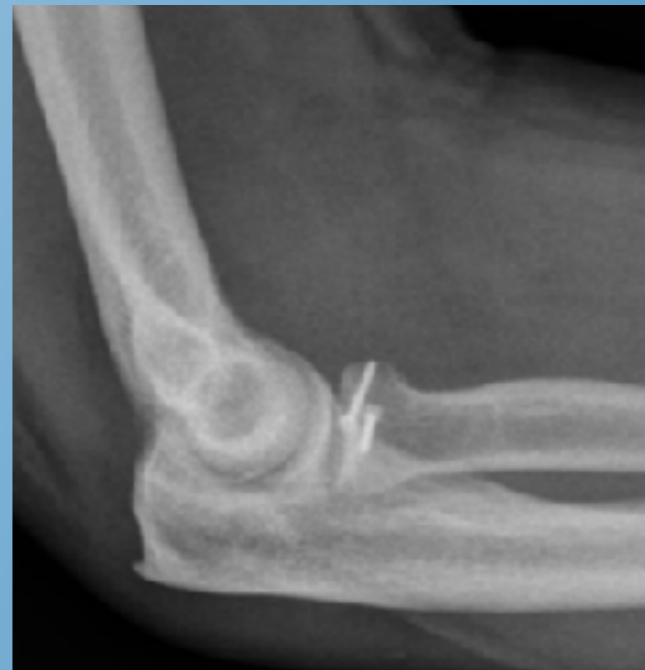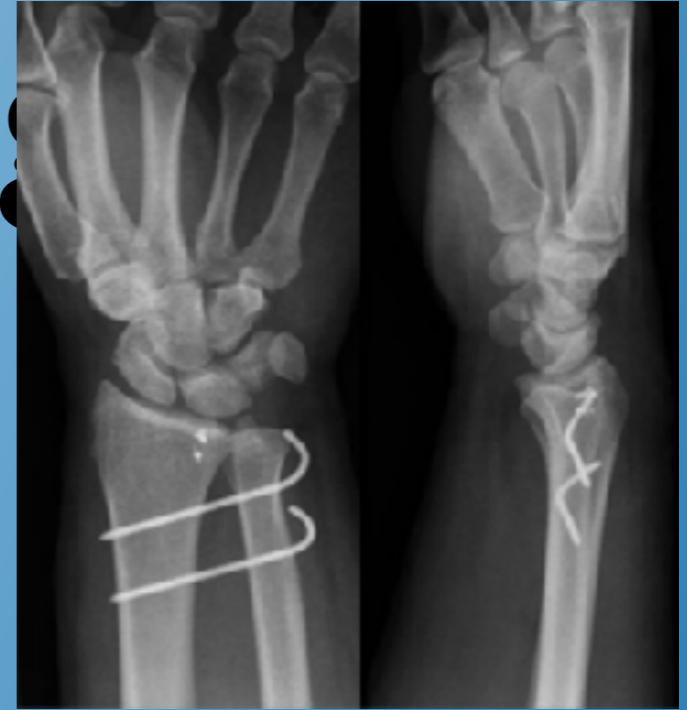2

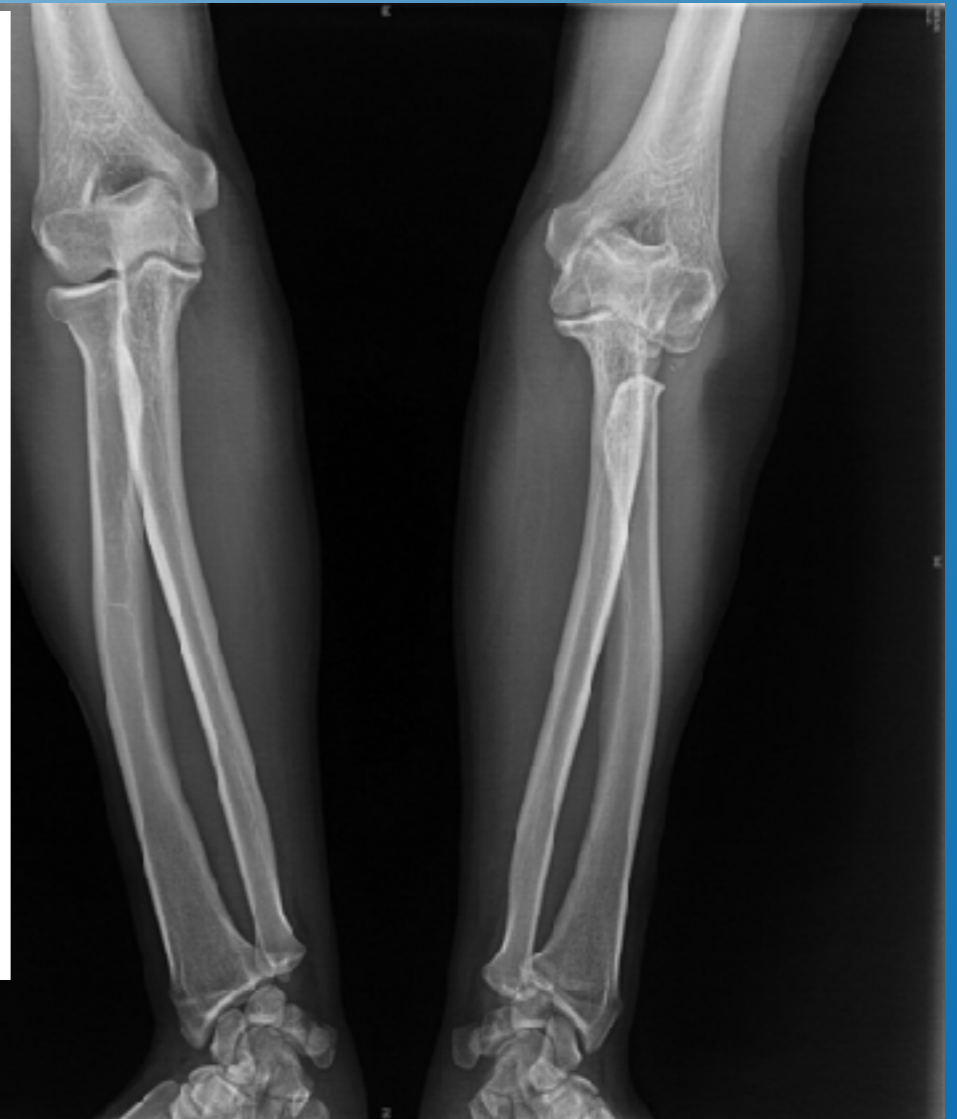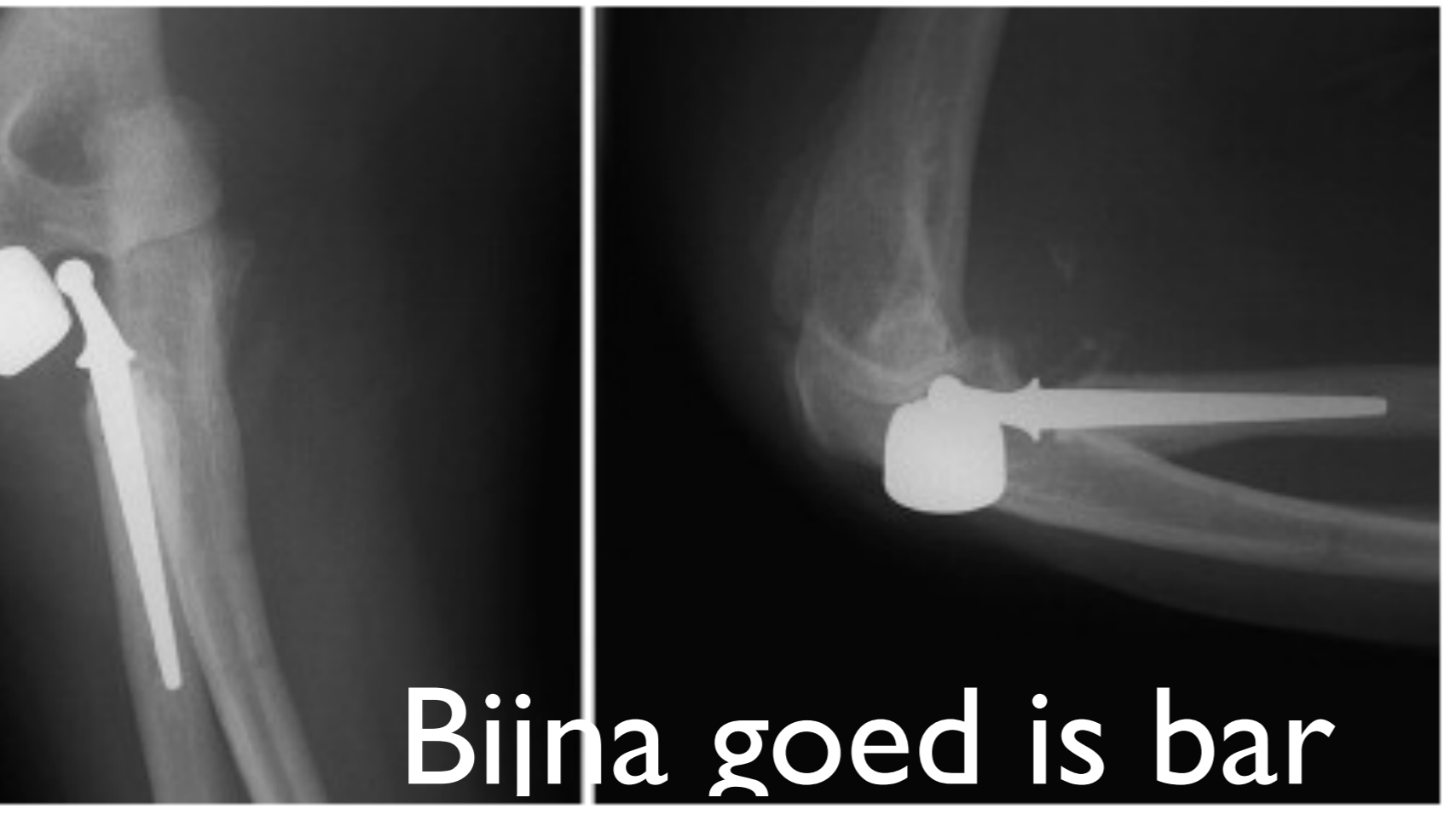


Zoom: 41% Hoek: 0

Behandeling

- Geen plaats voor radiuskopresectie of conservatieve behandeling
- radiuskopherstel of prothese en pinning ulna-radius, na reductie DRUJ





Slechte prognose in oudere studie, maar geen consistente behandeling

- alle 4 redislocaties van de 23 elleboog fractuurluxaties, waren terrible triad letsels
- ernstige arthrose bij 12 van 19 ellebogen @3 tot 34 jaar

Josefsson et al. CORR 1989

- 7 van 11 patienten slecht resultaat
- arthrose bij 9 van 10 patienten @7 jaar

Ring et al. JBJS-Am, 2002



Huidige behandelingsprotocollen (na 2004), betere resultaten, maar..

bewegingsarcus 110° ,

Rotatie 30° ,

Mayo score 85

news
... lange termijn
niet gekend.

geen
redislocaties
Milde arthrose
@ 2,5jaar

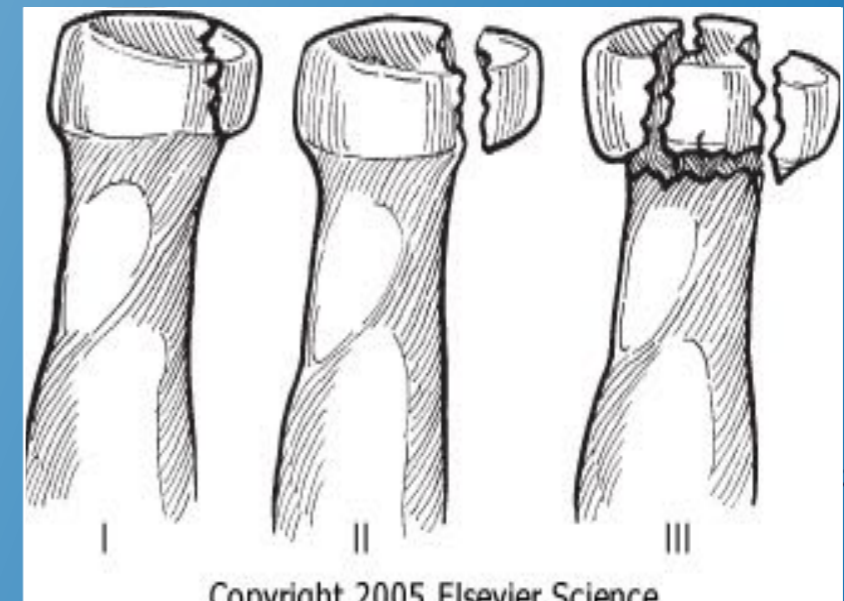
Pugh et al., JBJS (A) 2004, Egol et al, Bull NYU Hosp Jt Dis.2007,
Forthman et al.,

JHS(A) 2008, Lindenhovius et al, JHS(A) 2008, Zeiders et al., JBJS
2008



Take Home

- Instabiliteit is niet steeds duidelijk: wees op uw hoede!
- Denk aan de pols!!
- Steeds operatieve behandeling: challenging!
 - Elk deel van complex geheel aanpakken
 - Bijna goed is bar slecht
- Doel: snelle, stabiele mobilisatie



Copyright 2005 Elsevier Science

Je le pansai, Dieu le guérit.

Bijna goed is bar slecht!



Figure 1:
Reduction of an elbow fracture dislocation in Paris, France 1564 by Dr. Ambroise Pare (1510 – 1590)





**Bedankt!
Vragen?**