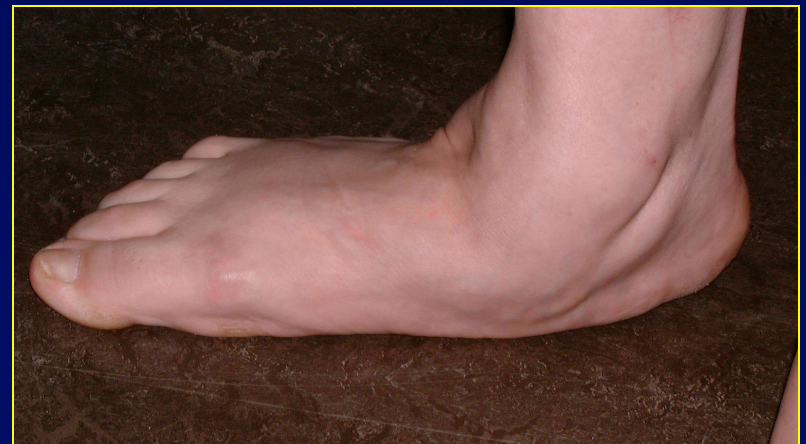
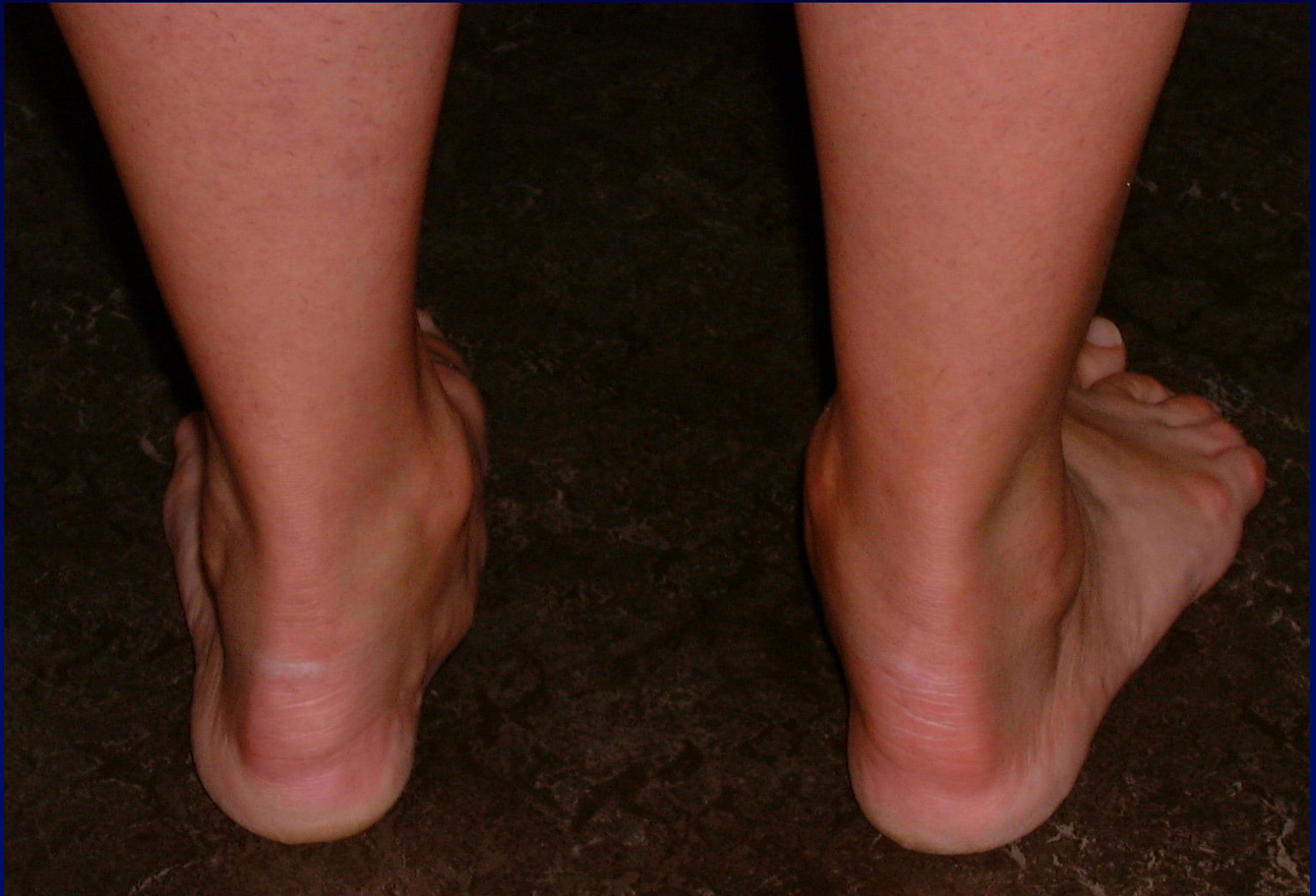
# Tibialis posterior pees insufficiëntie

Dr. Geoffroy Vandeputte  
Hand en voetchirurgie  
Lier

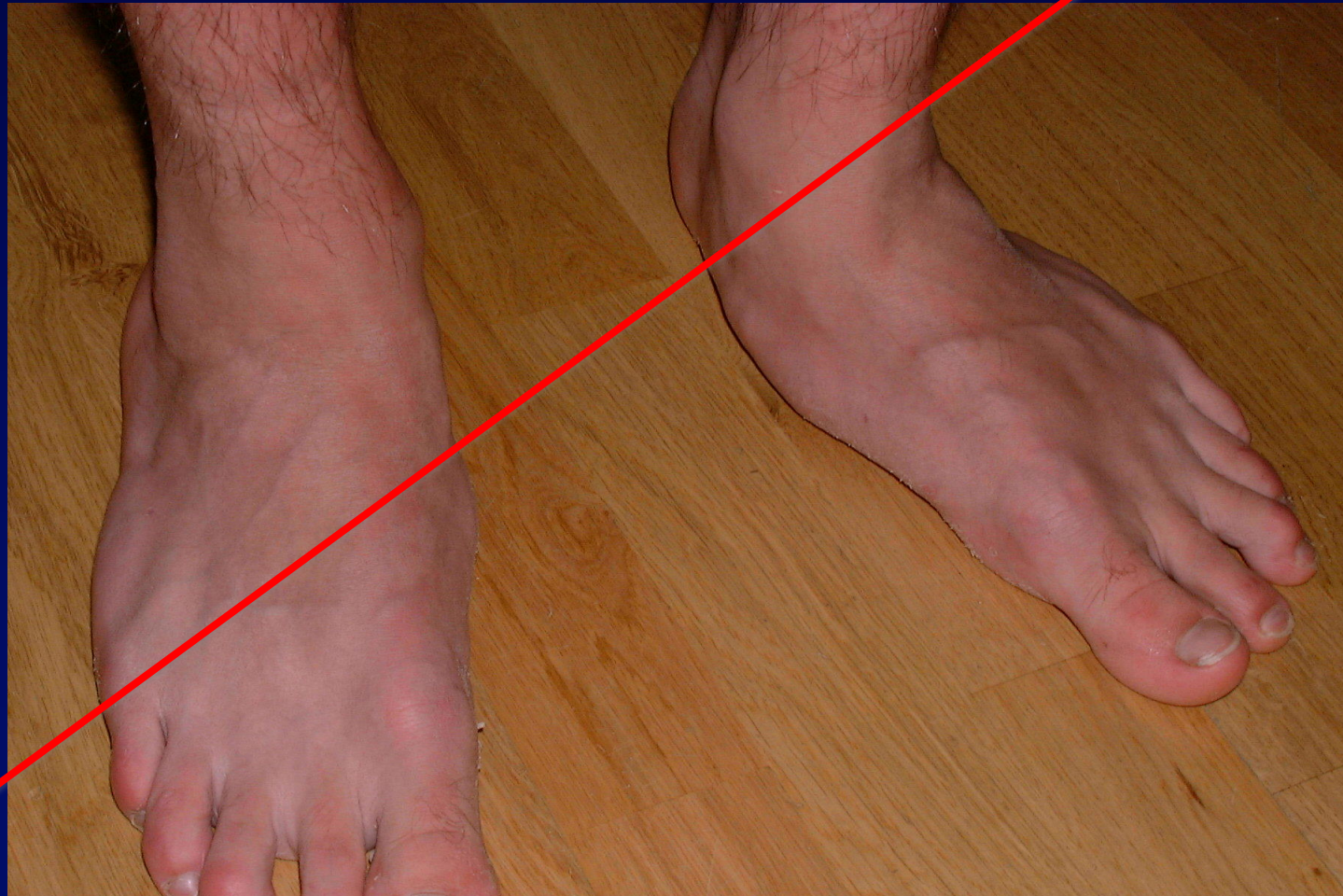

# Verworven platvoet



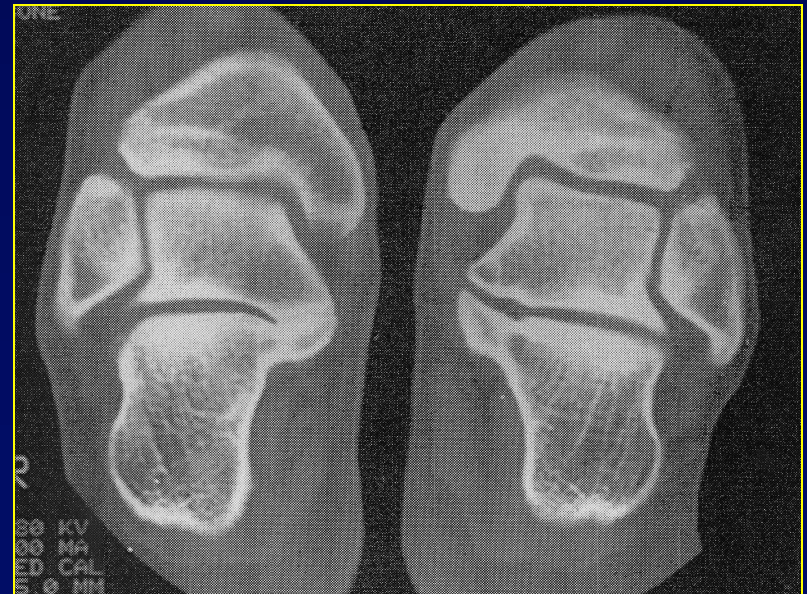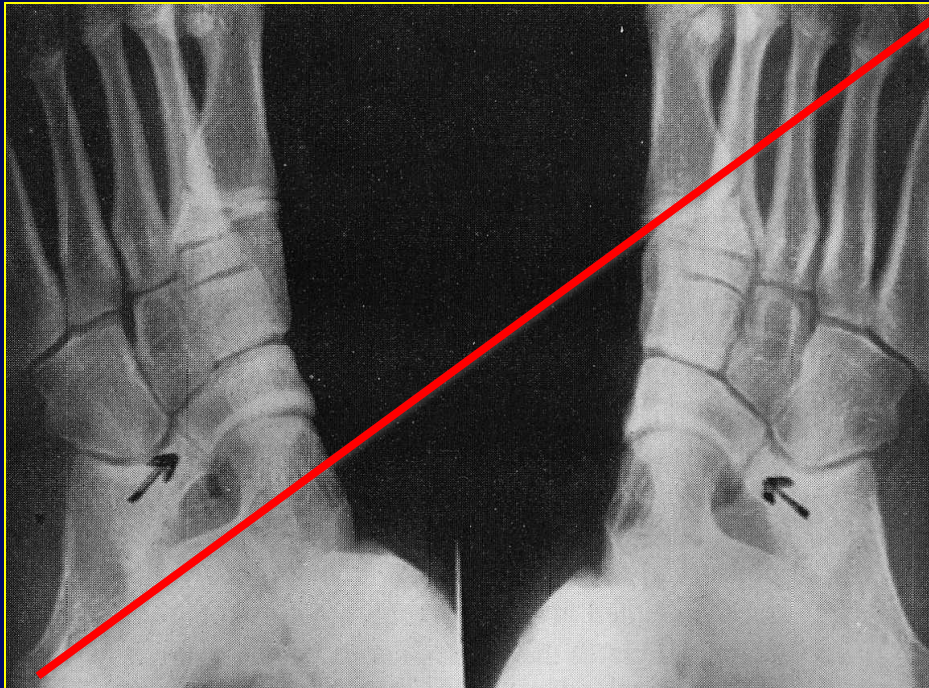


# Congenitale soepele platvoet

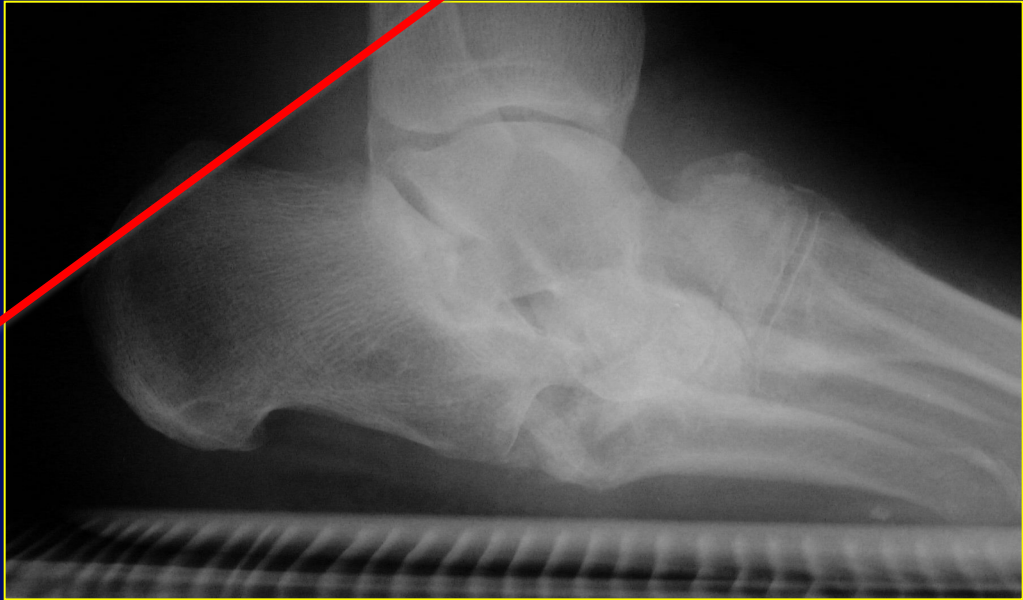




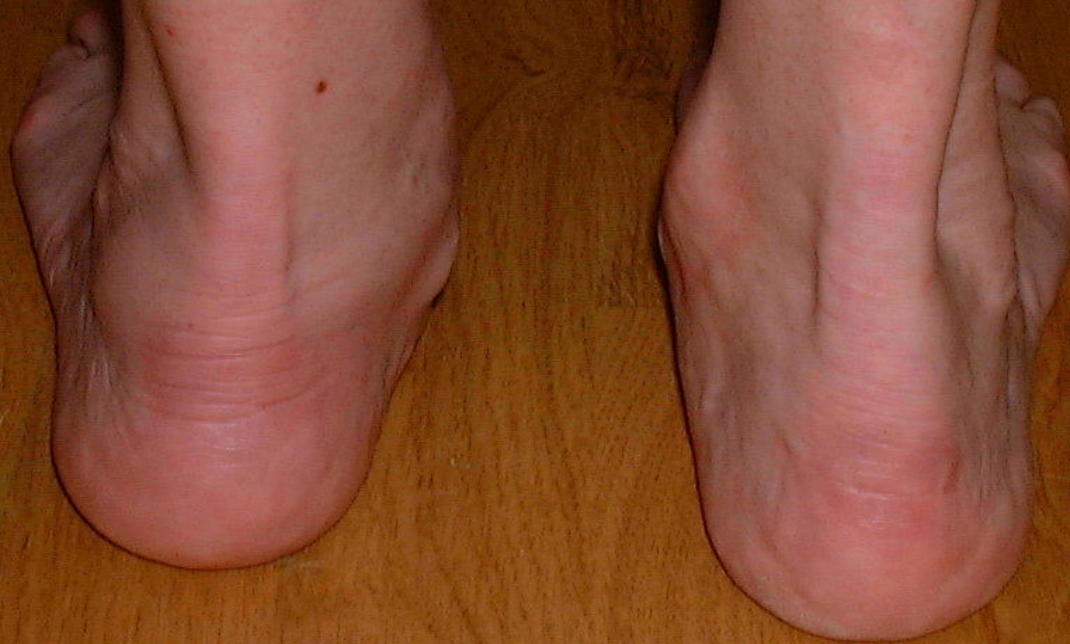# Congenitale rigiede platvoet



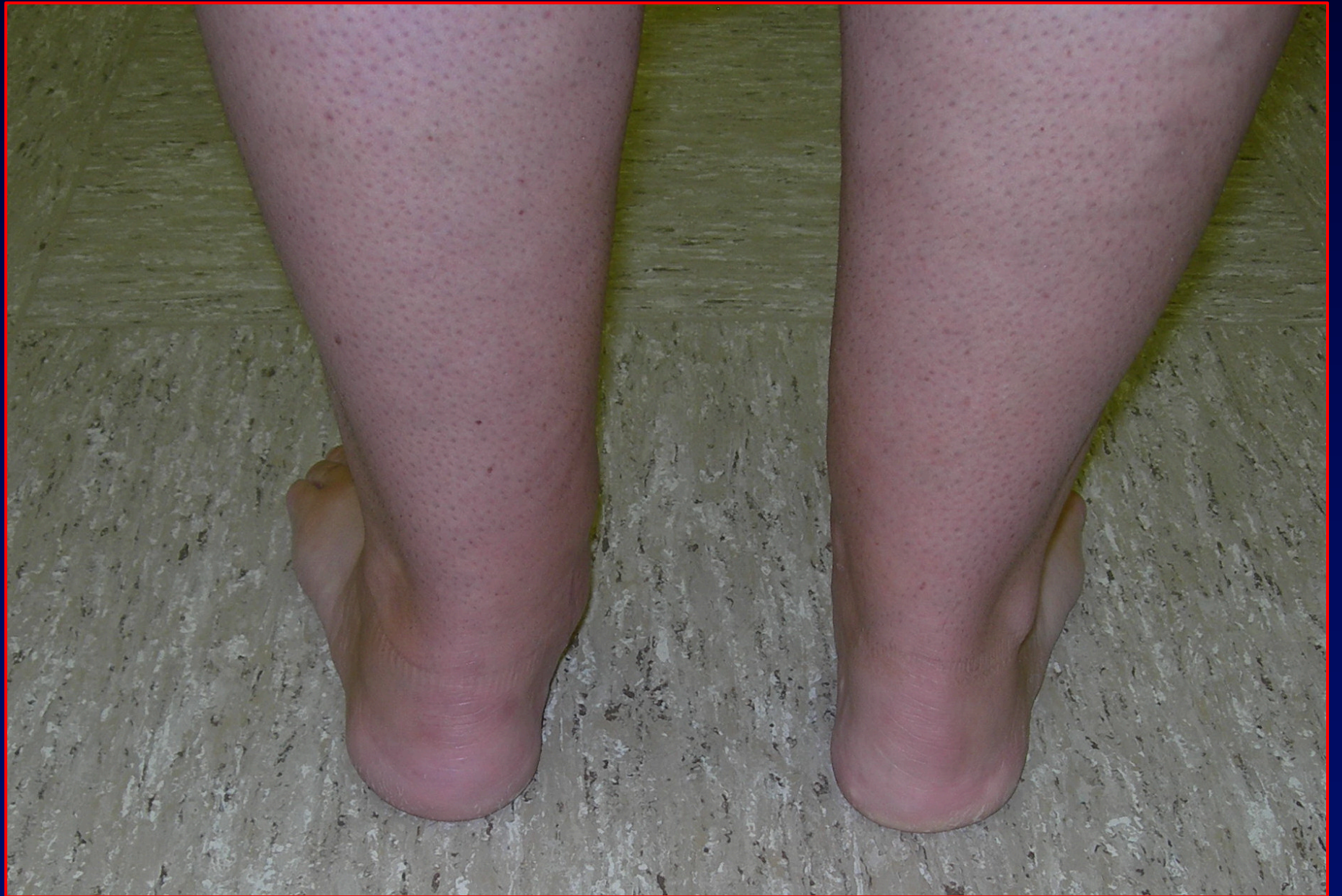



Verworven platvoet



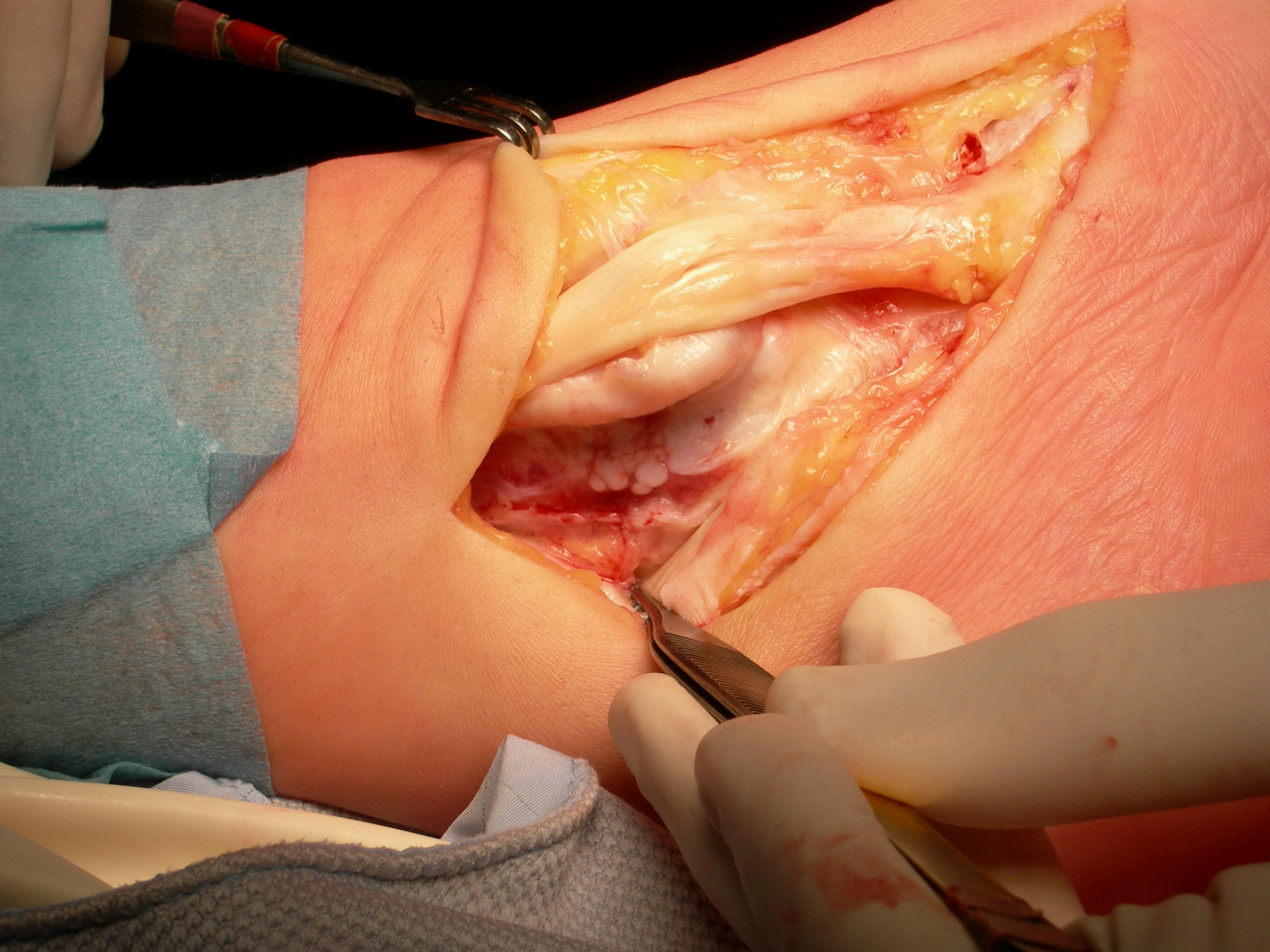



Oorzaak ??

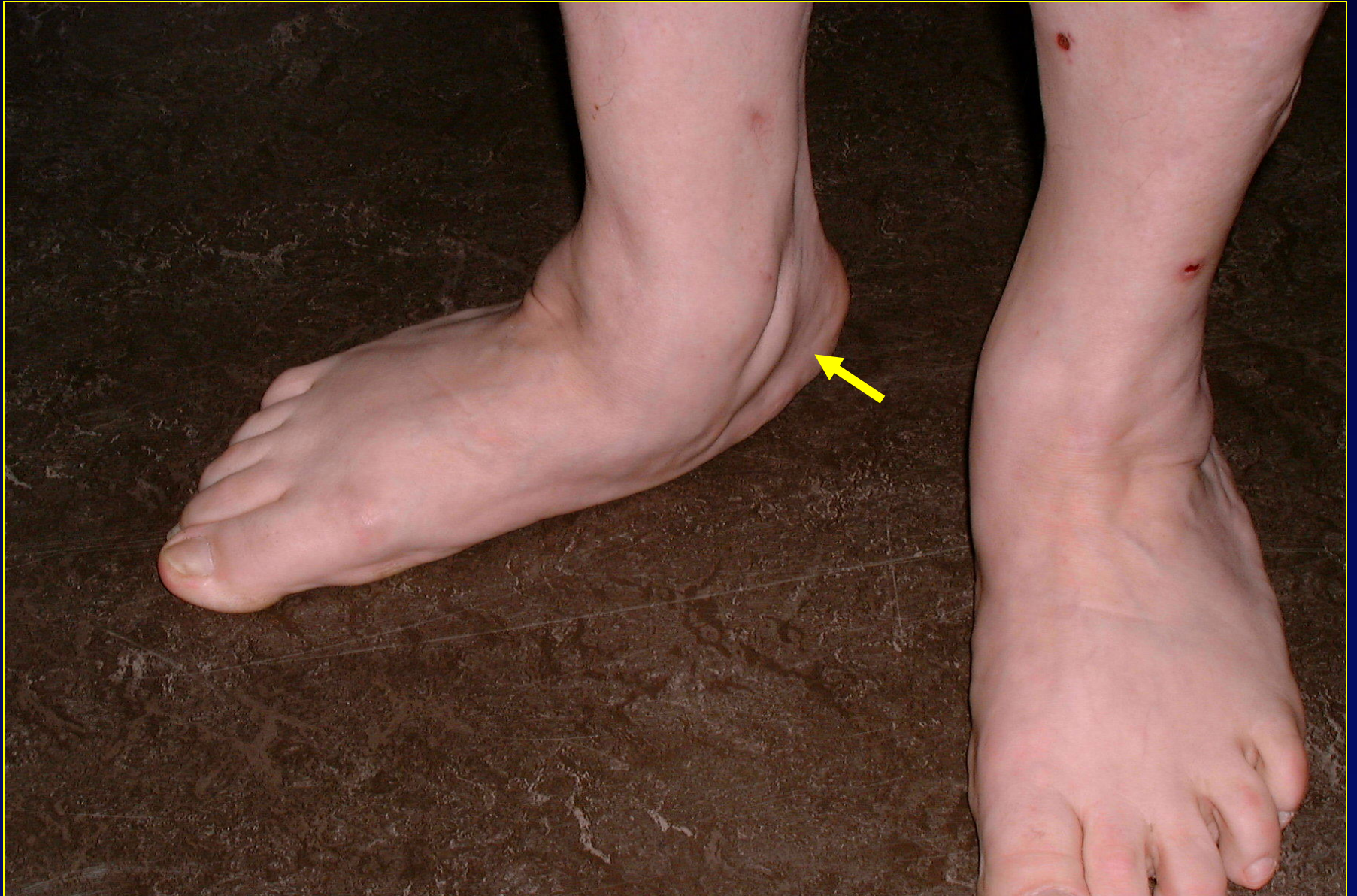

Stage 1

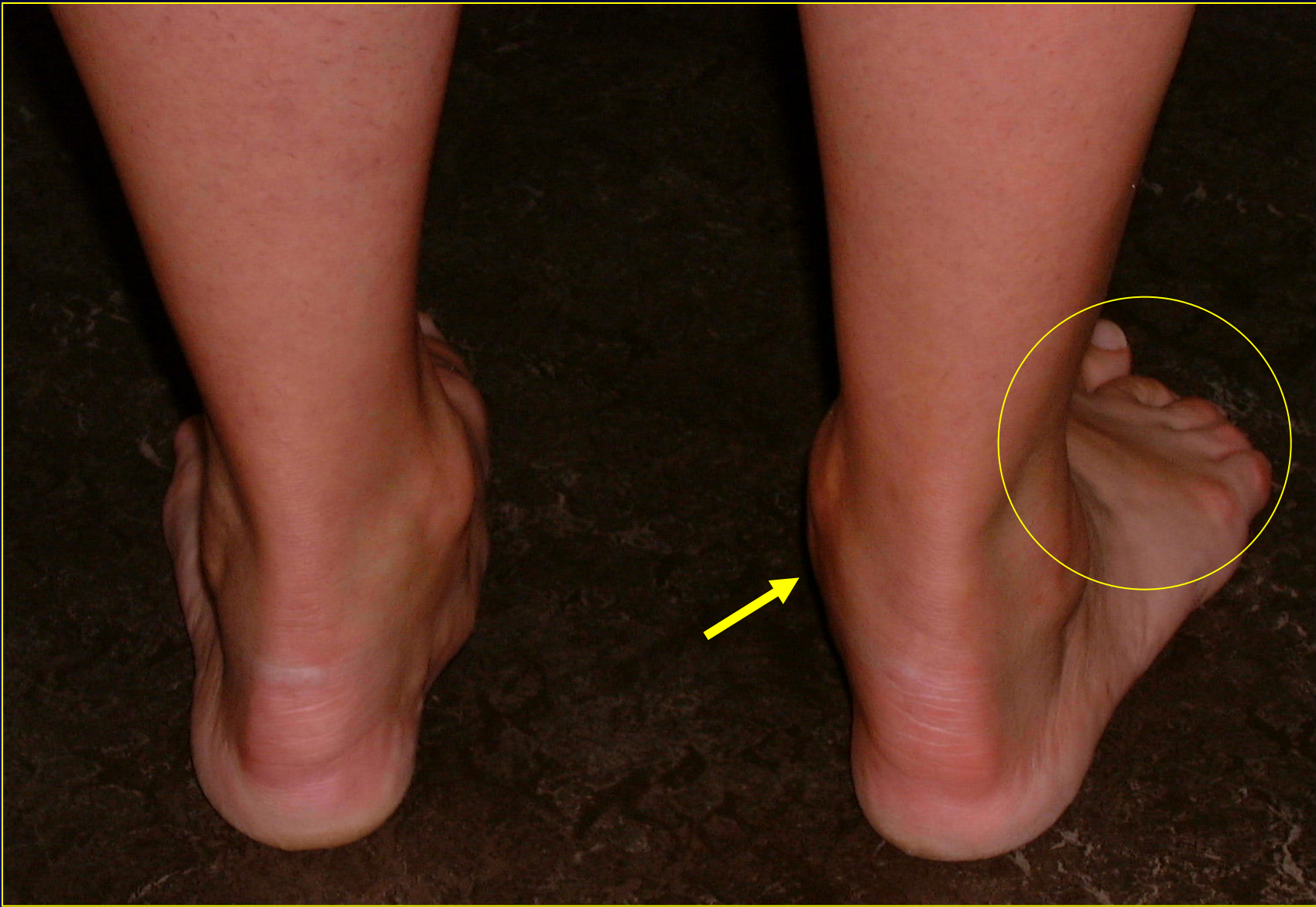




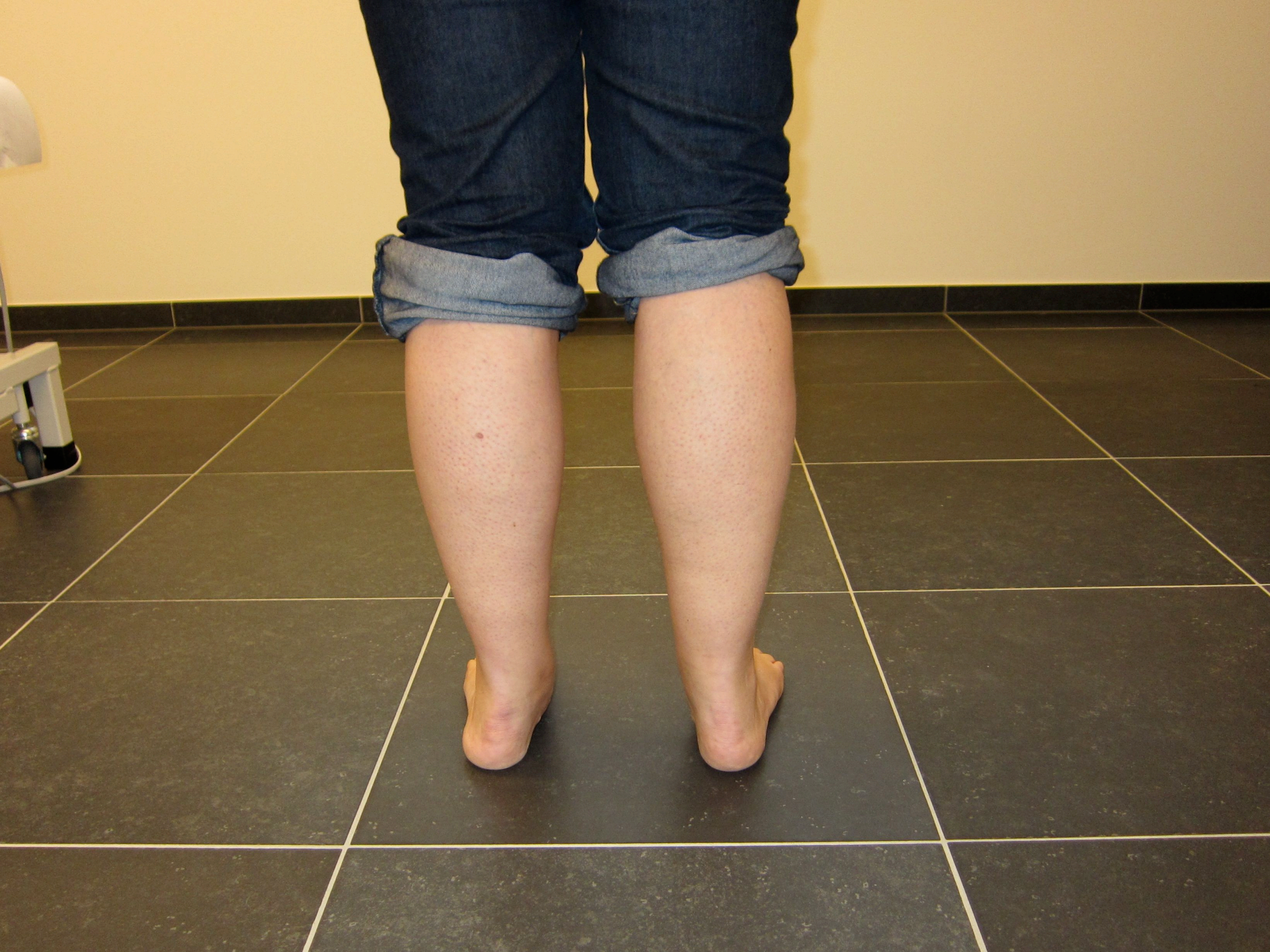## Stage 2







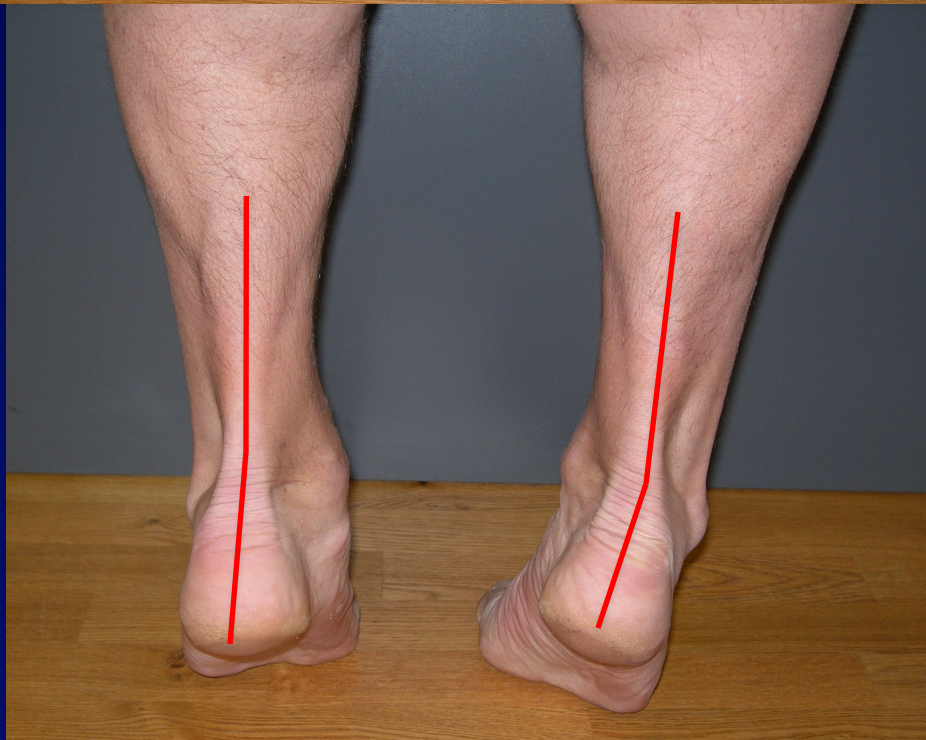
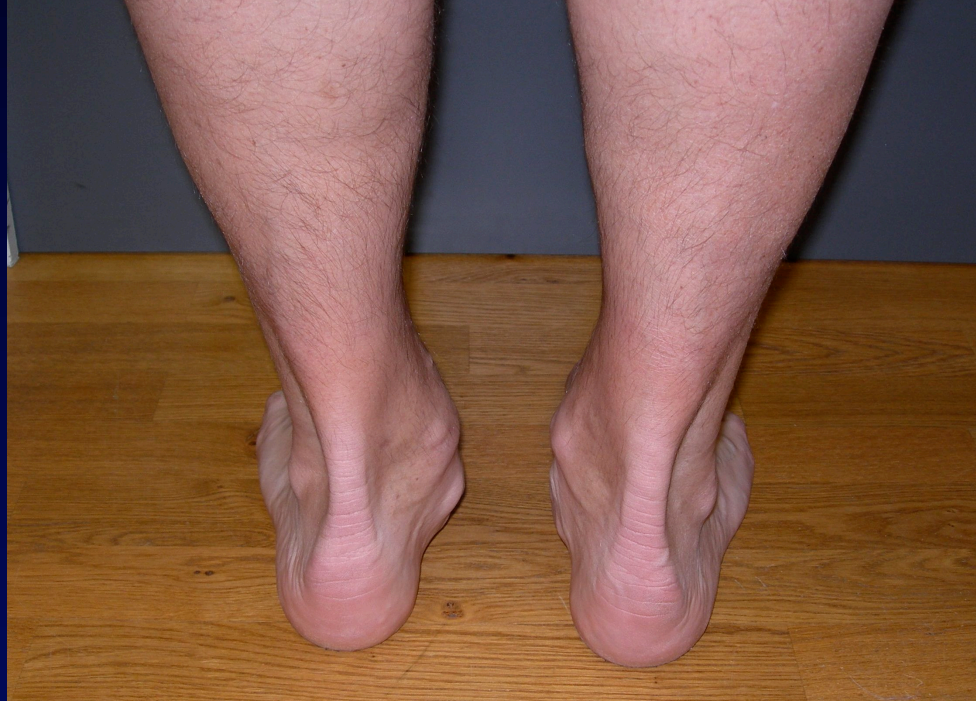



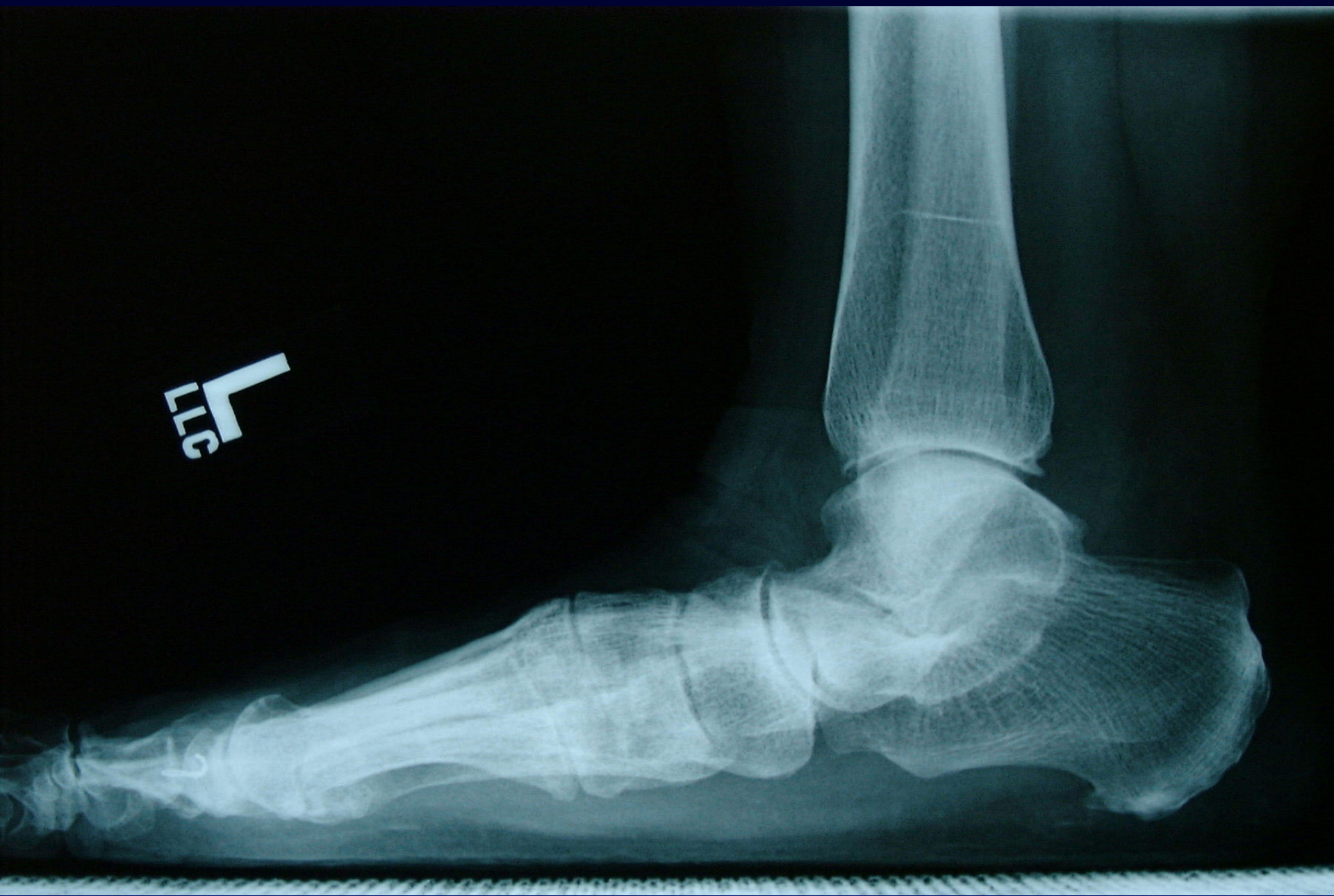


# Heel rise test



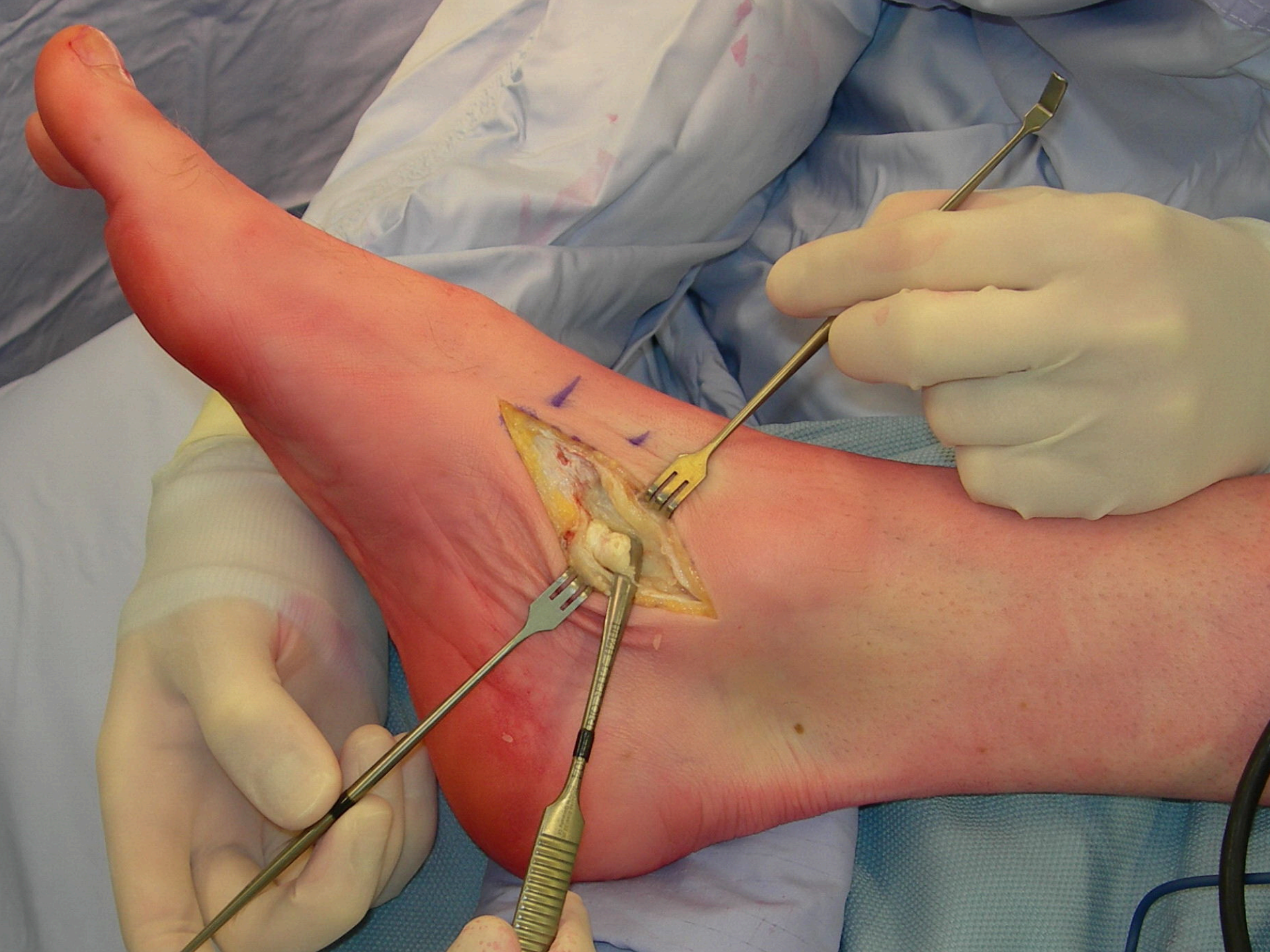




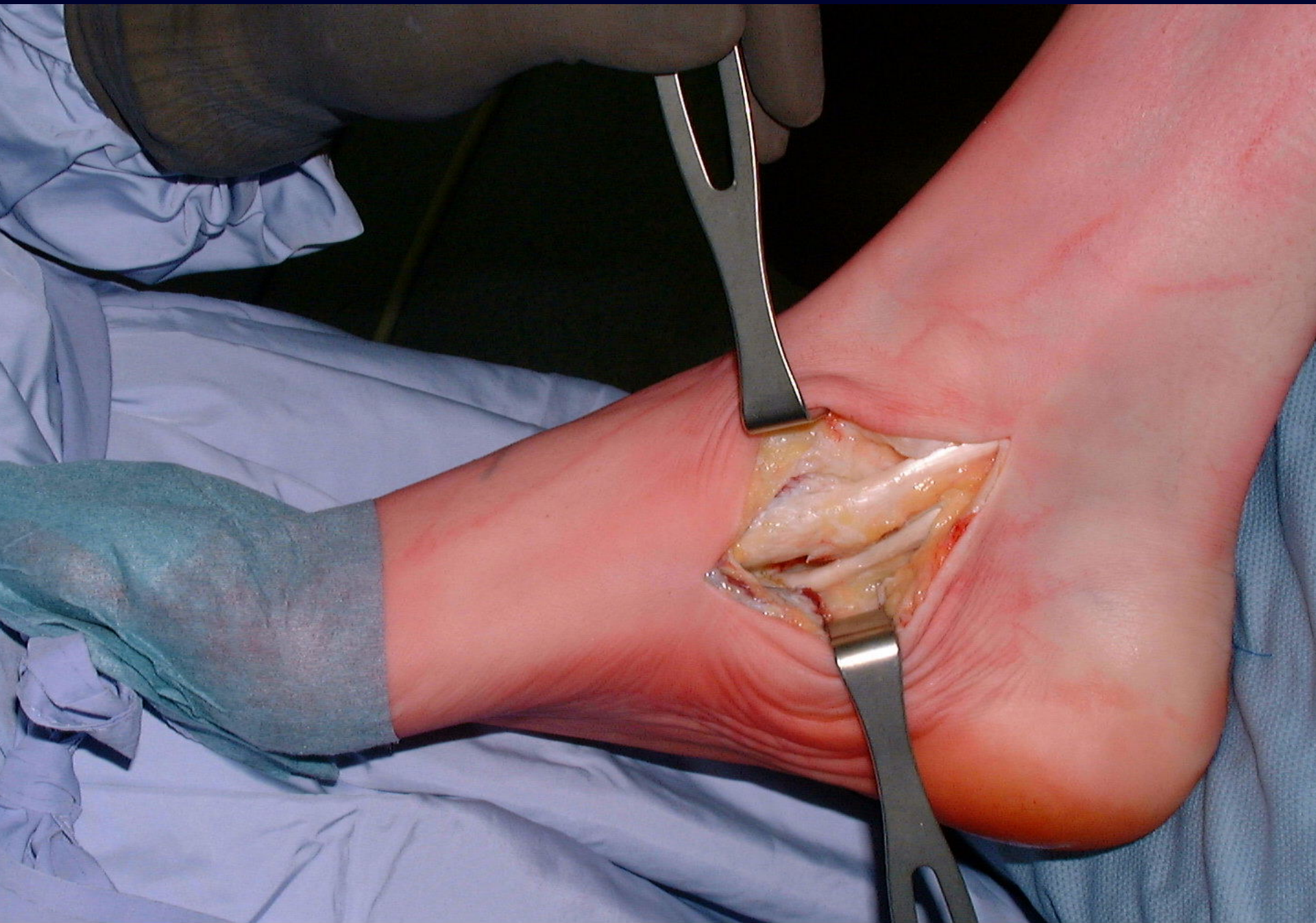

LTC

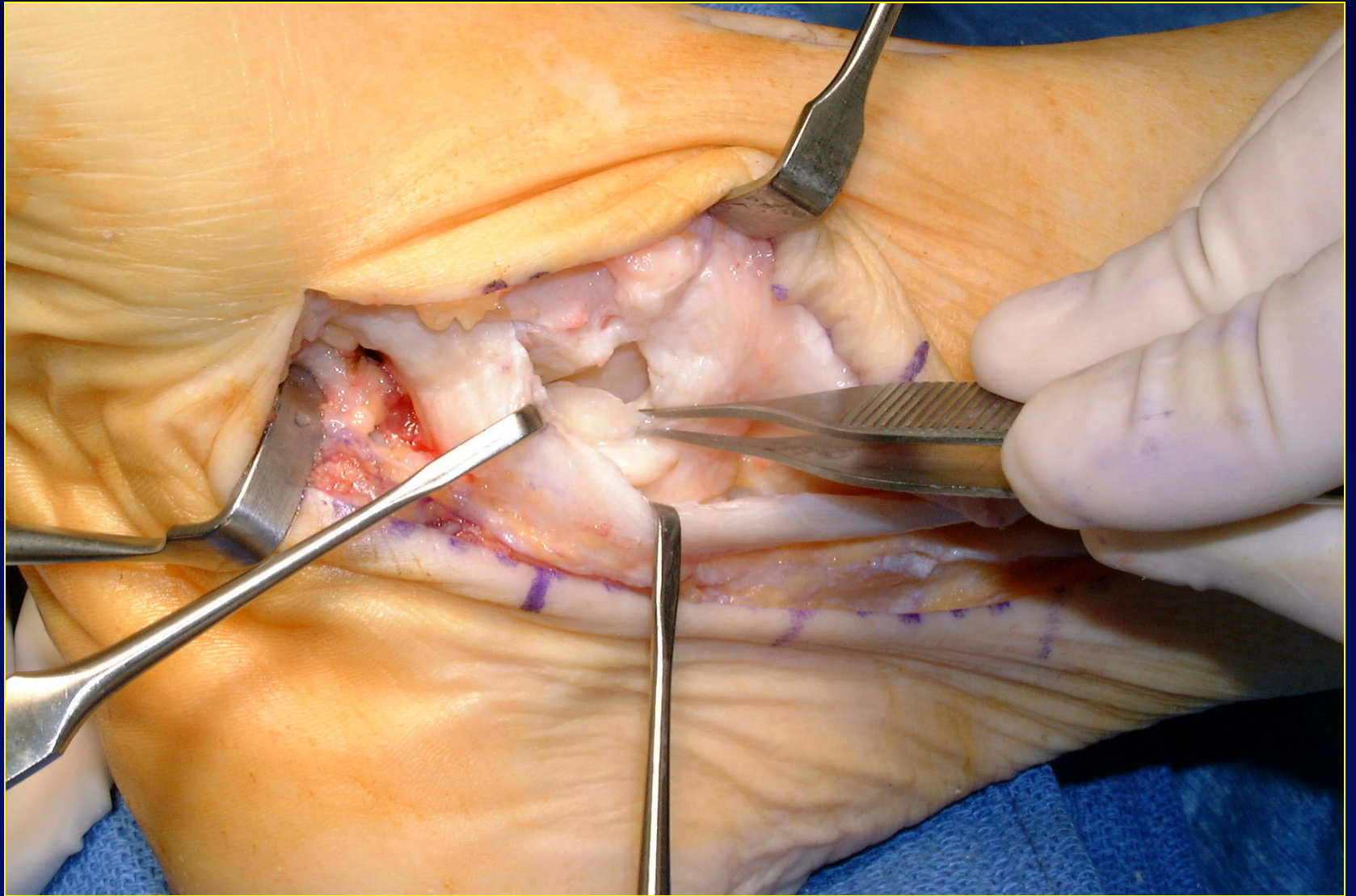




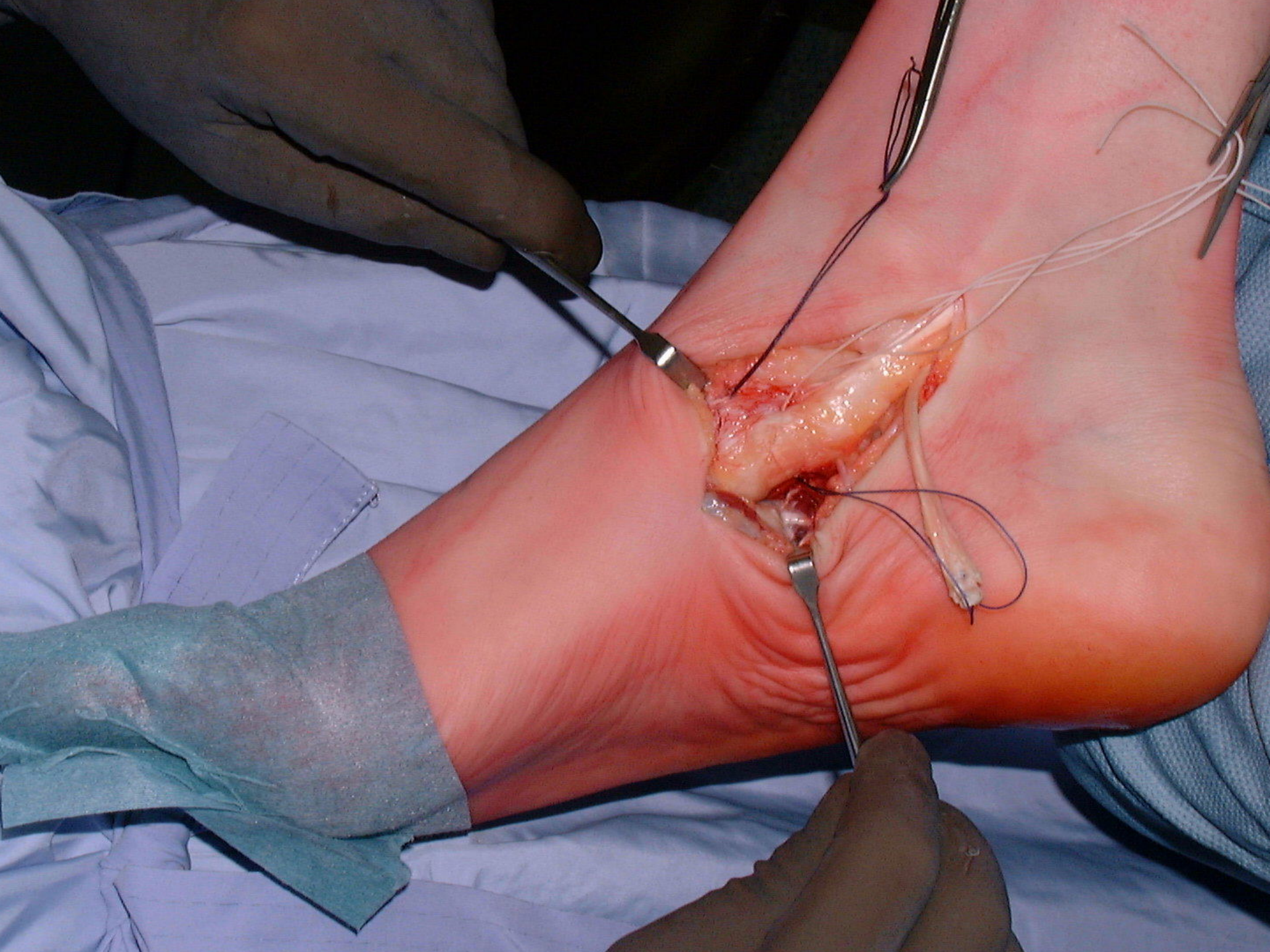




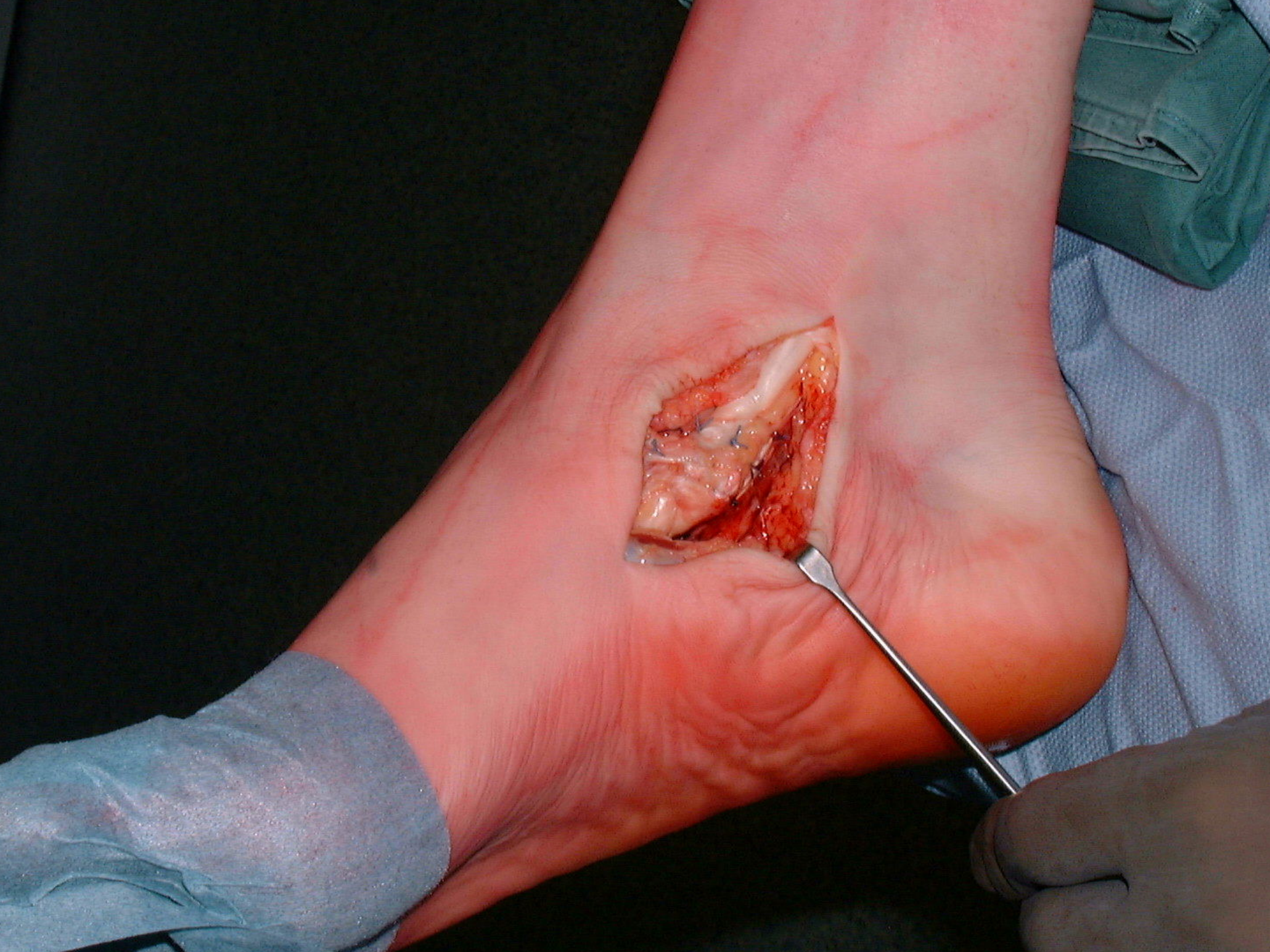




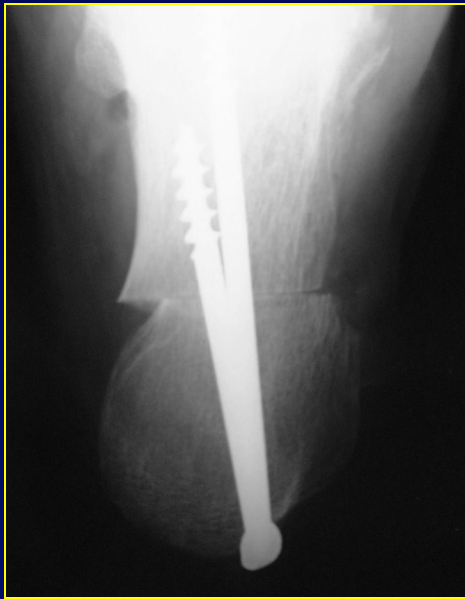
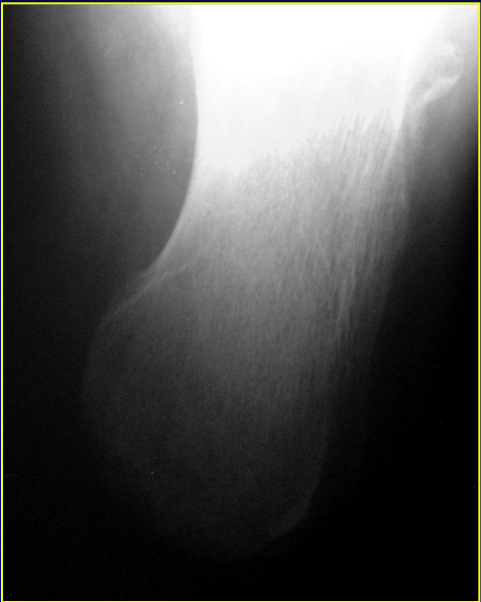
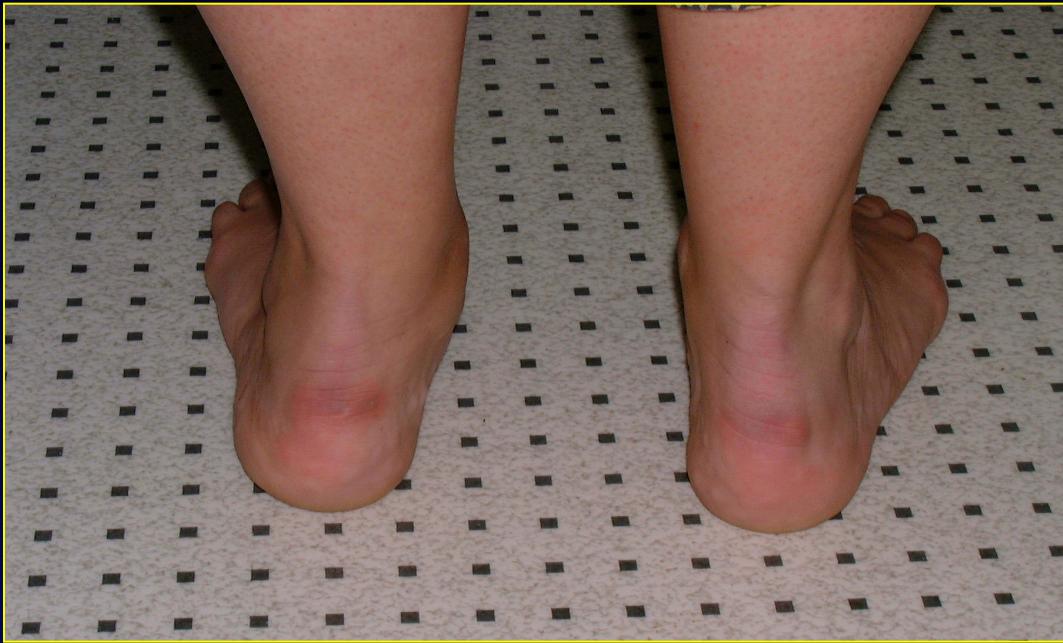


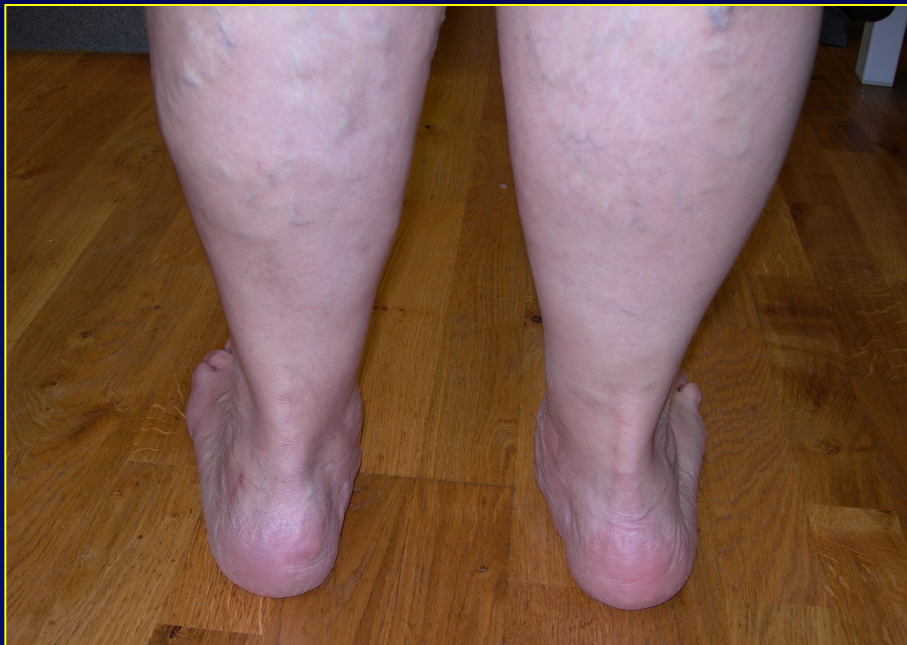
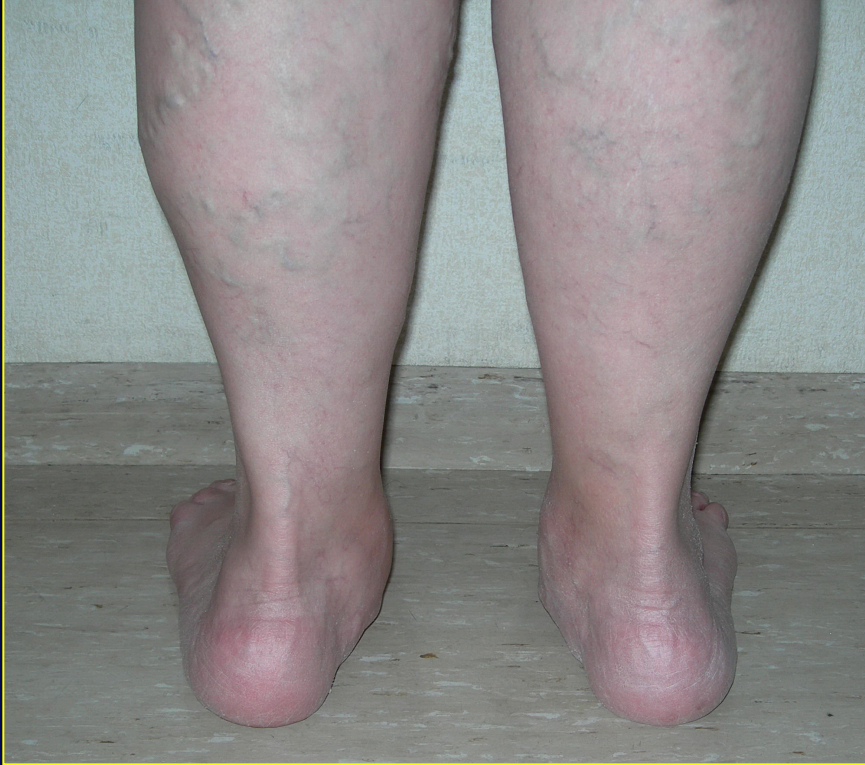


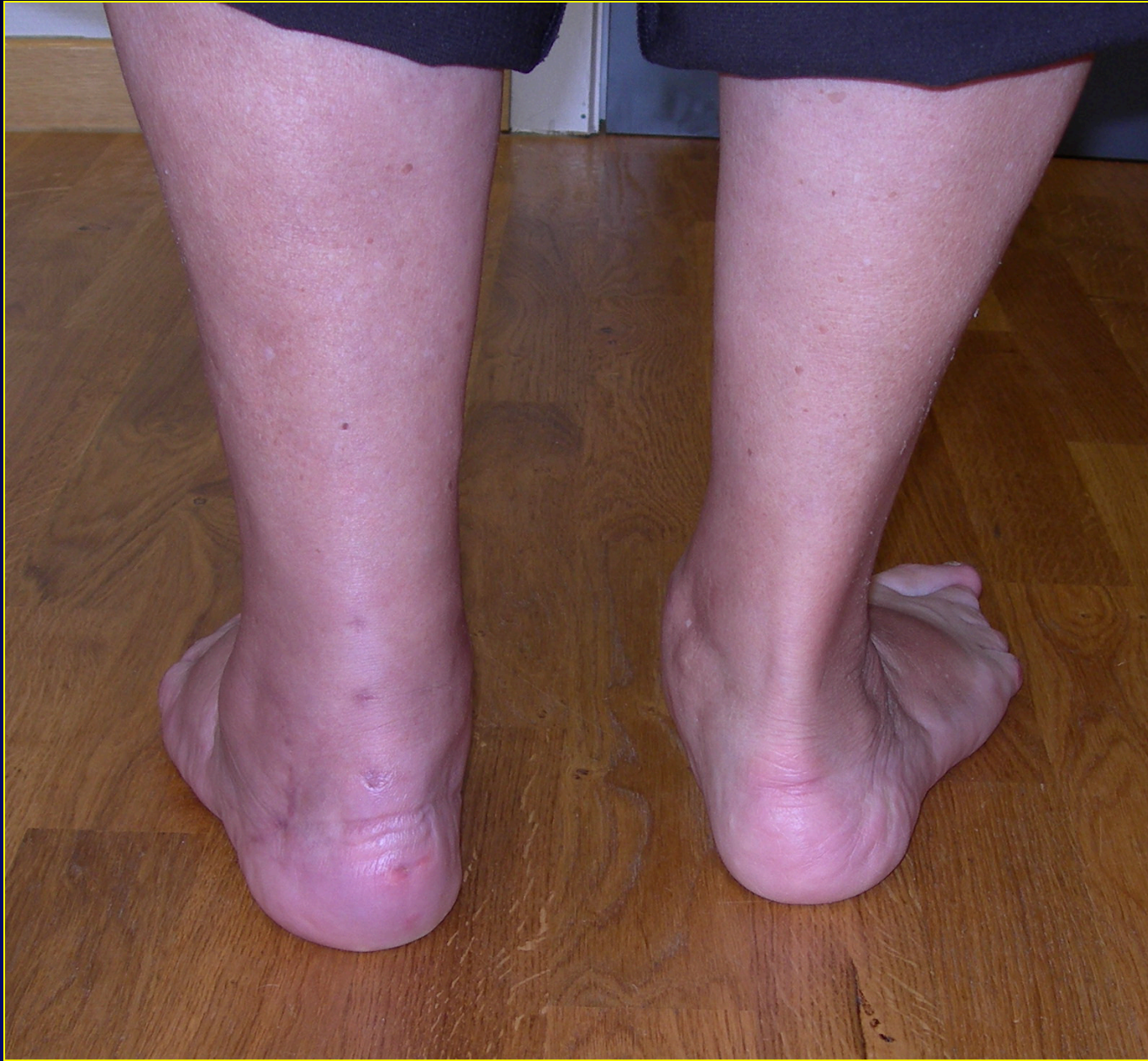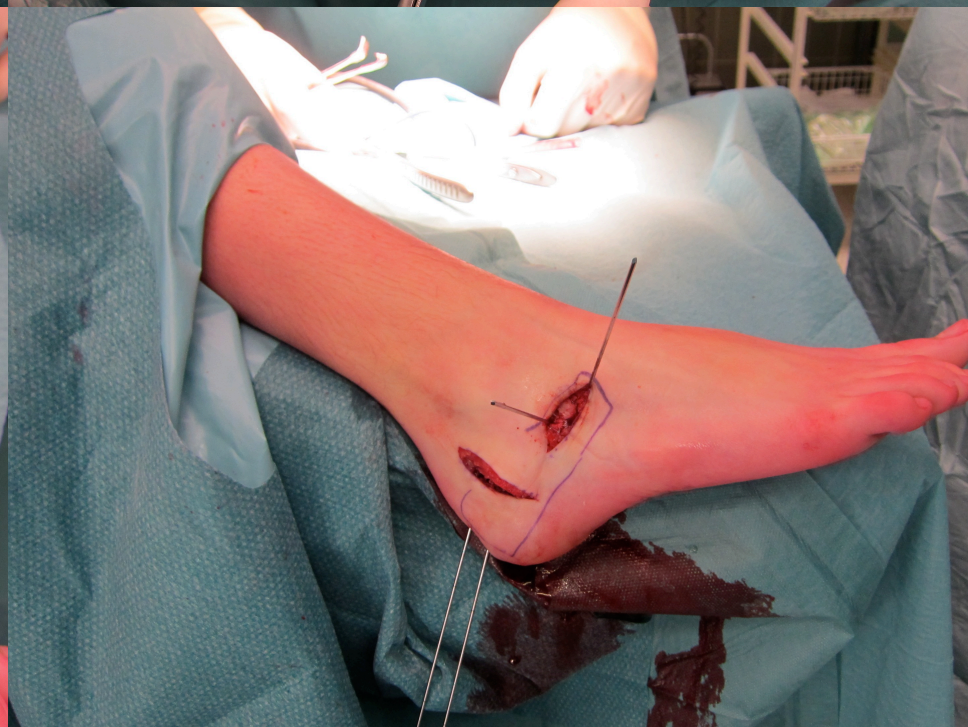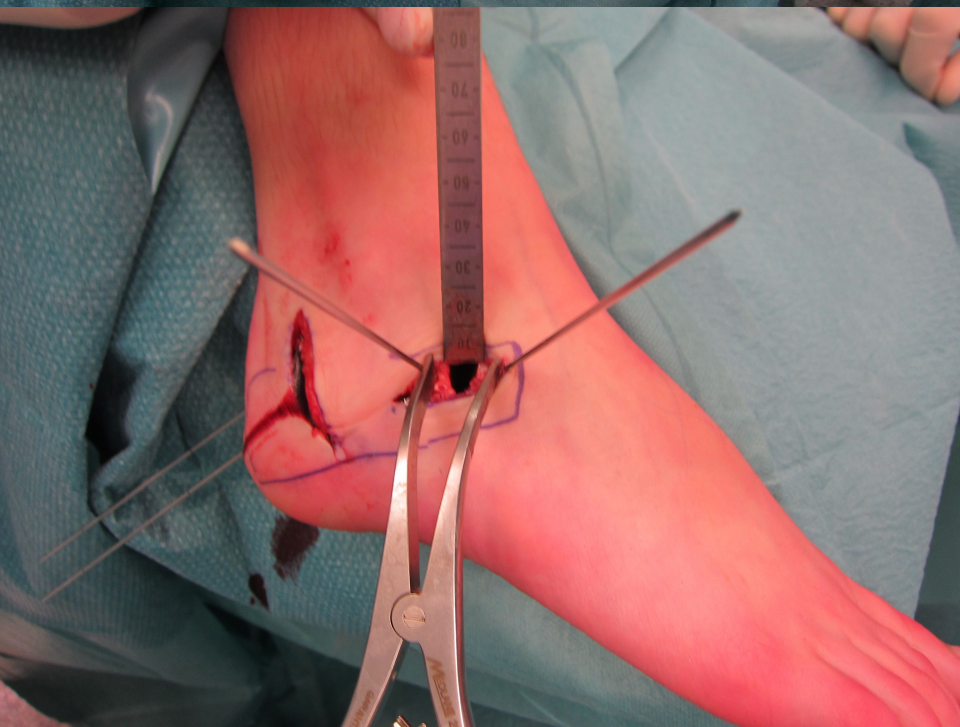
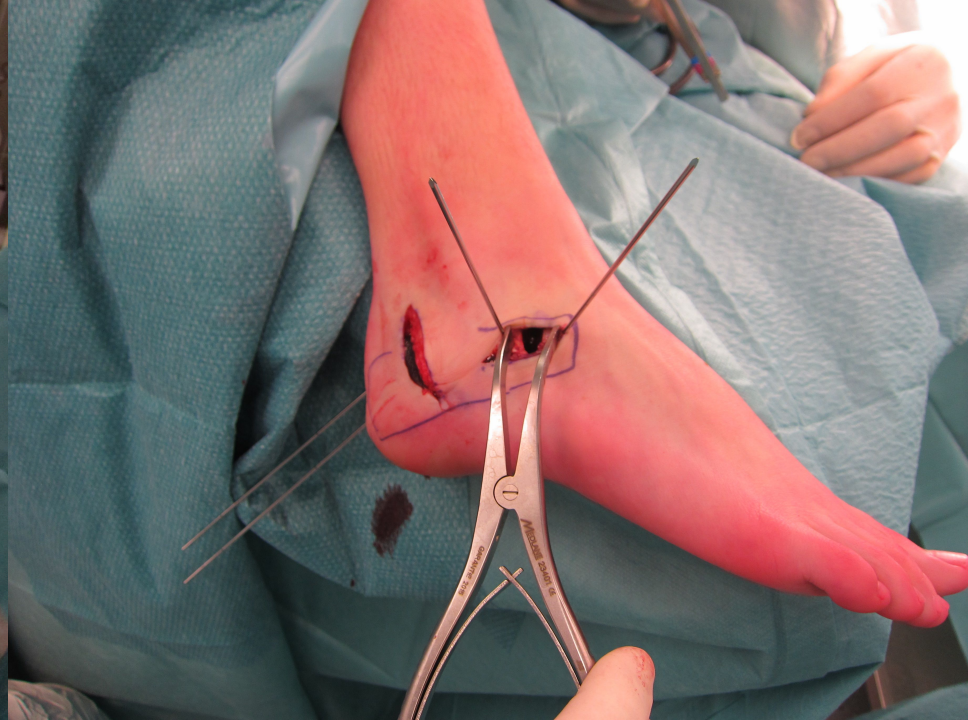








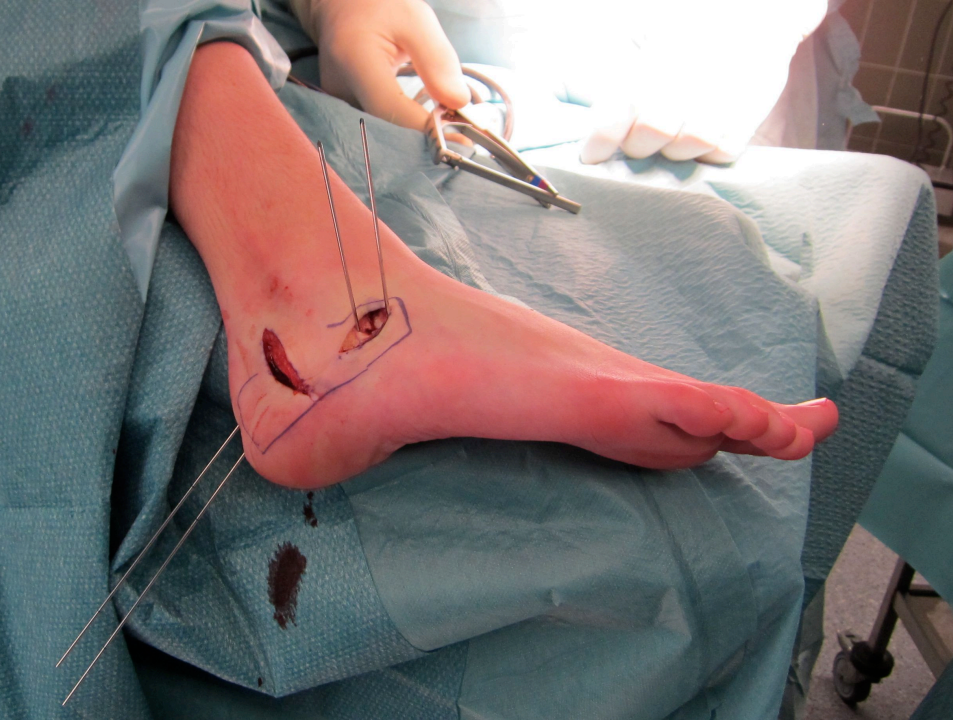



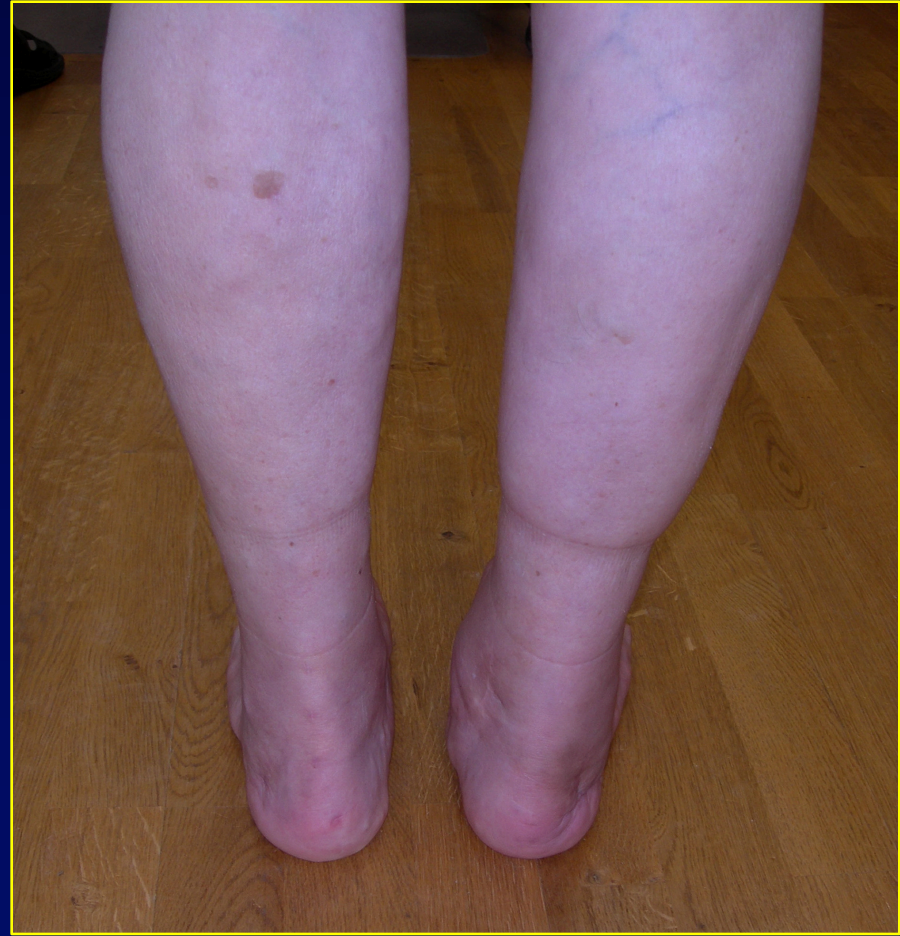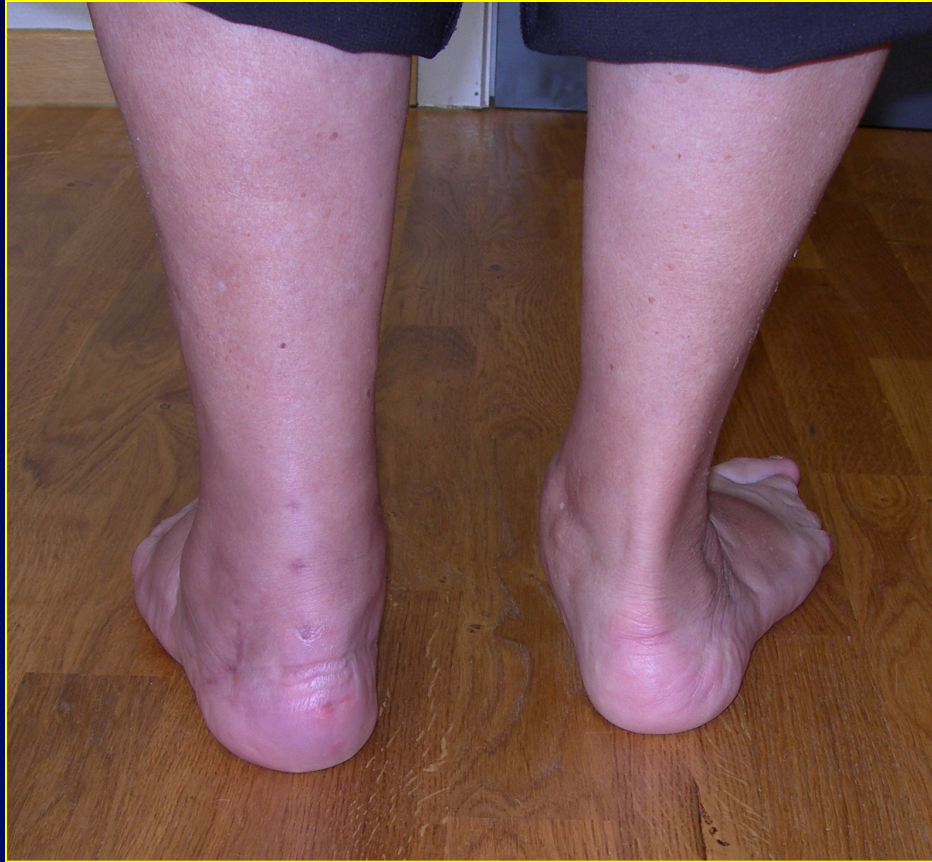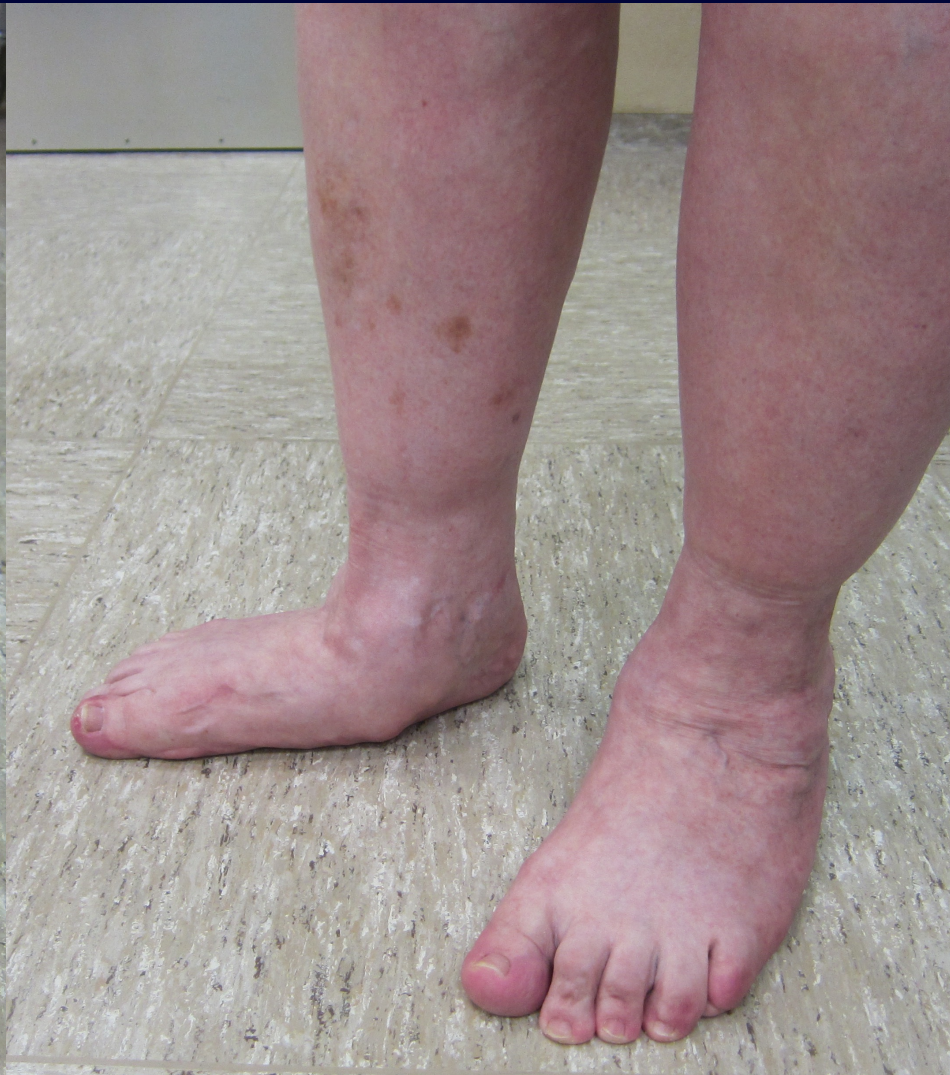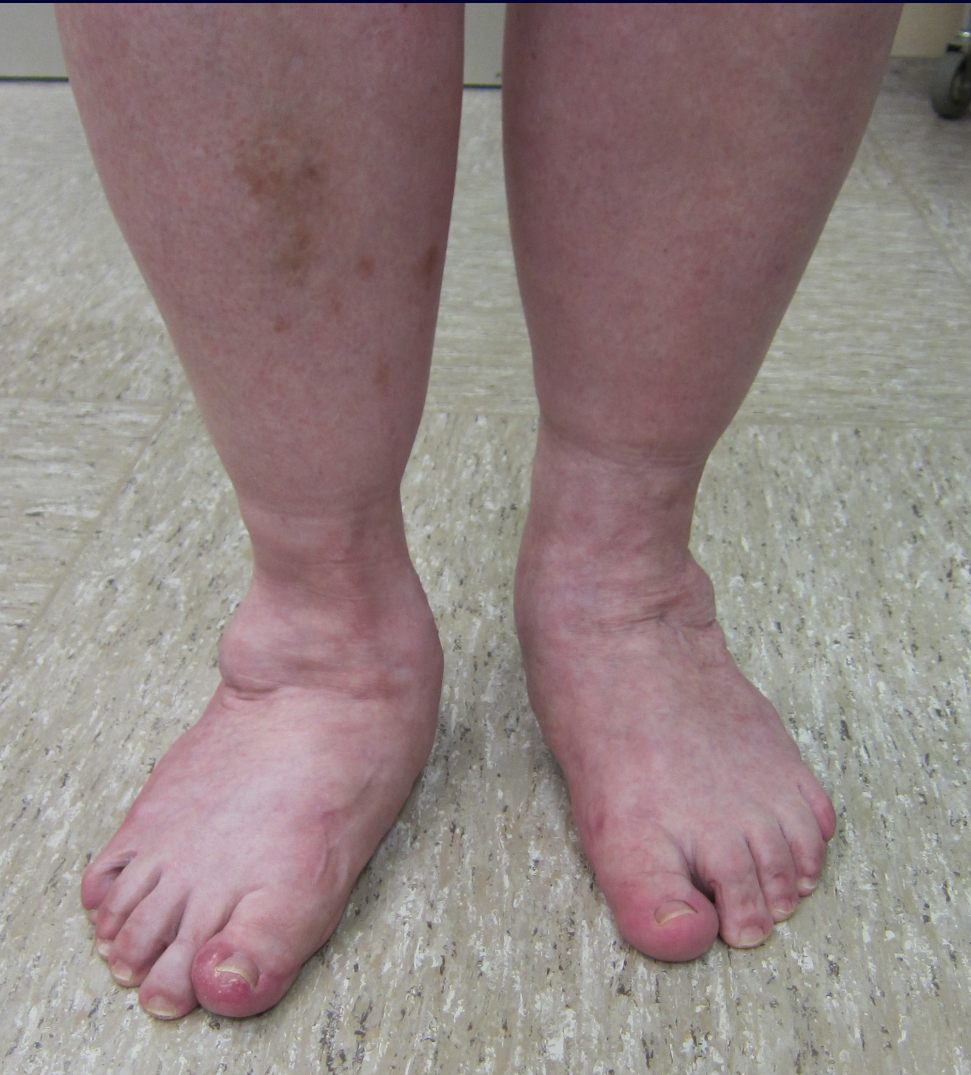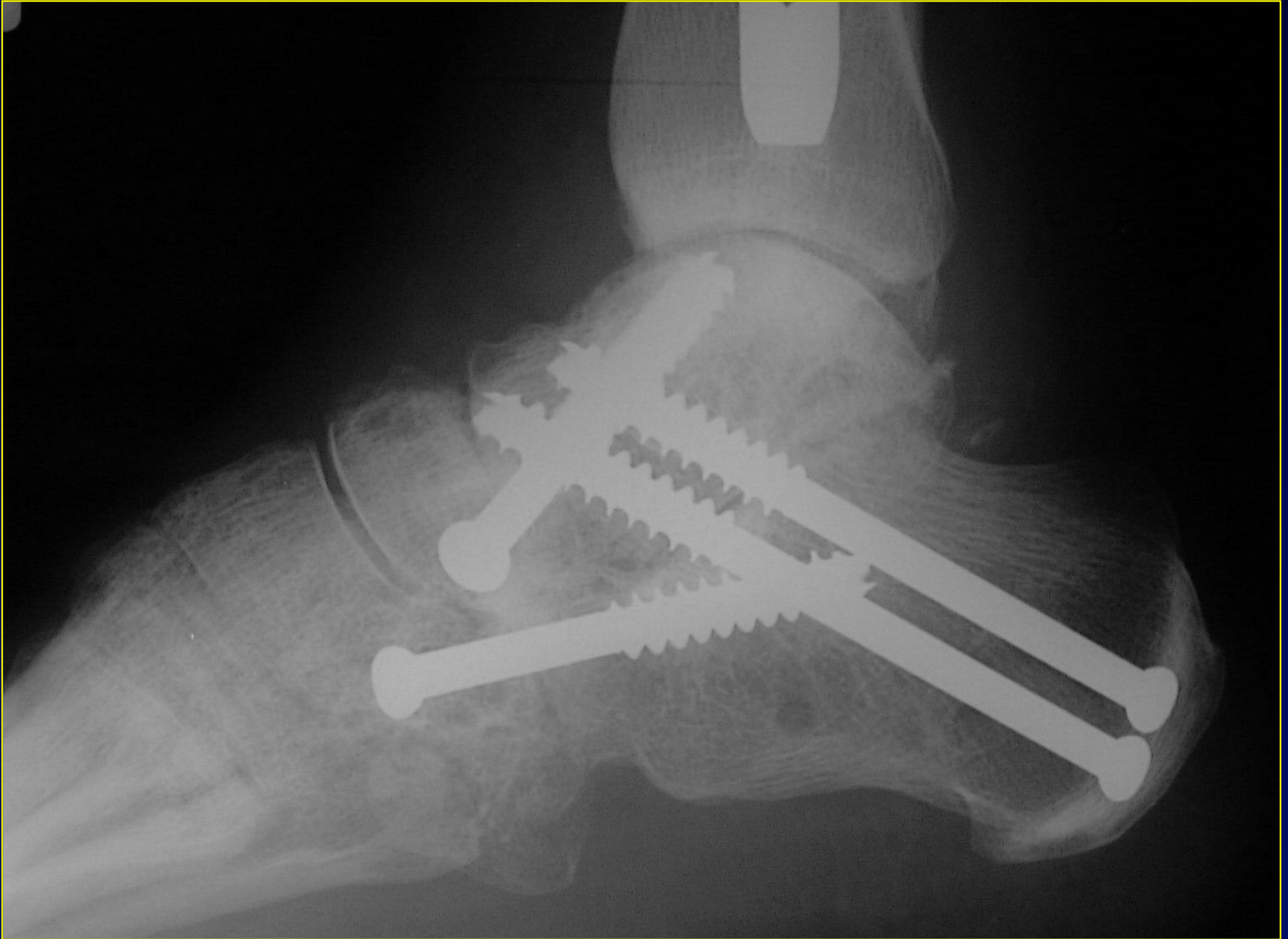




Stage 3

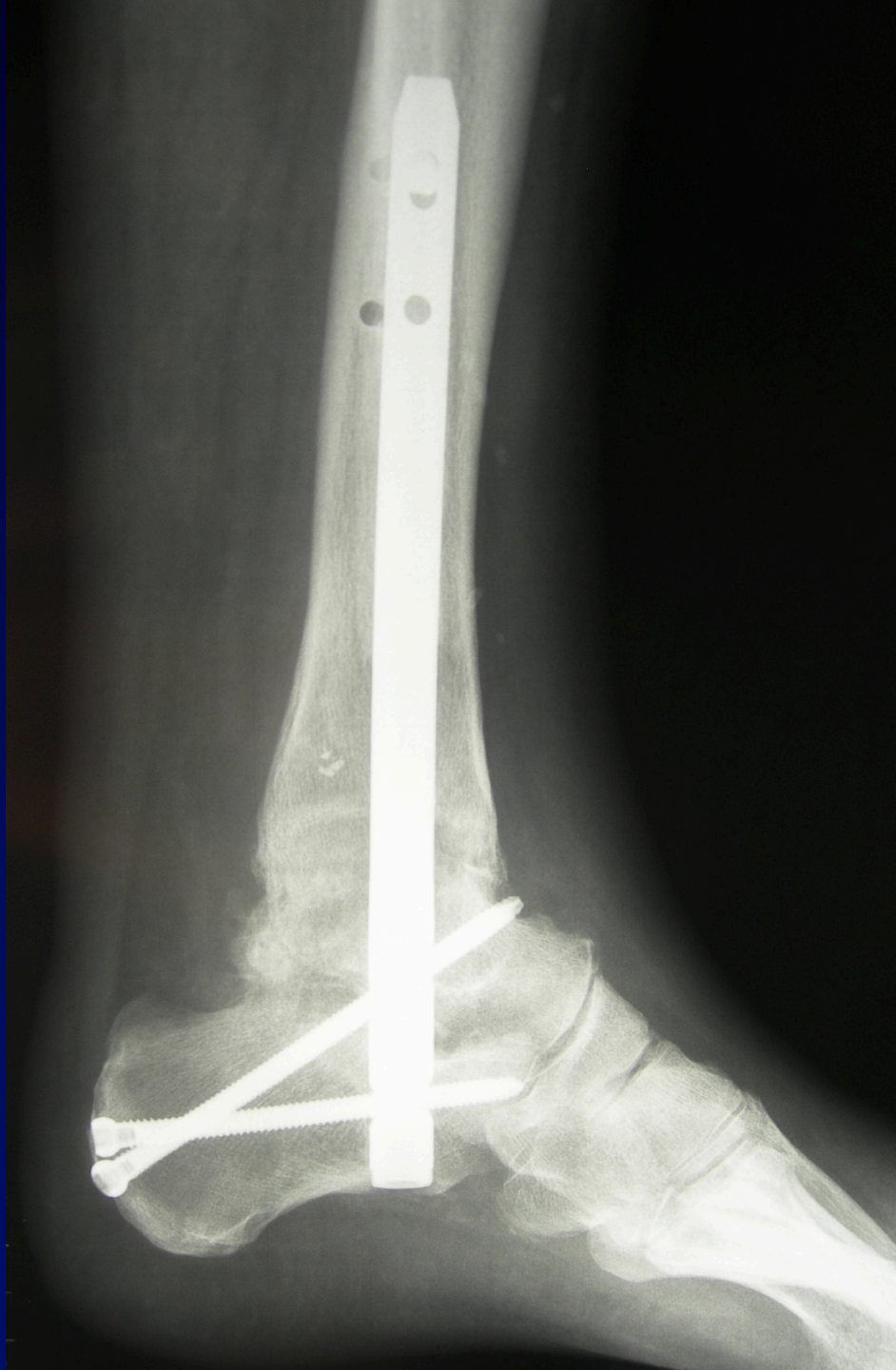








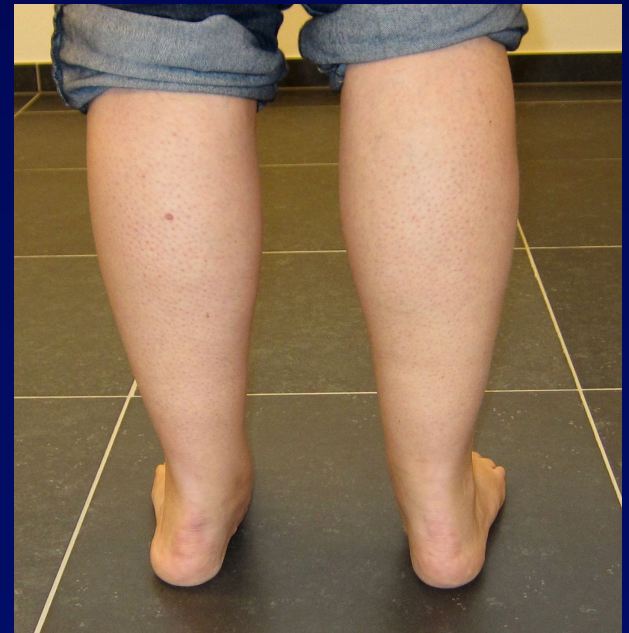Stage 4





# Tibialis posterior insufficiëntie

- Denk eraan.
- Behandelen om progressie te voorkomen.



Dank voor uw aandacht