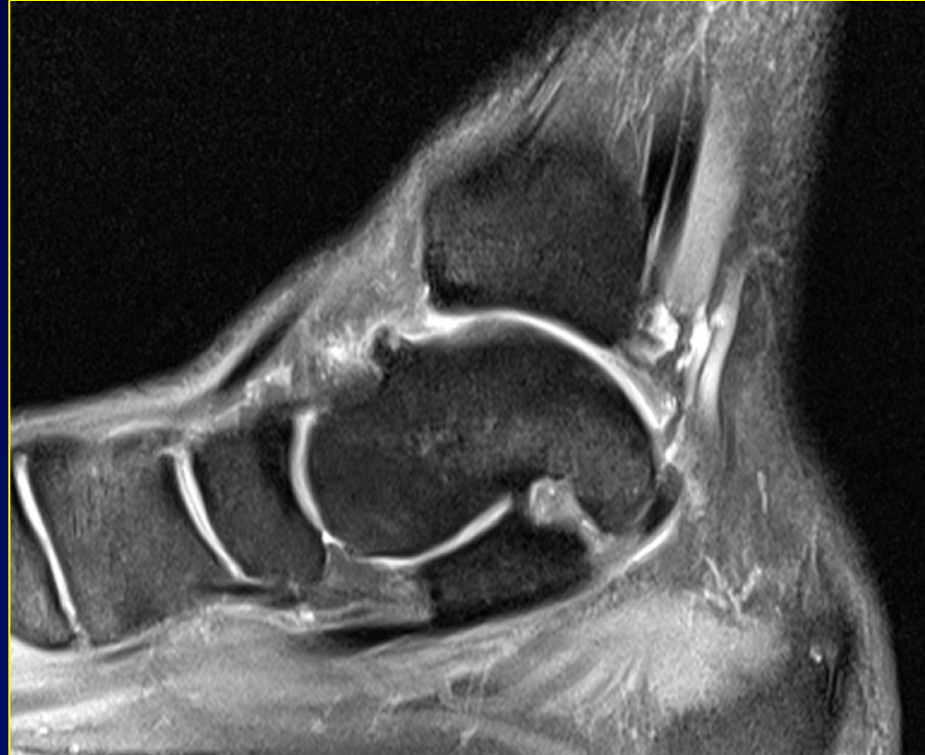
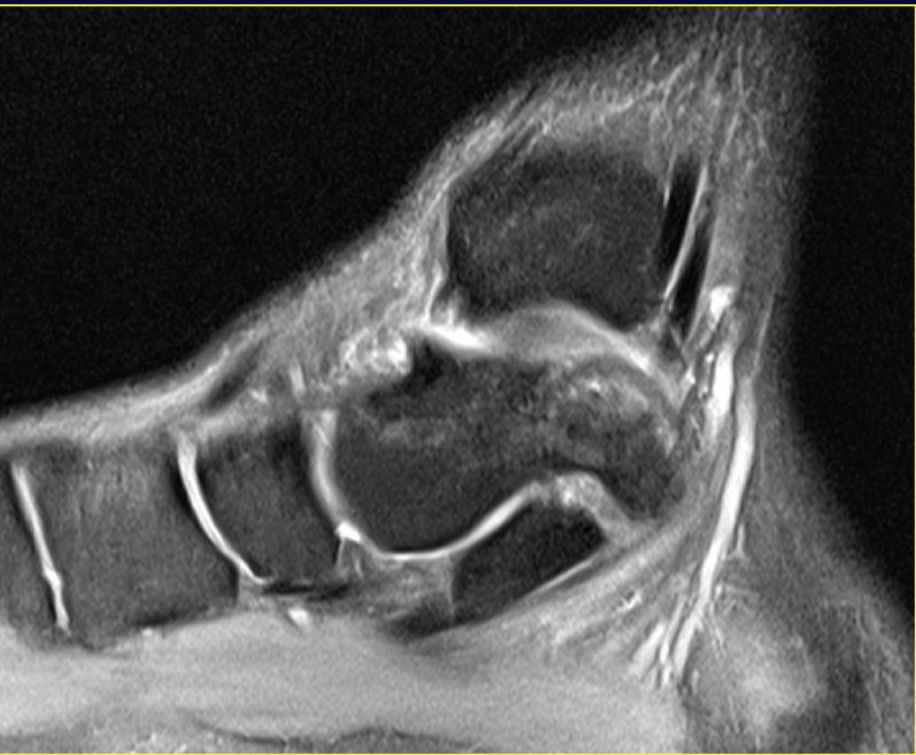
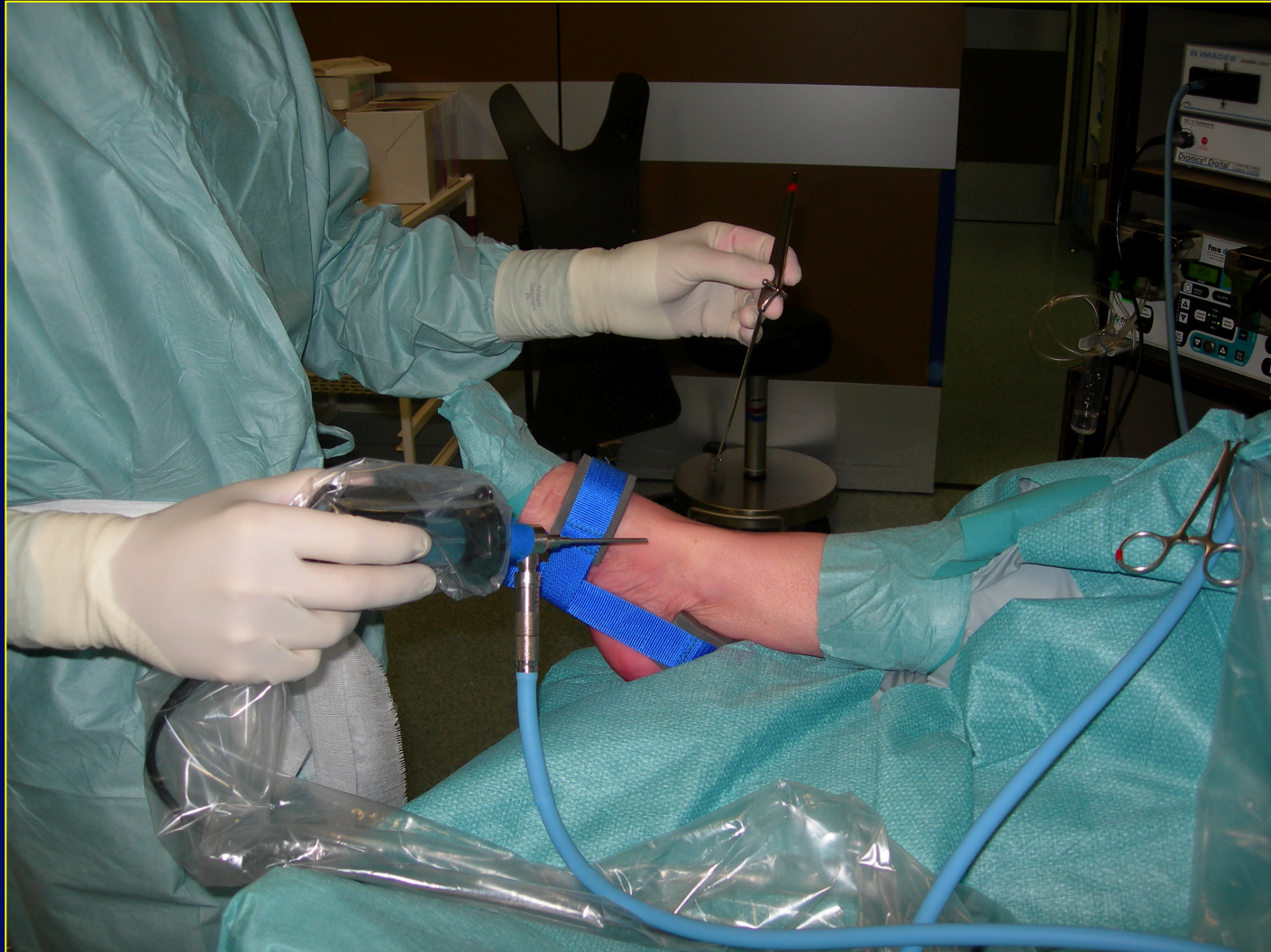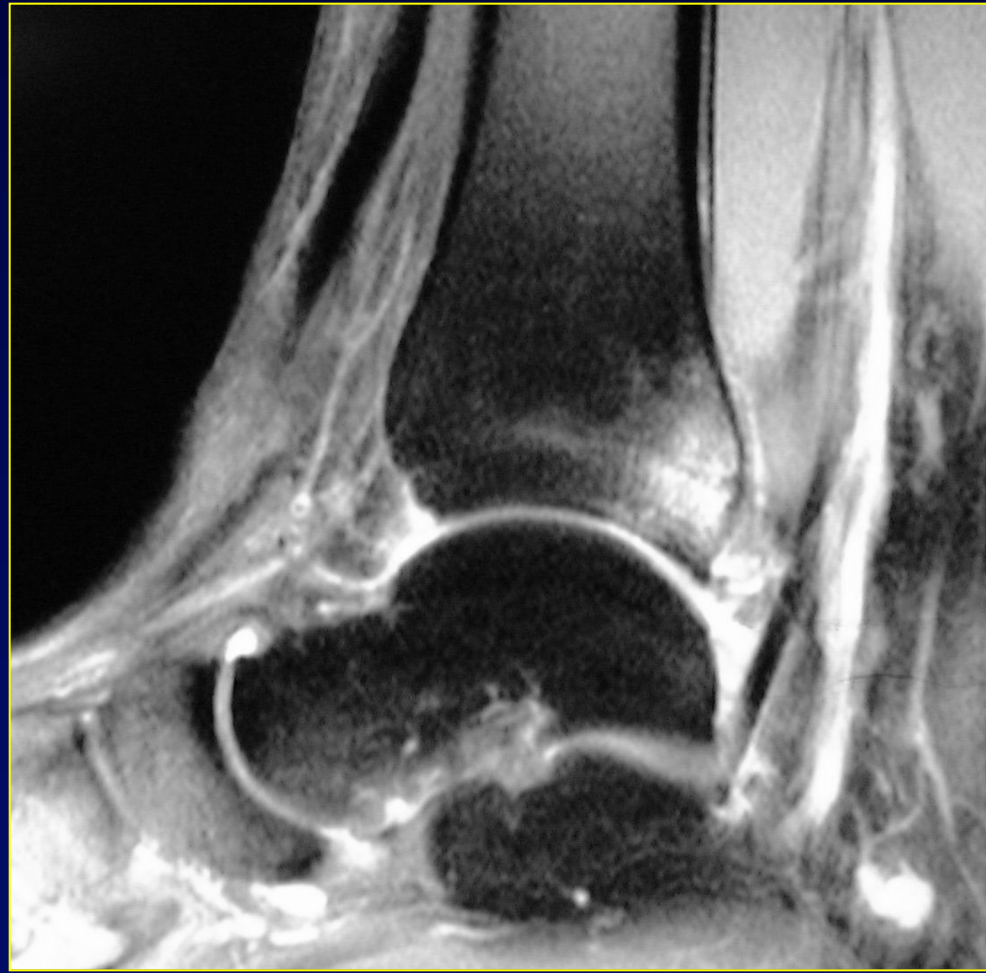
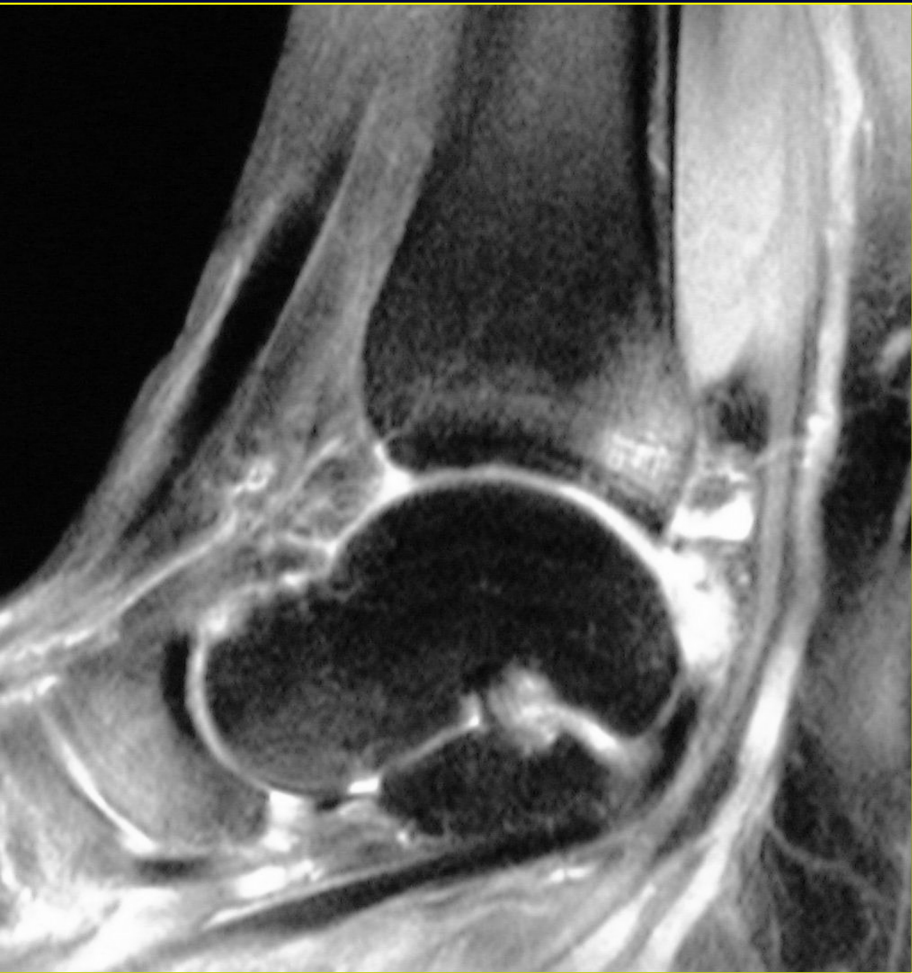
Enkel arthroscopie : hoe en voor wie ?

Geoffroy Vandeputte
Lier 12 juni 2010

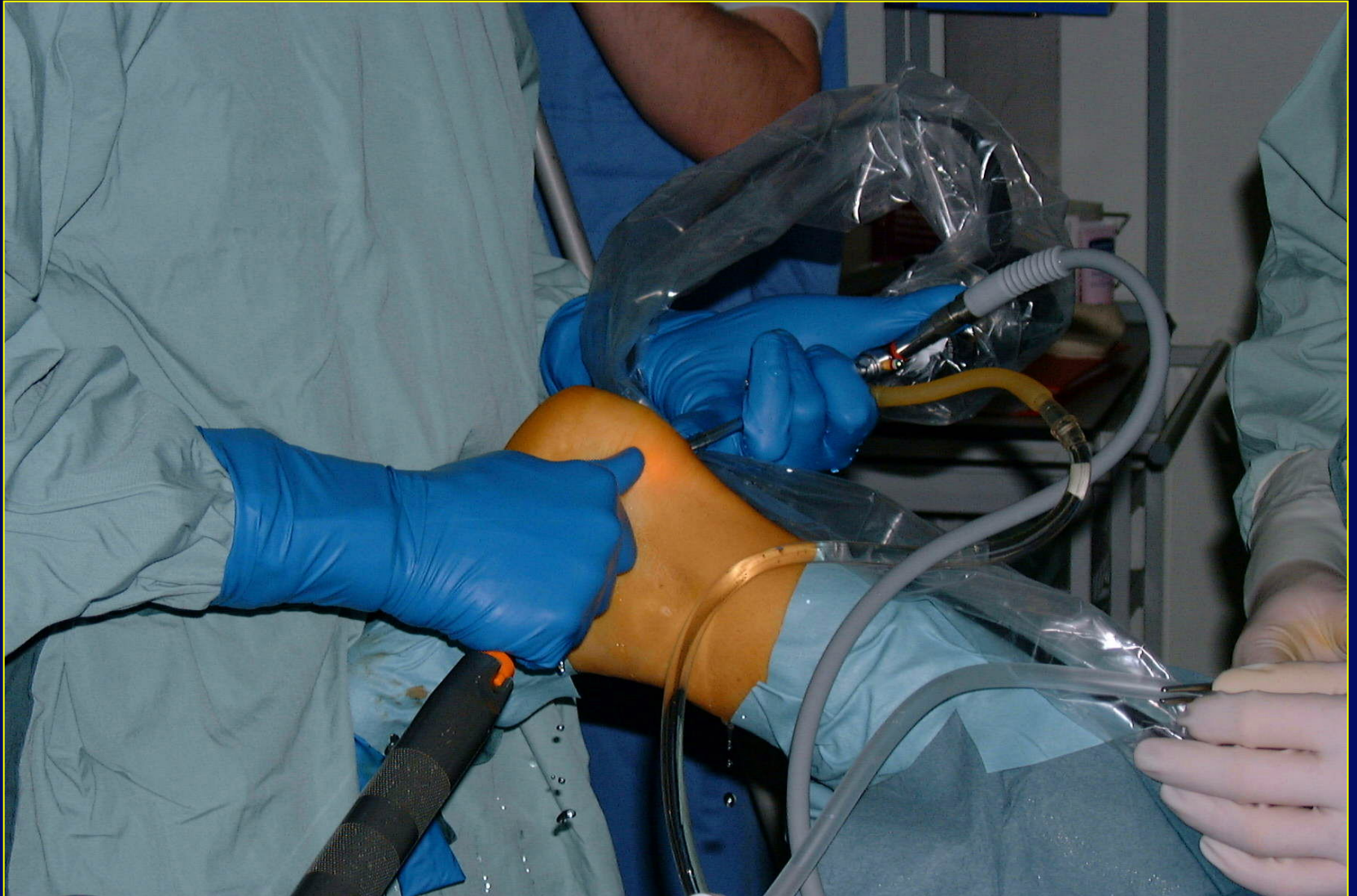

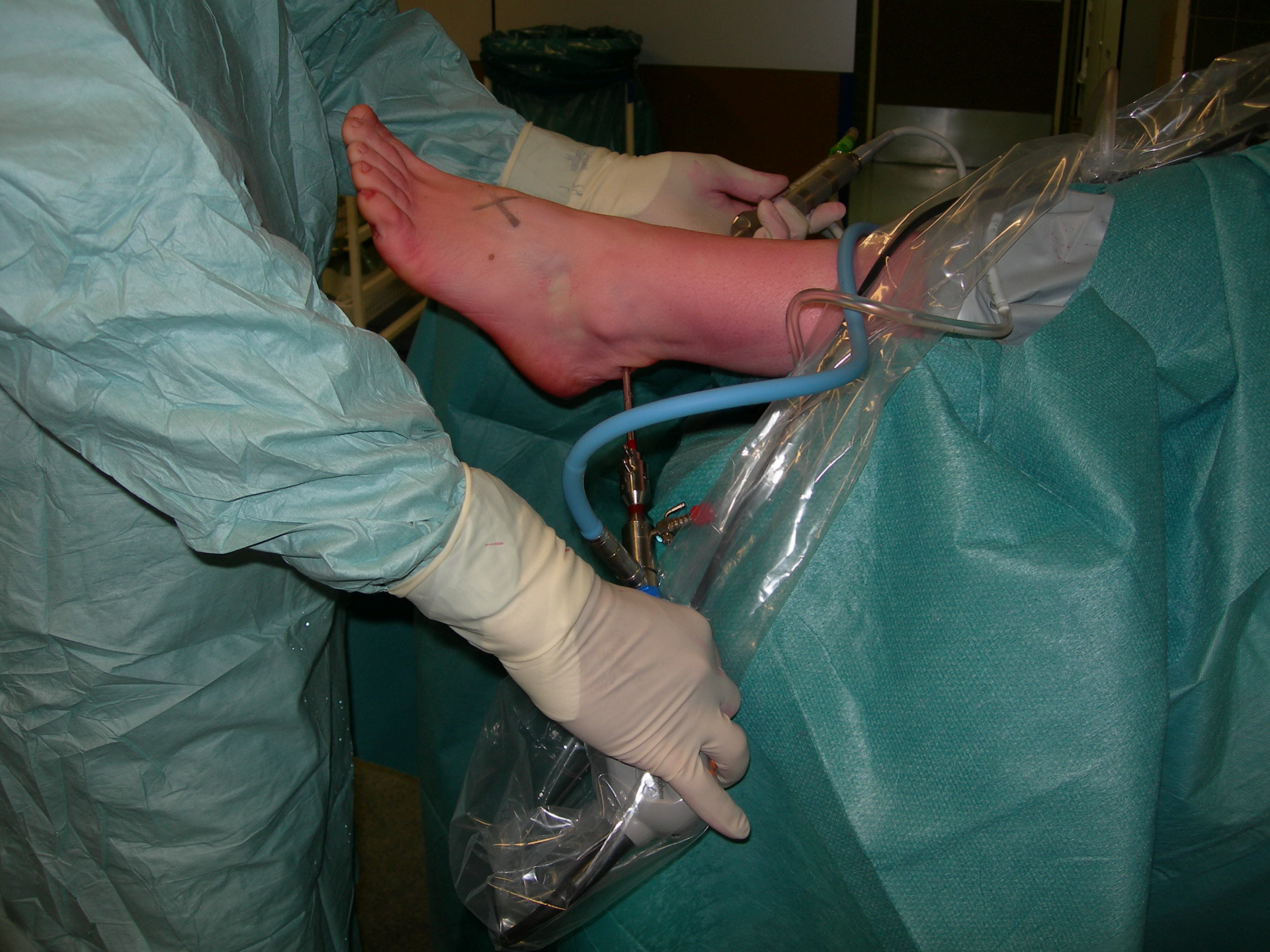Vooraan





Achteraan

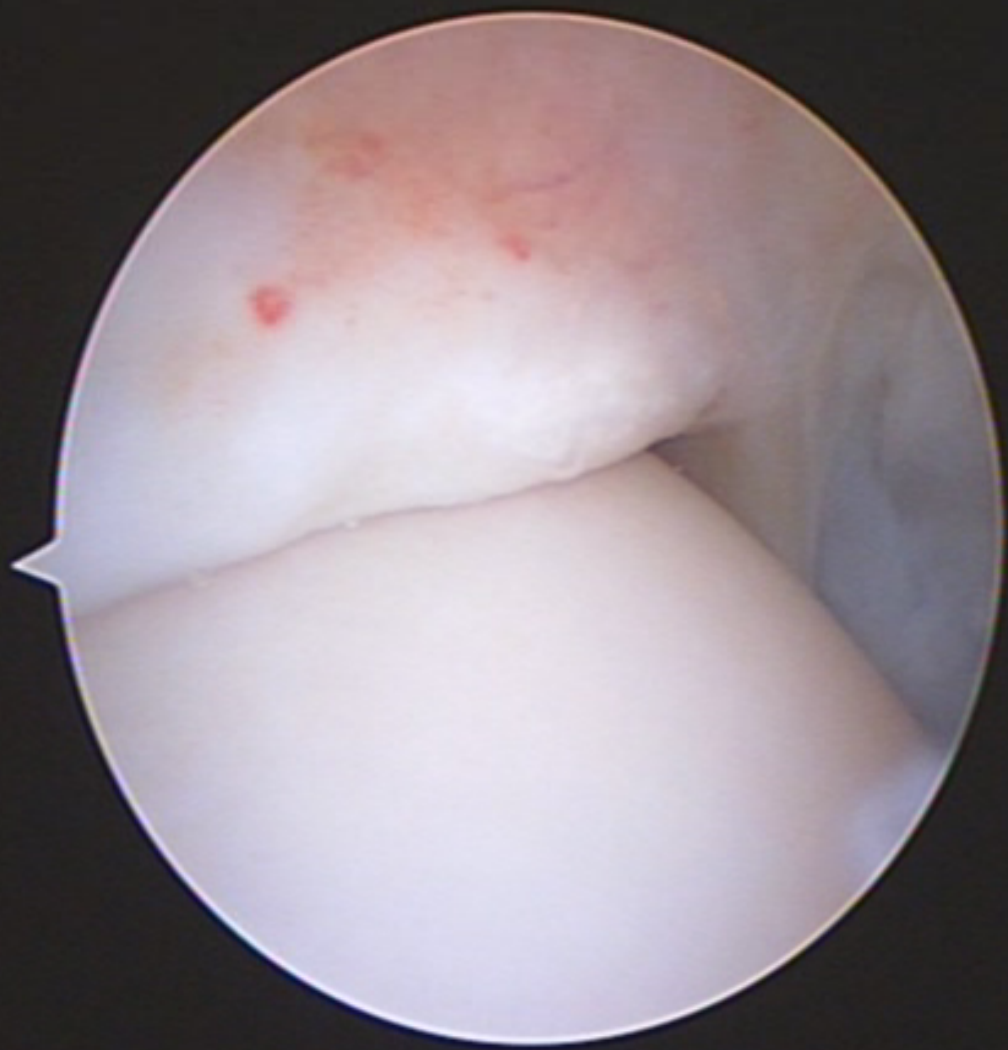


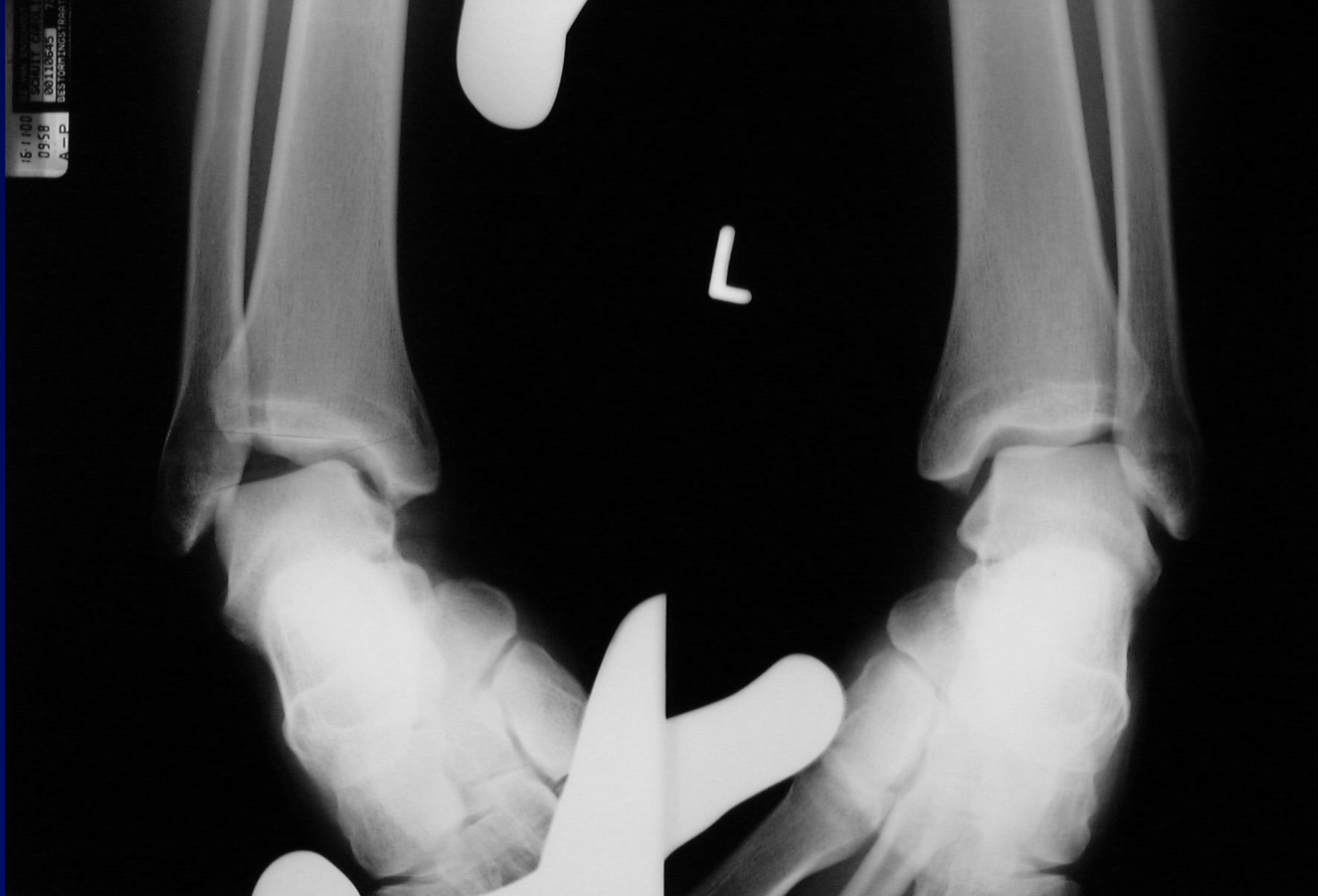

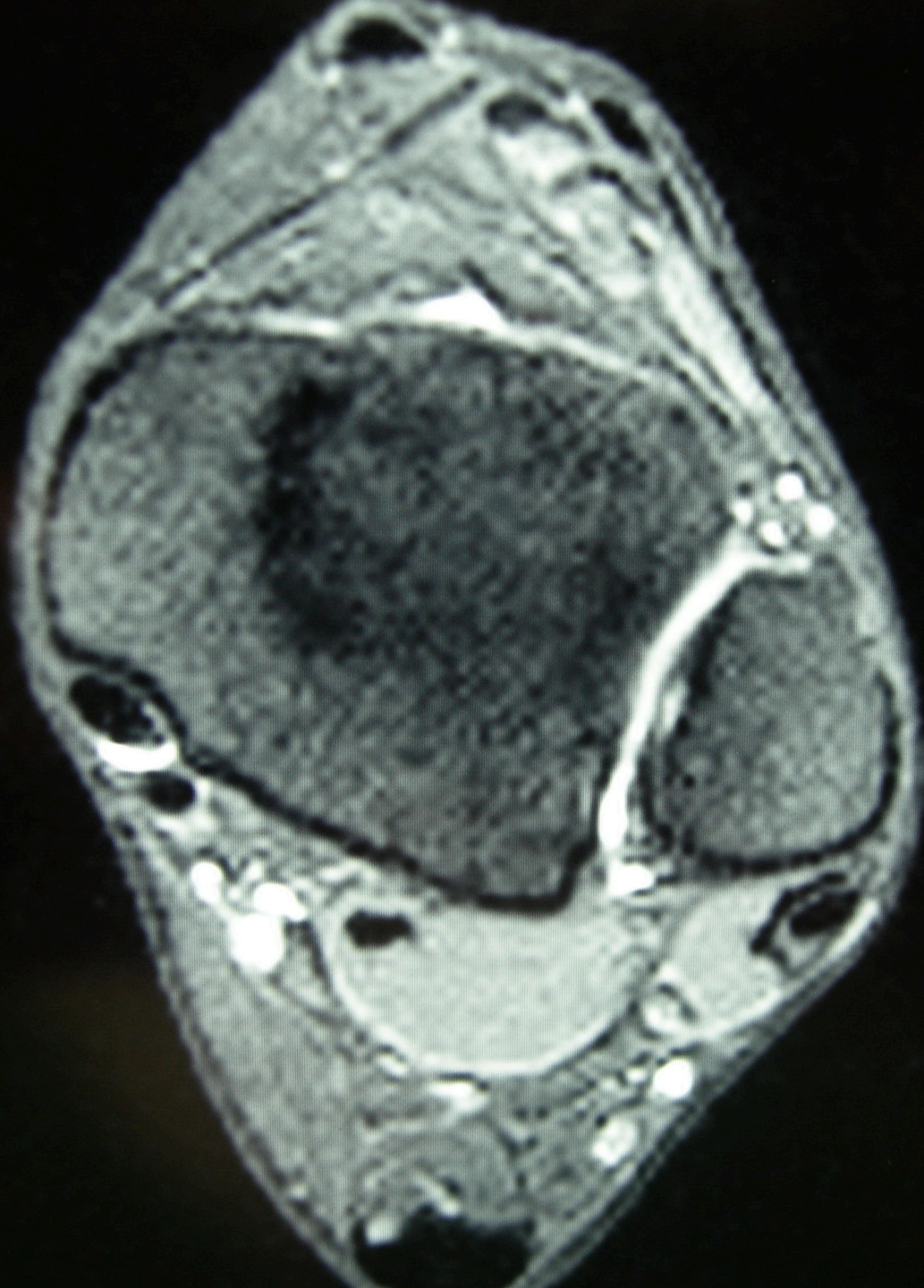
NMR

Bone Scan

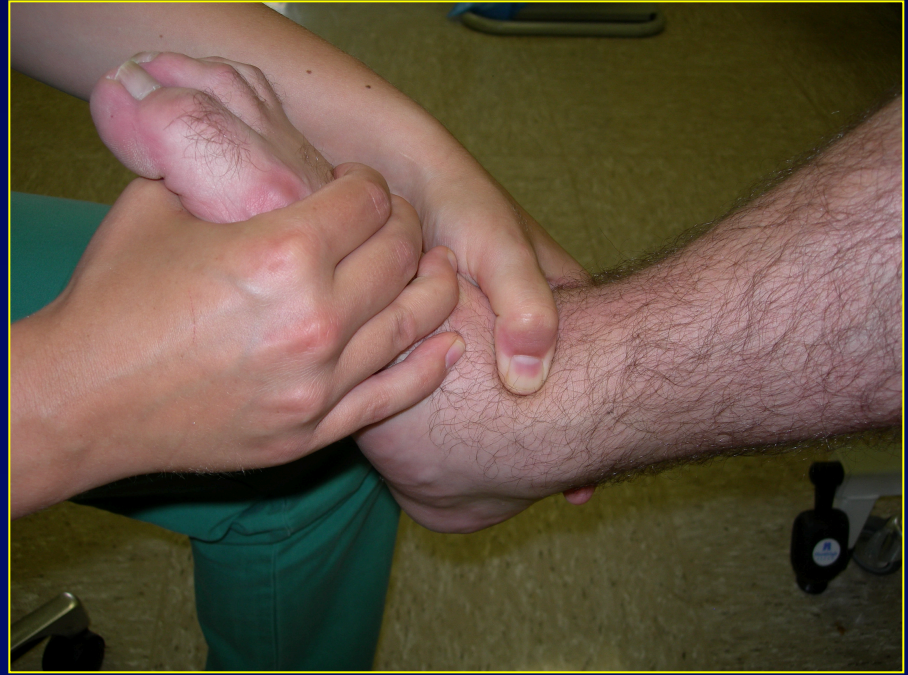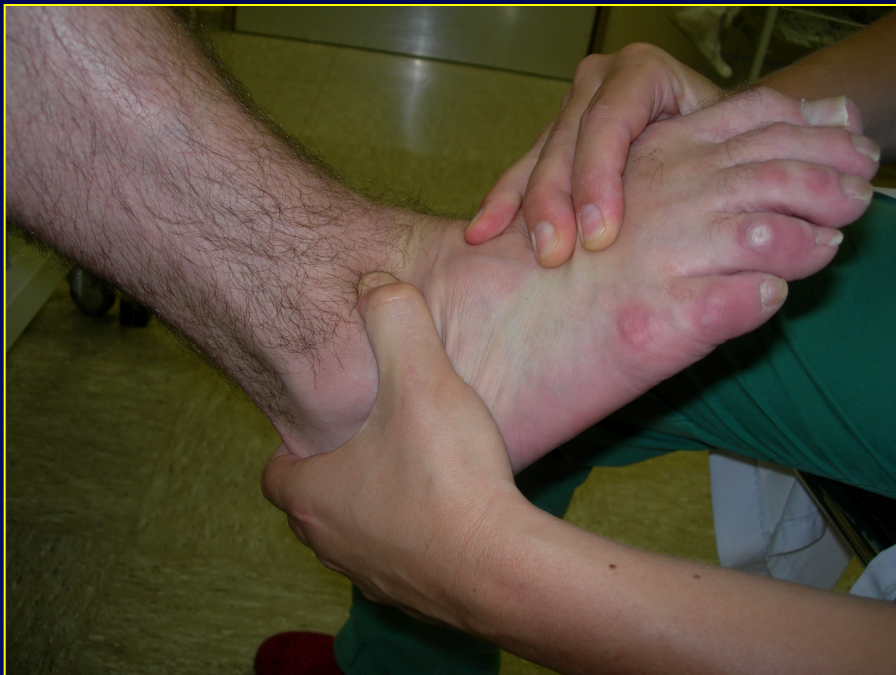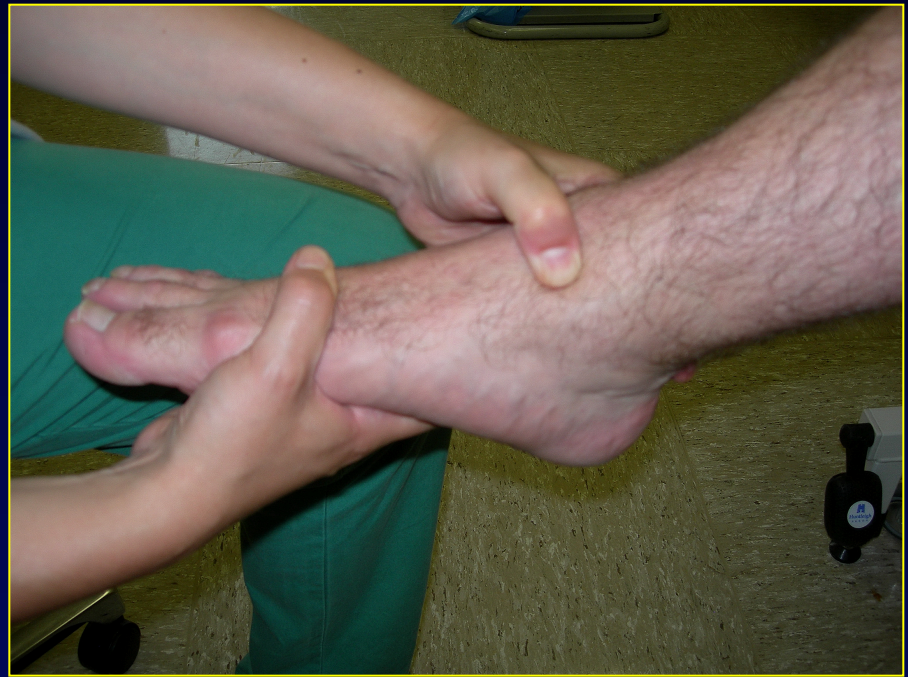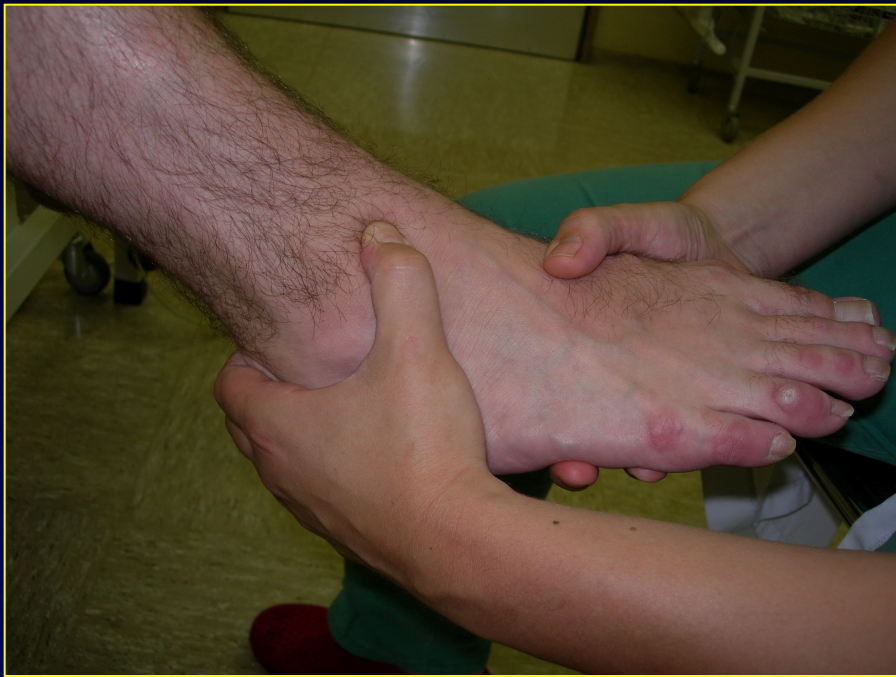Spect CT

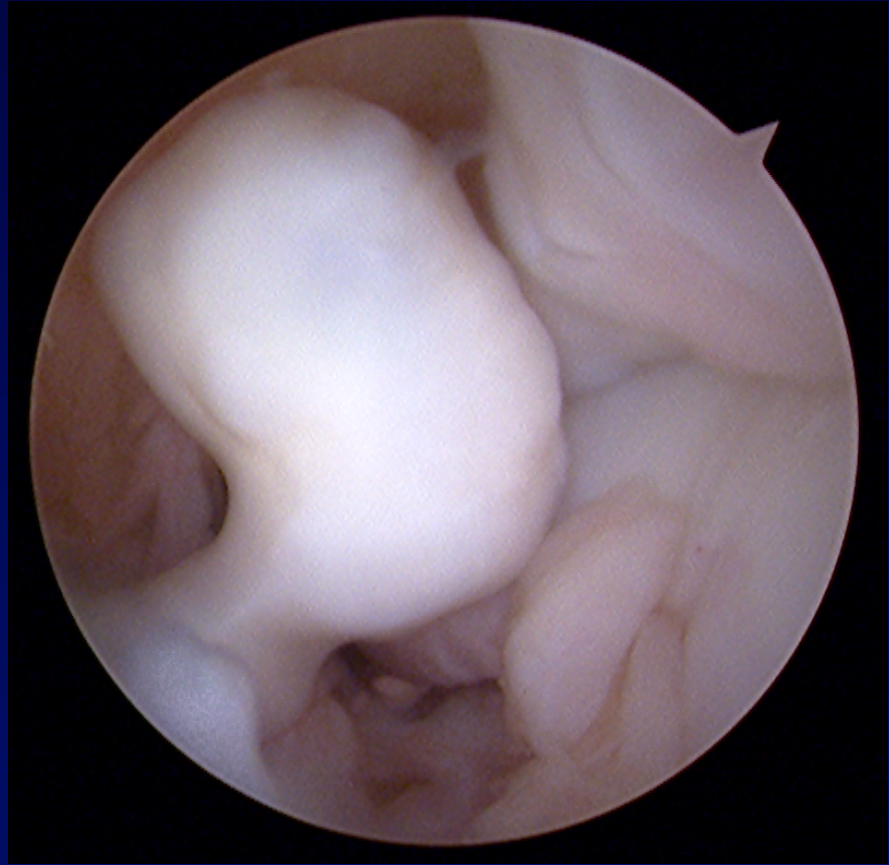
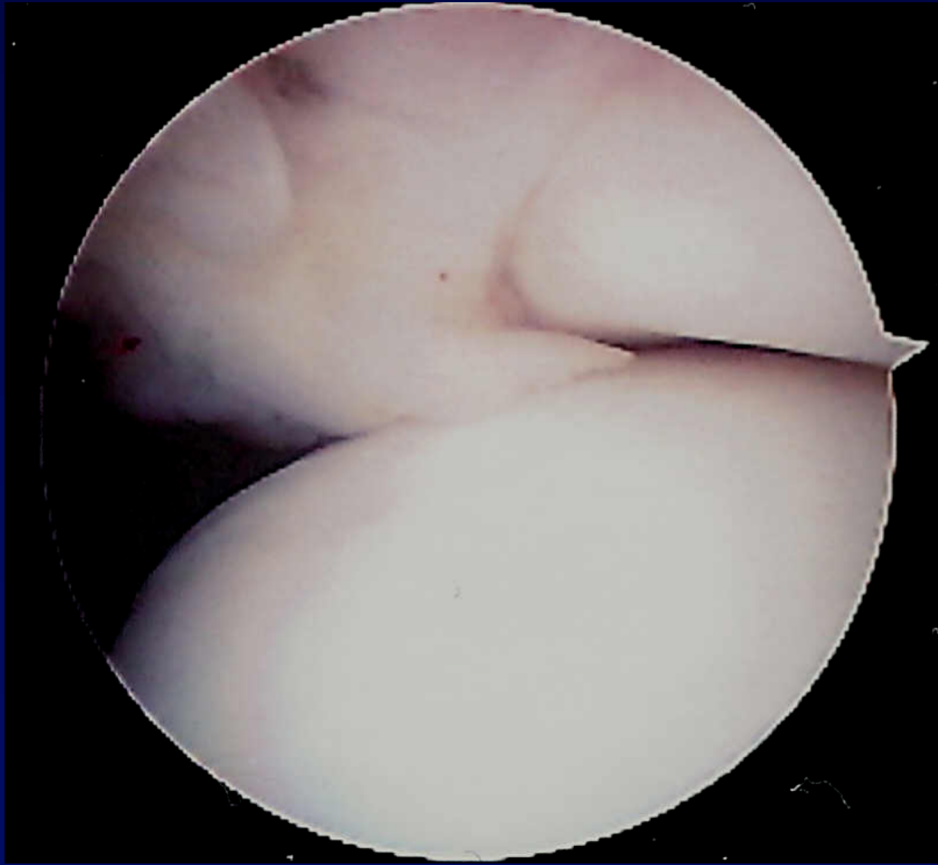


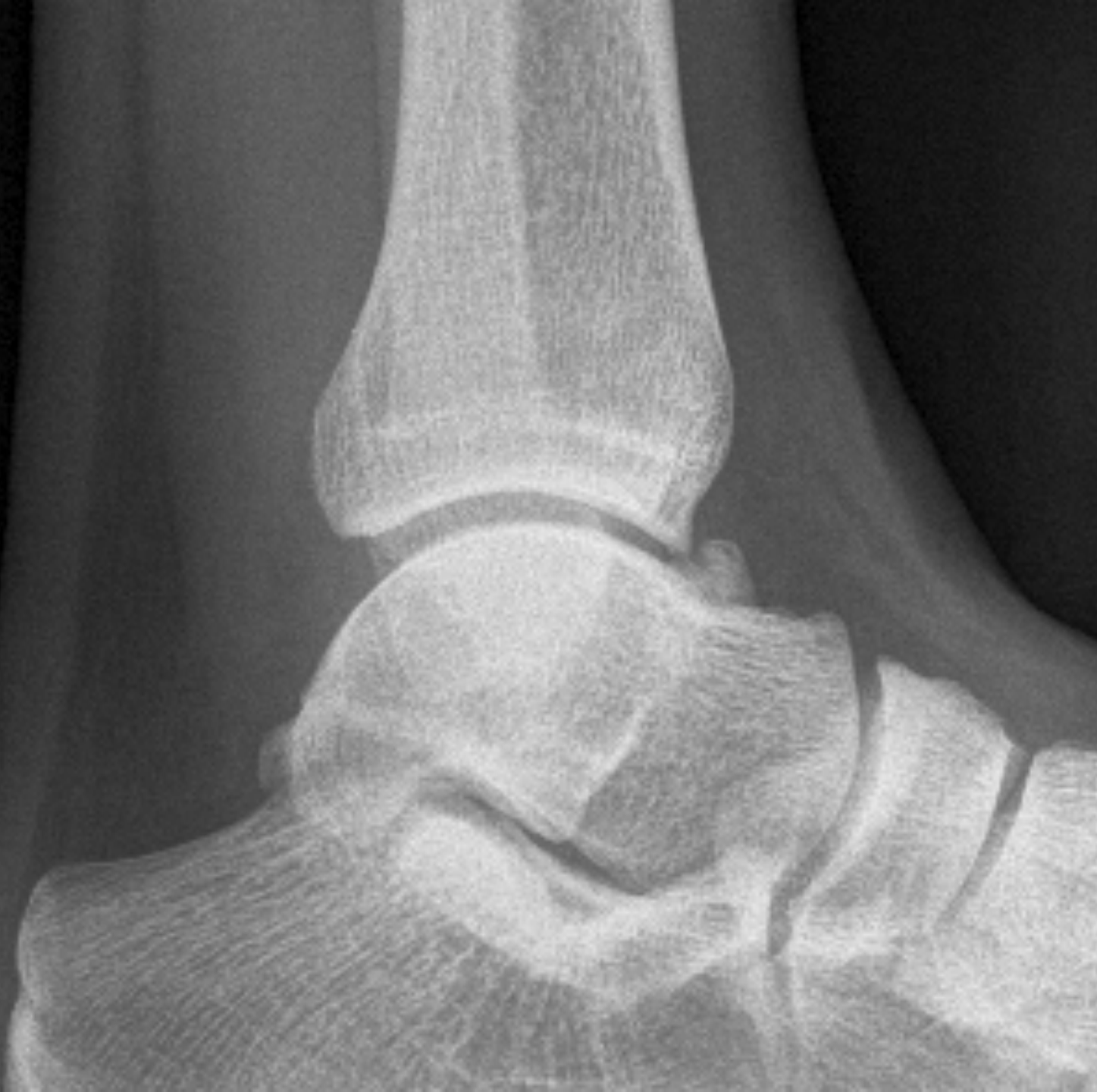

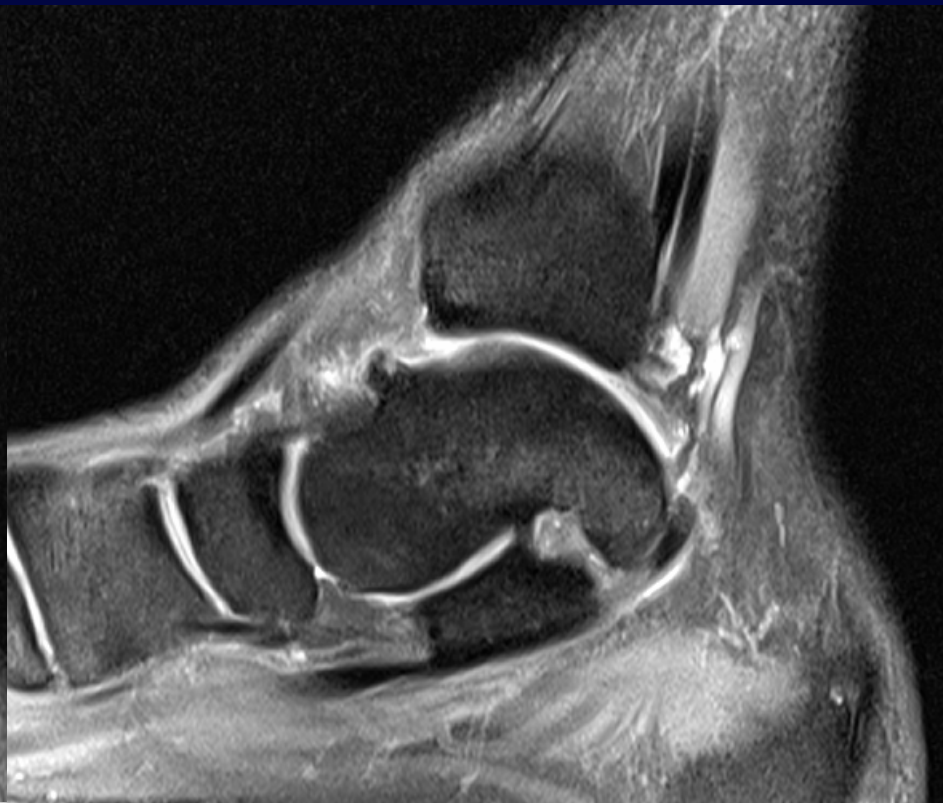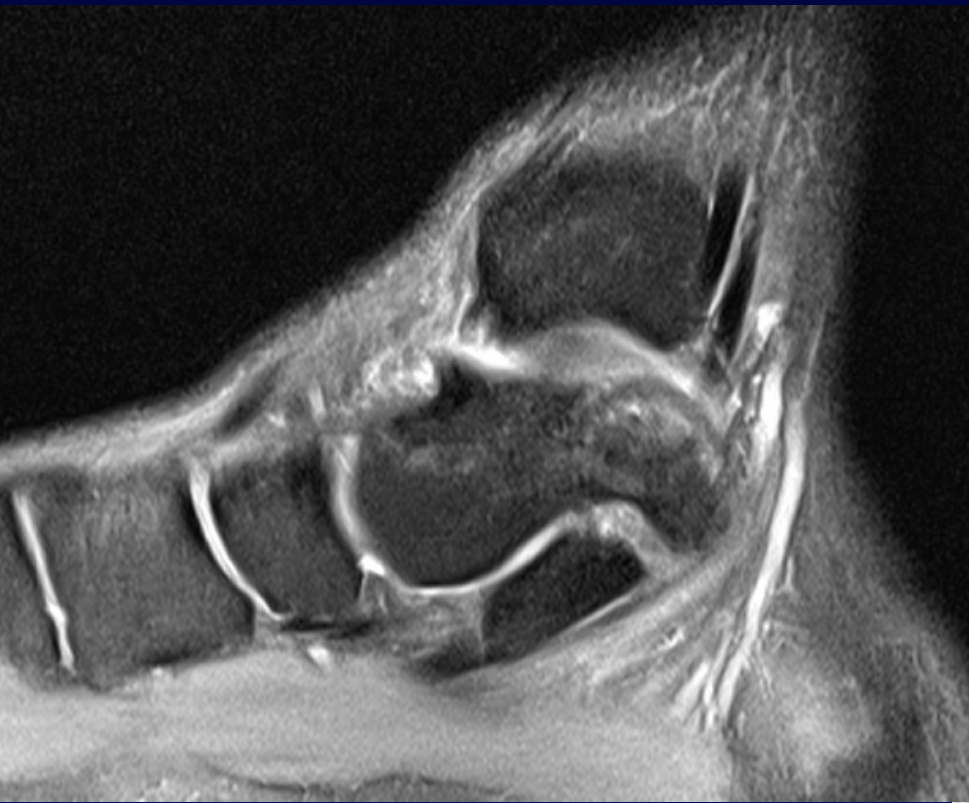


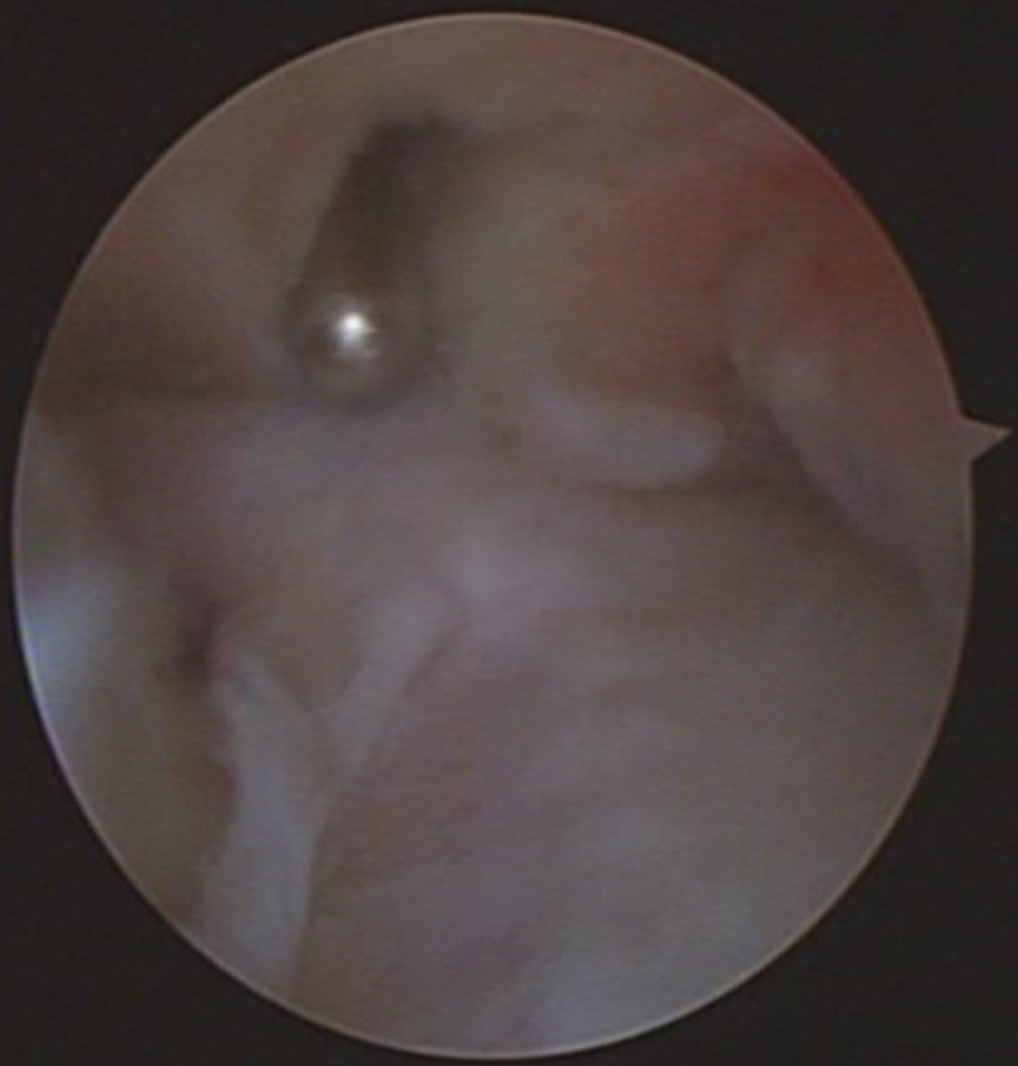RI

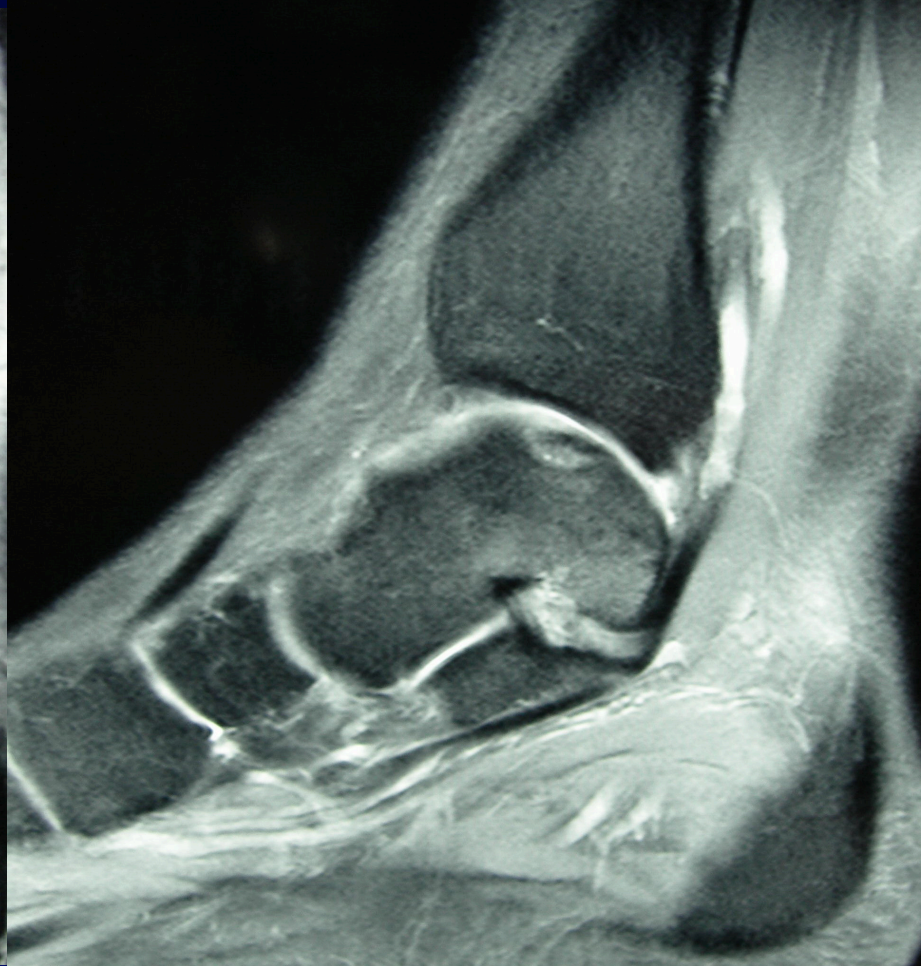
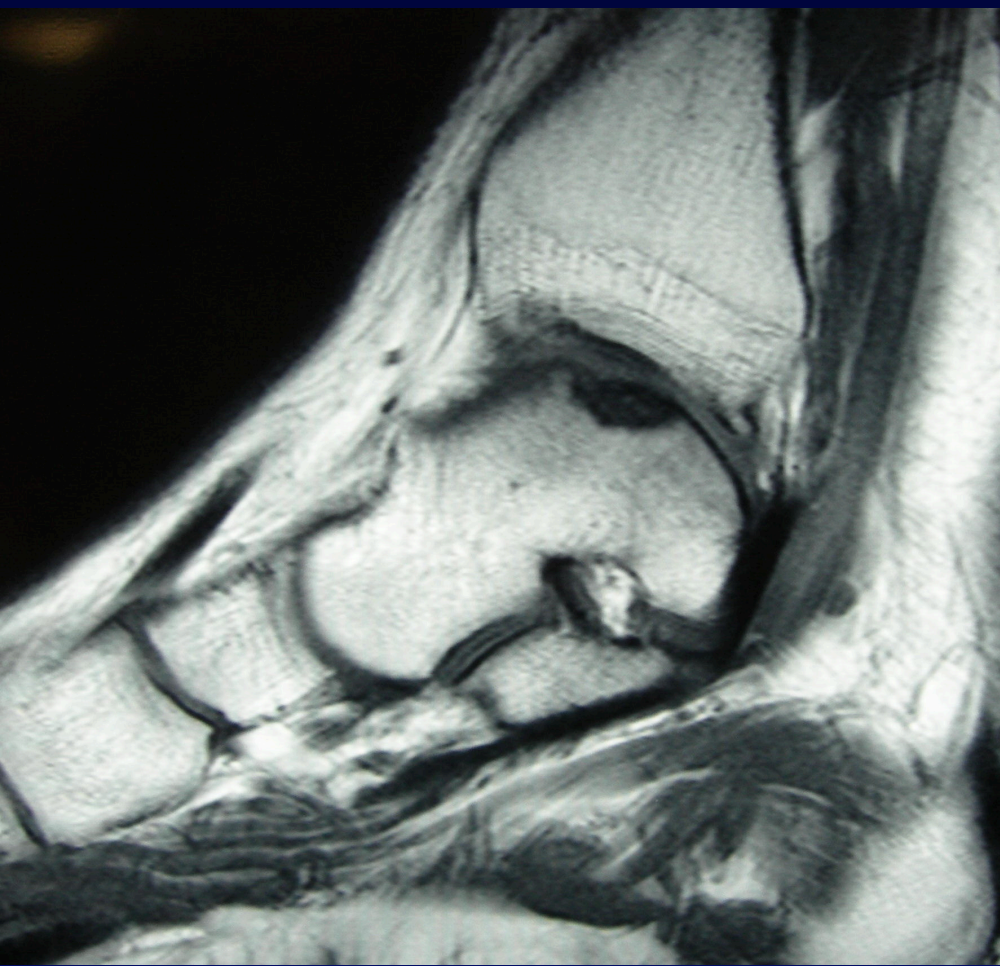


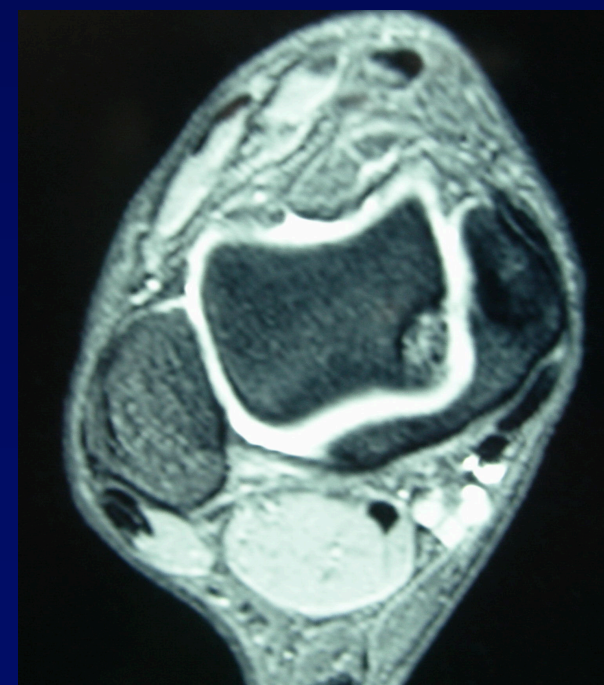
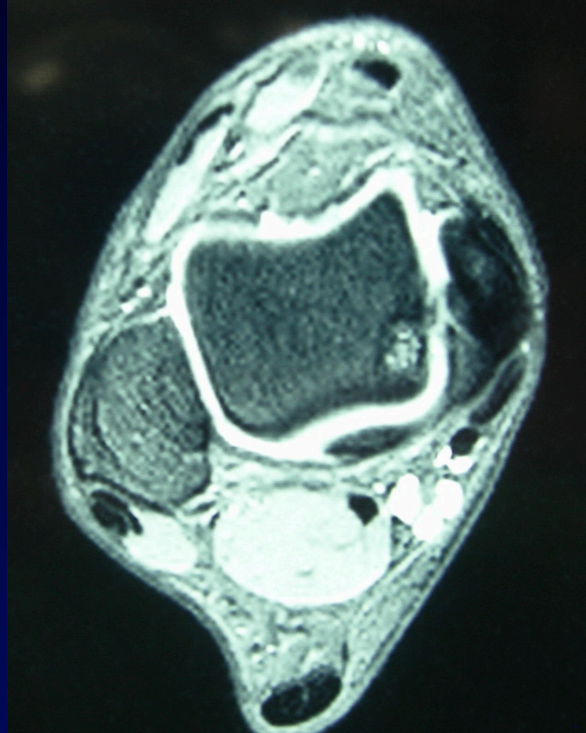
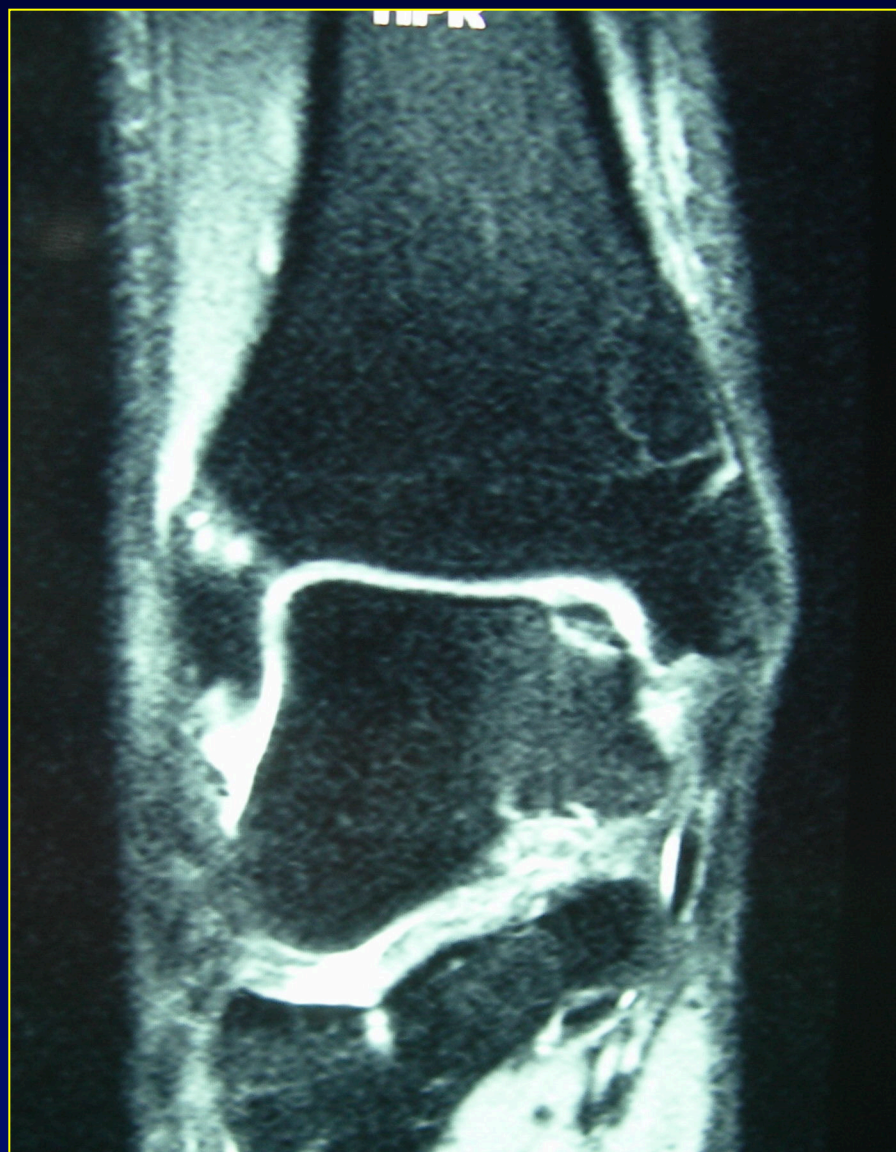


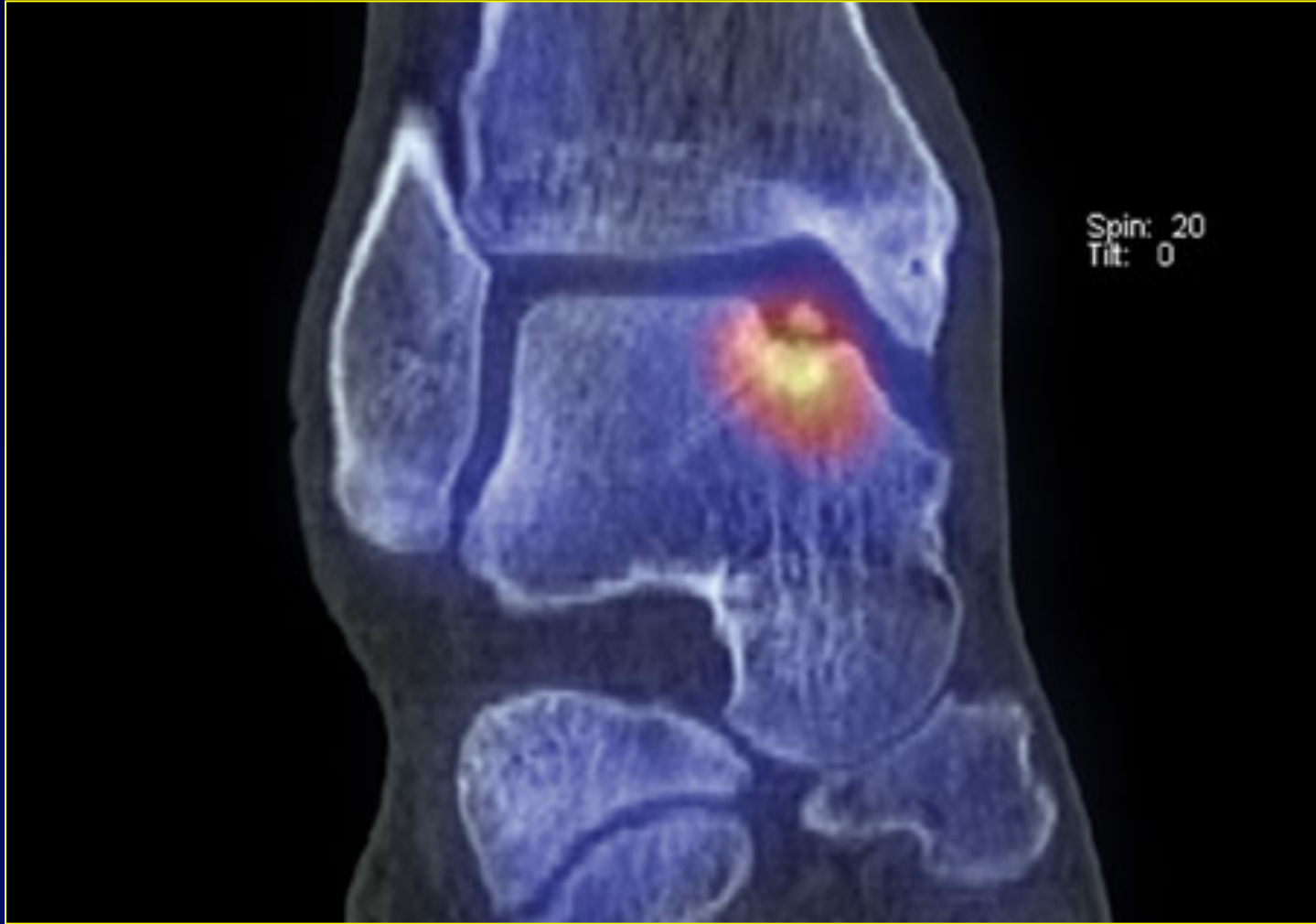
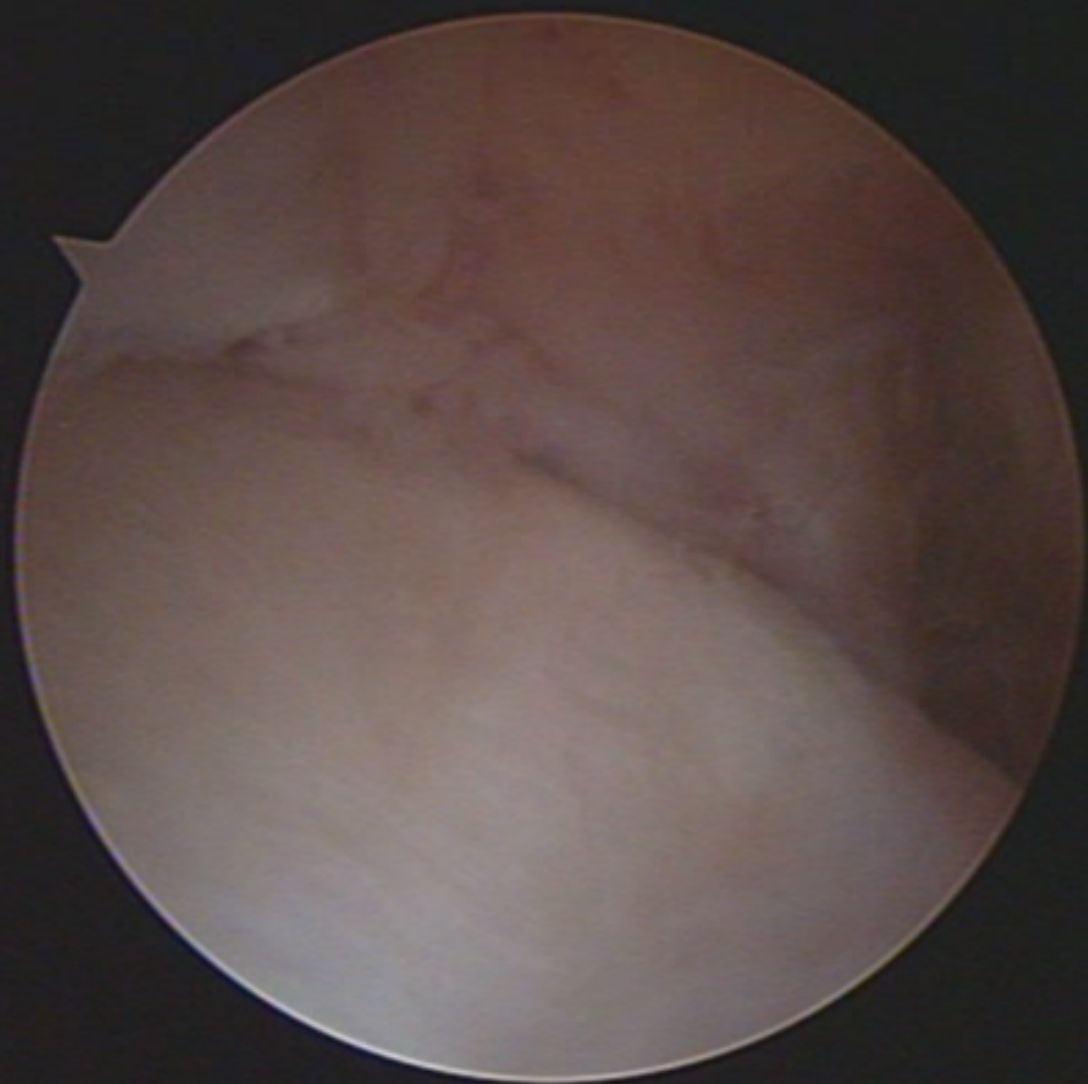




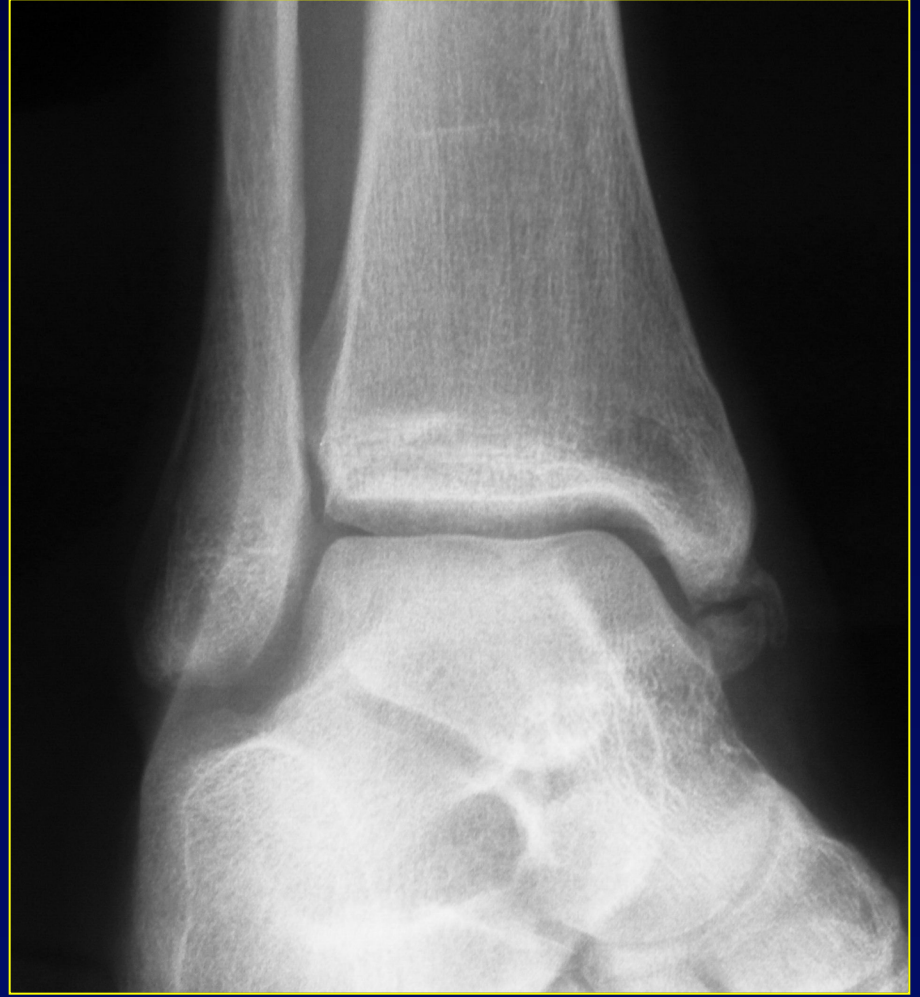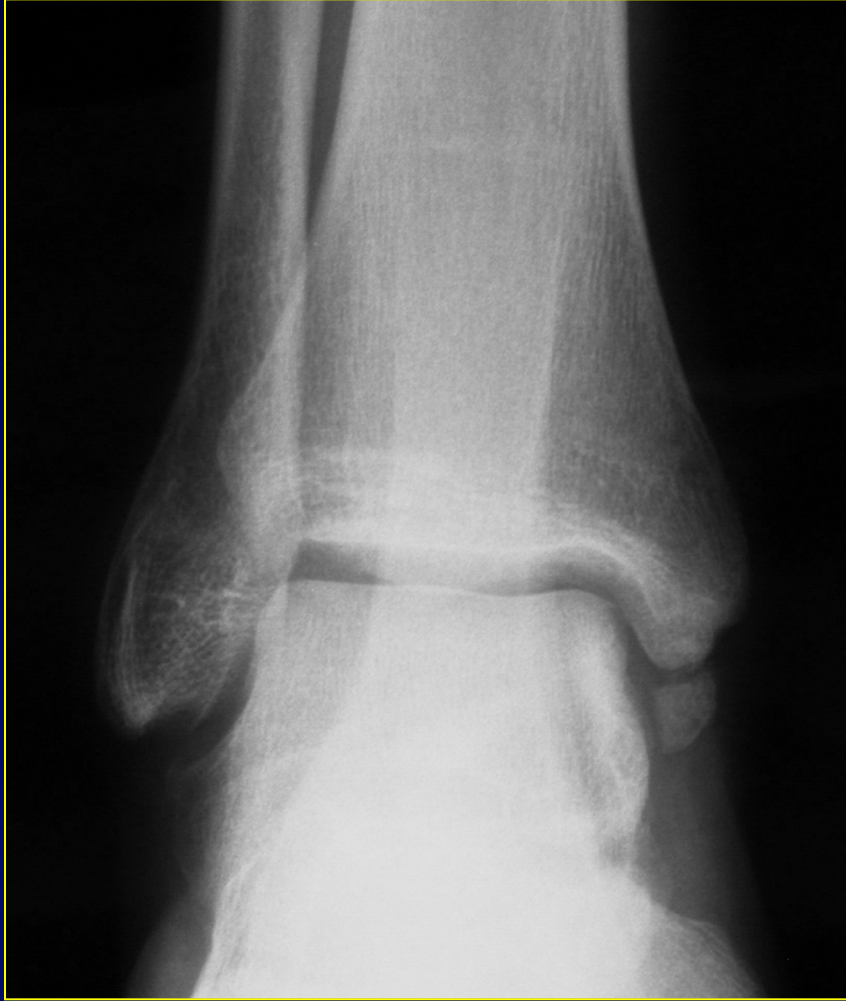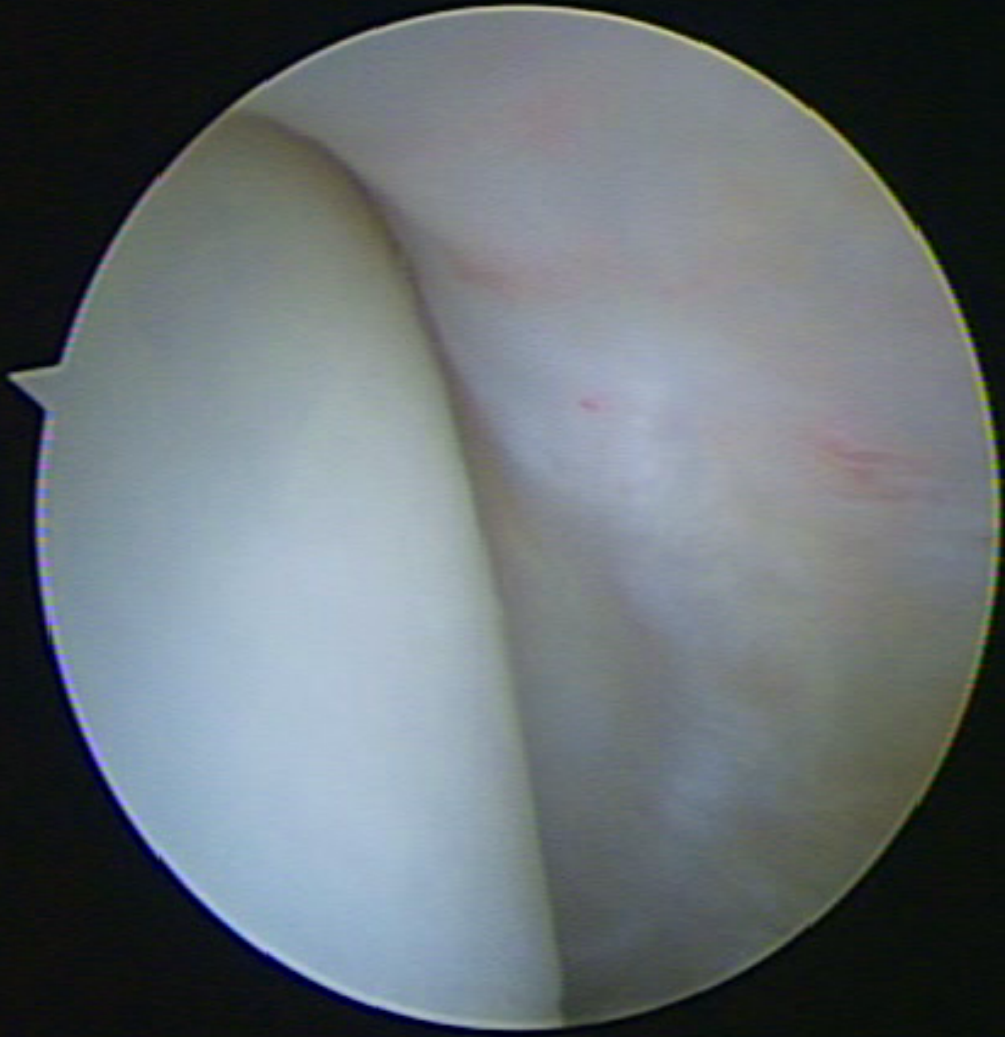




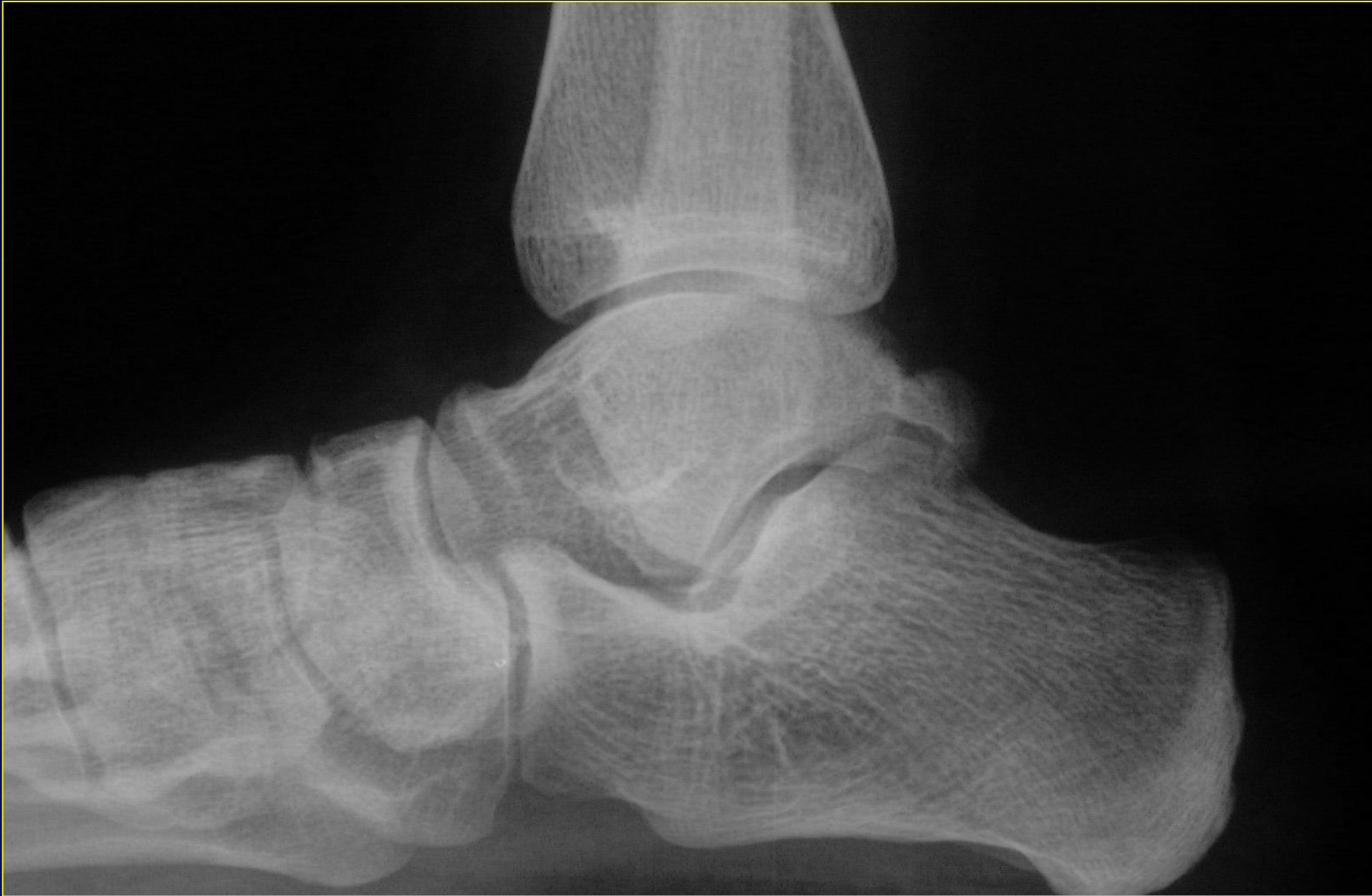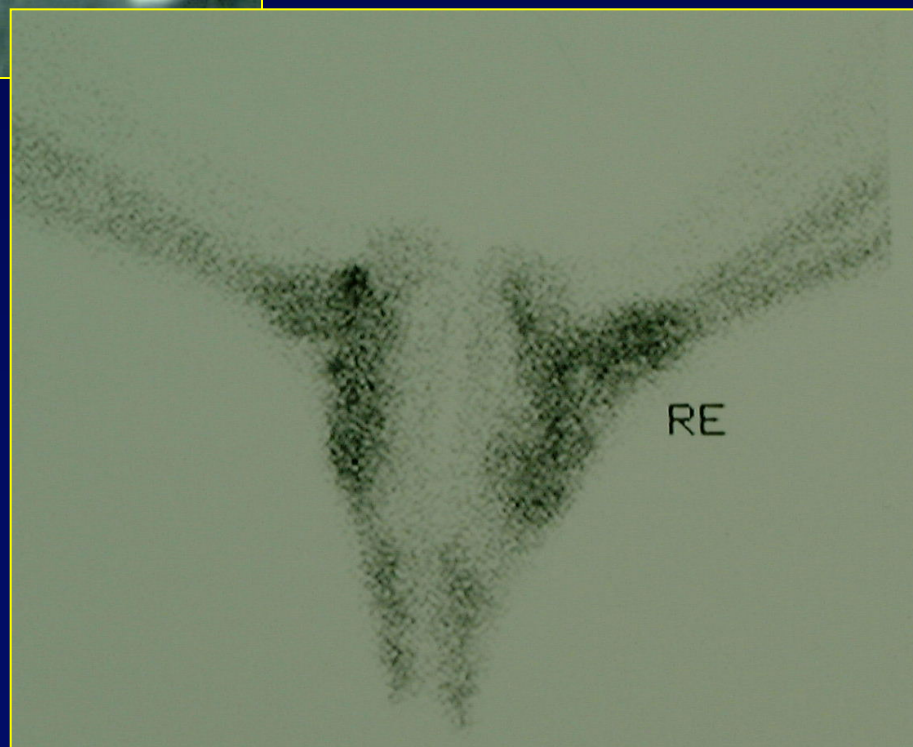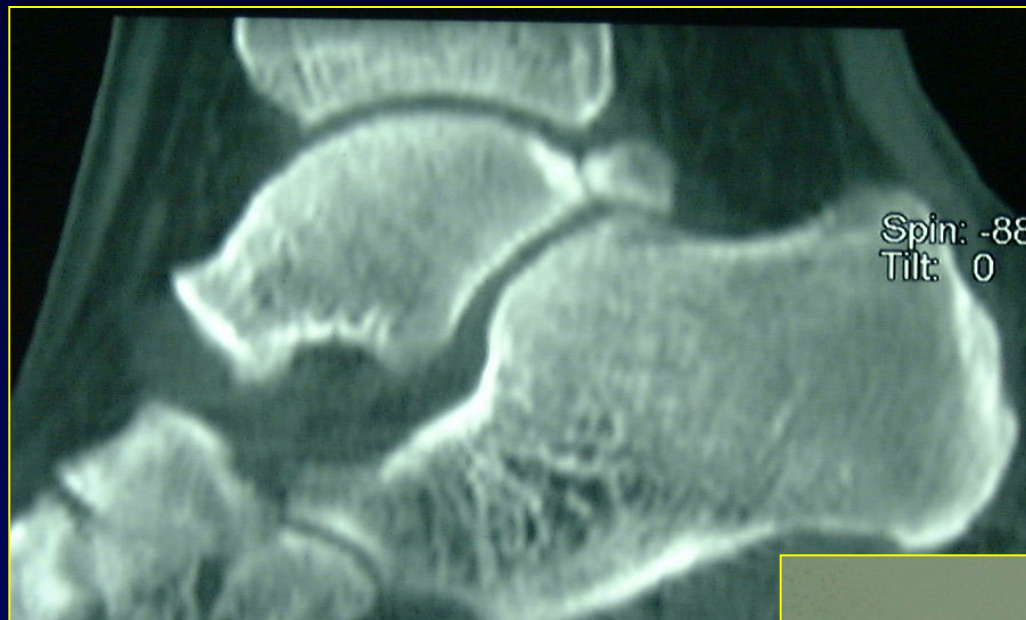


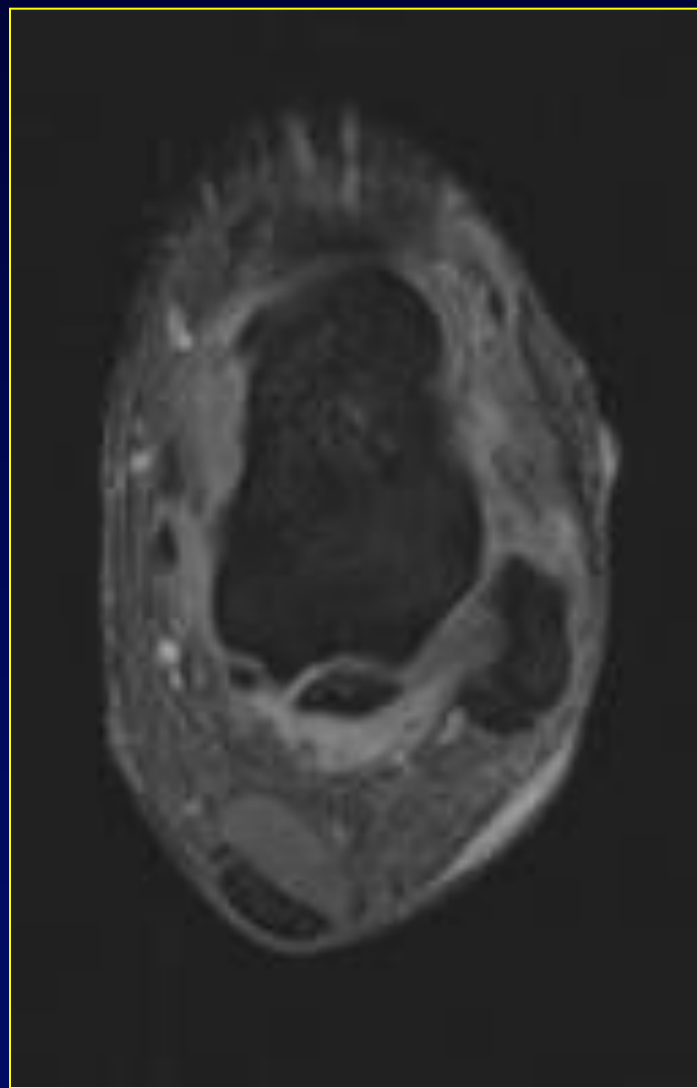


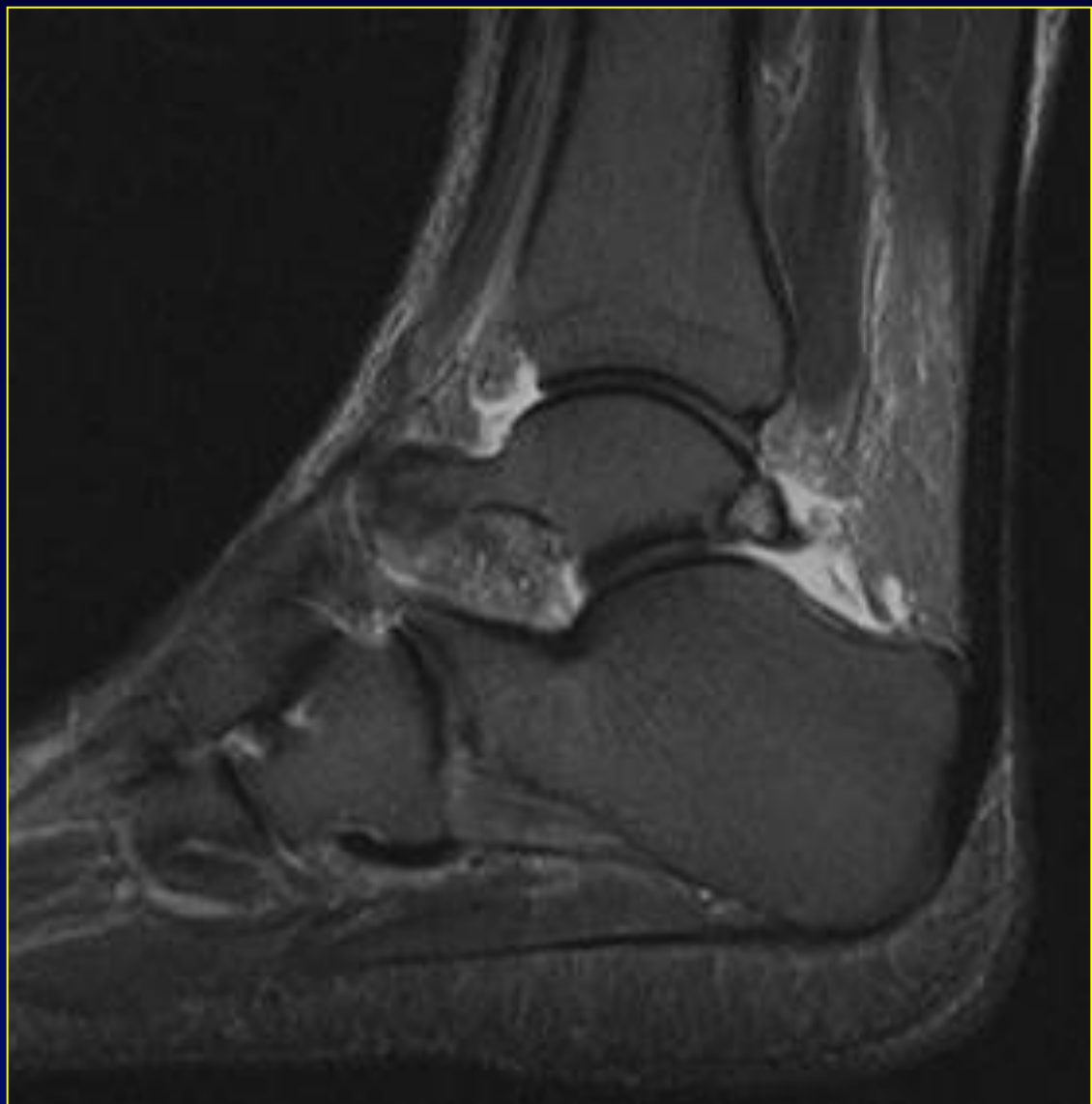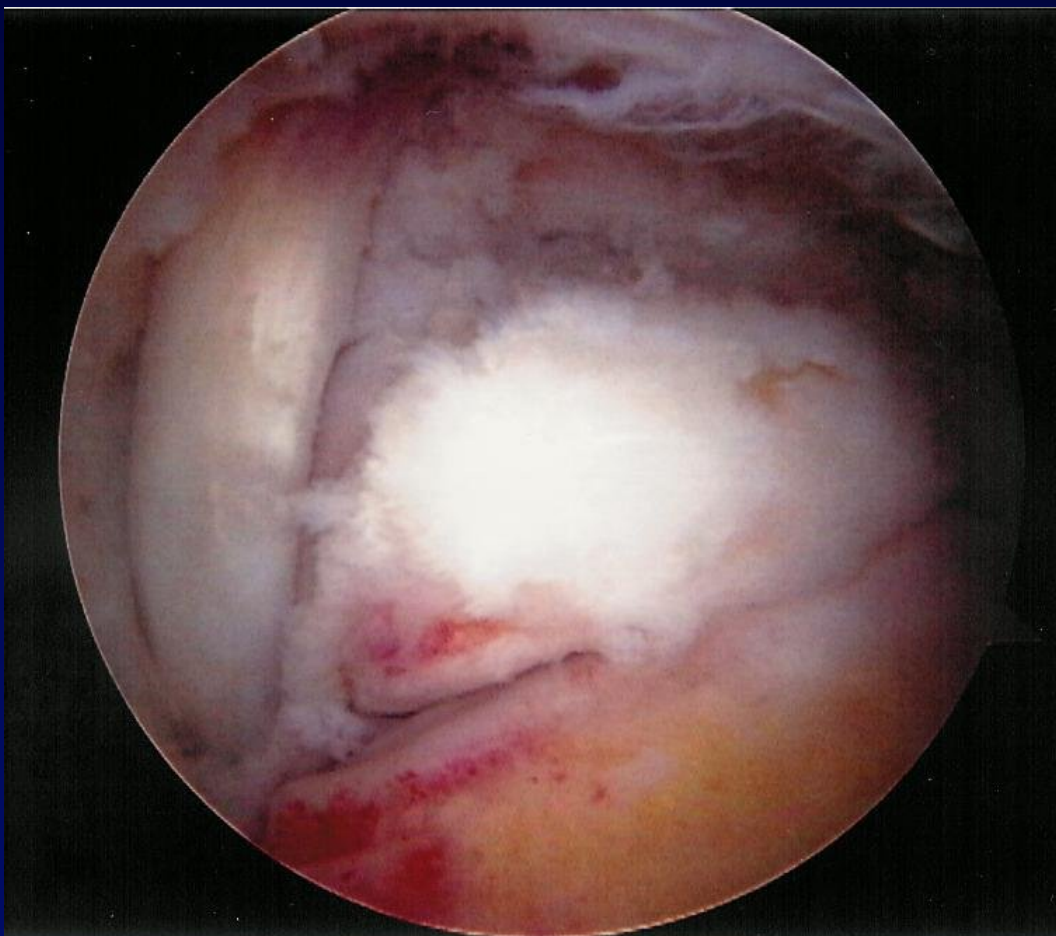


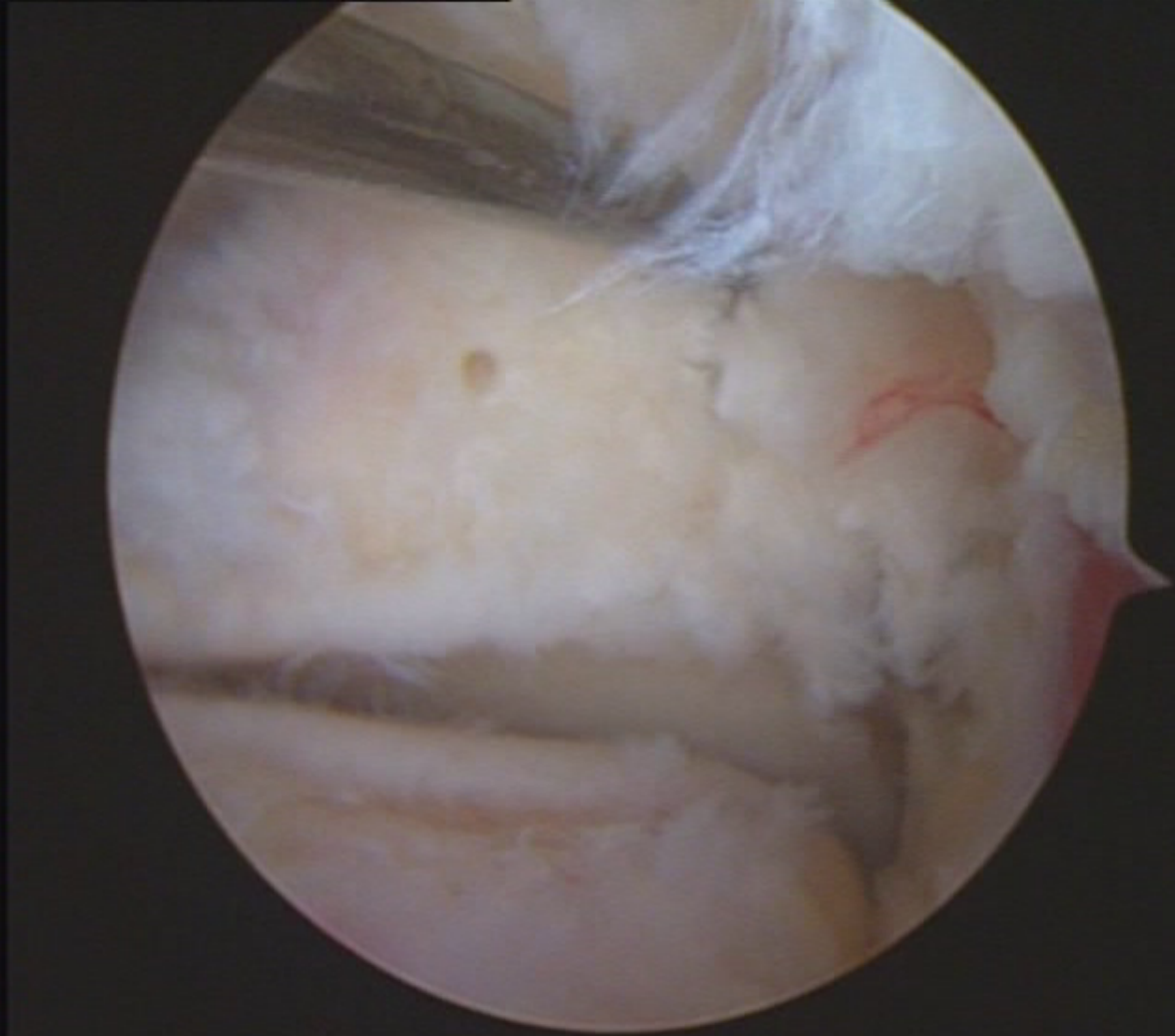


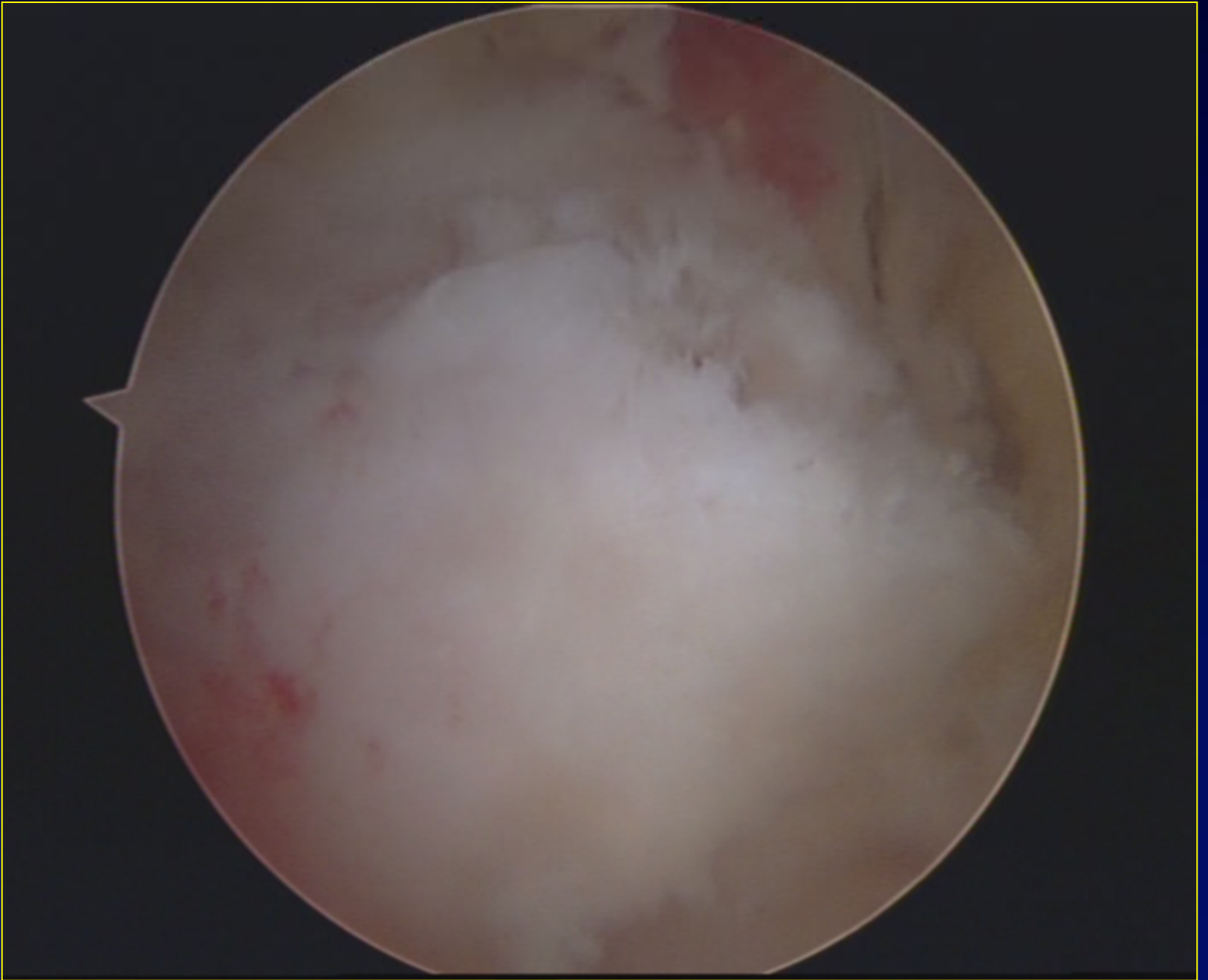


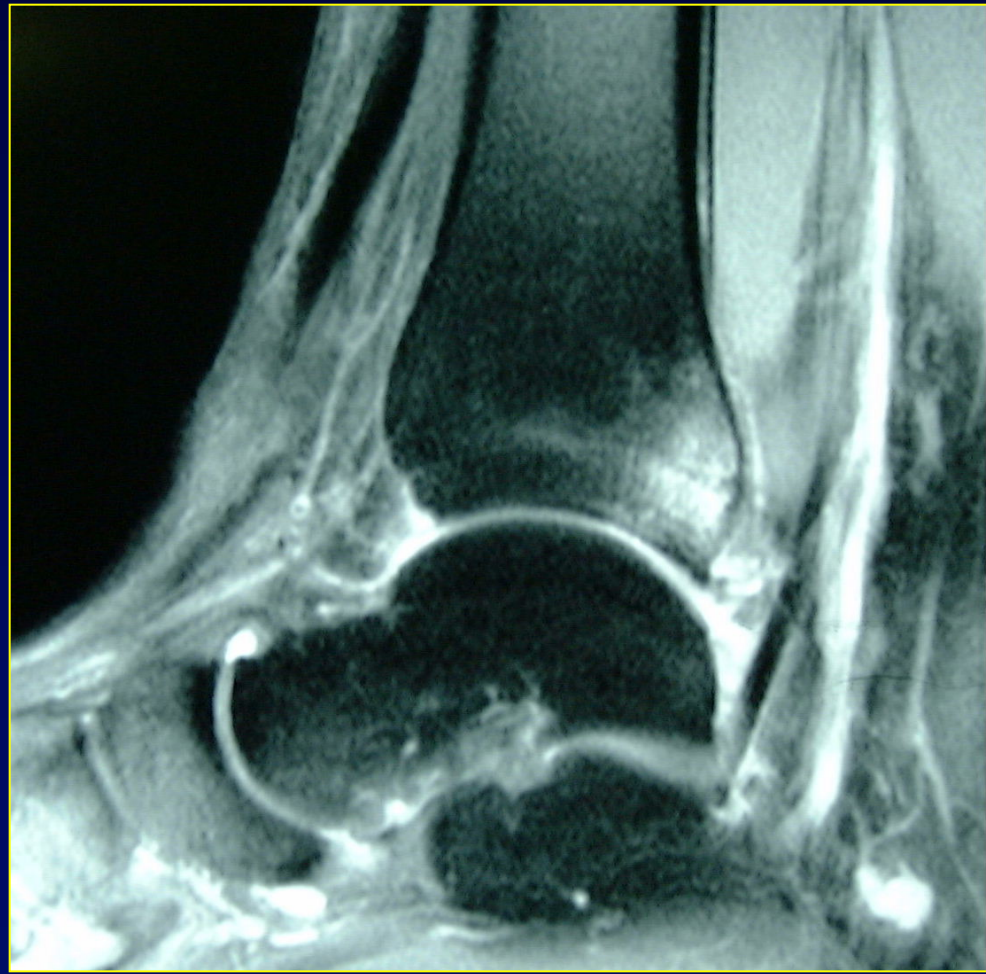
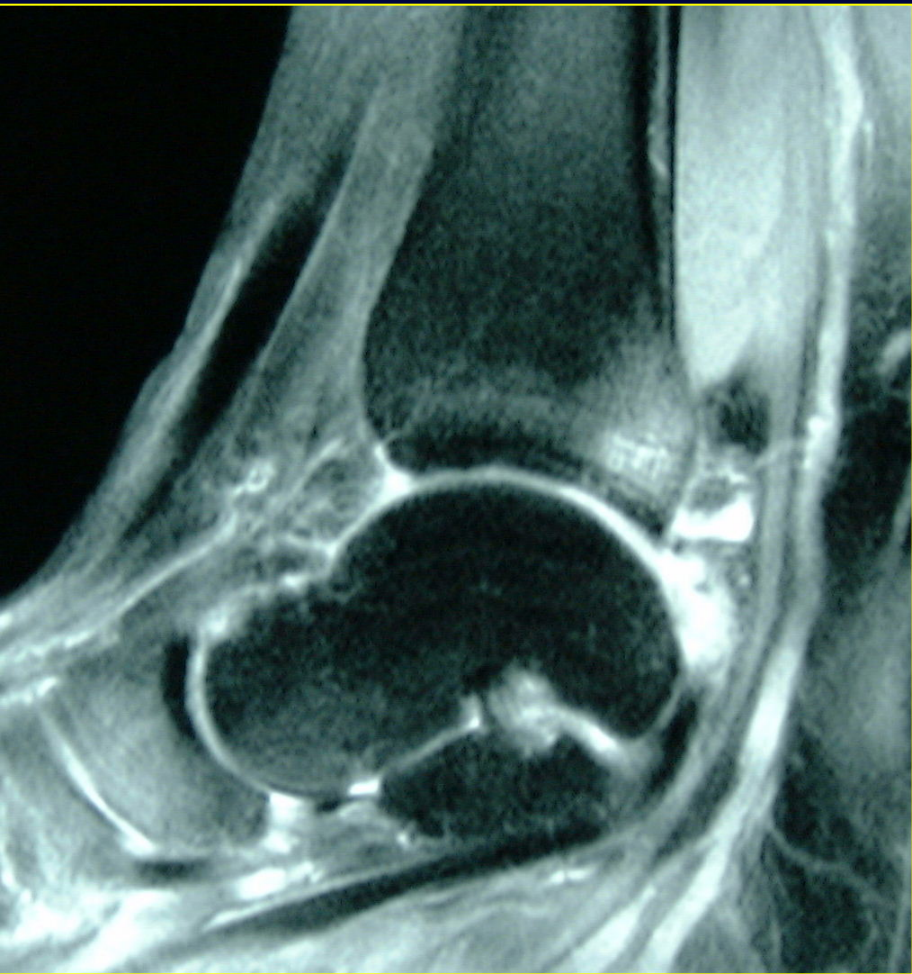


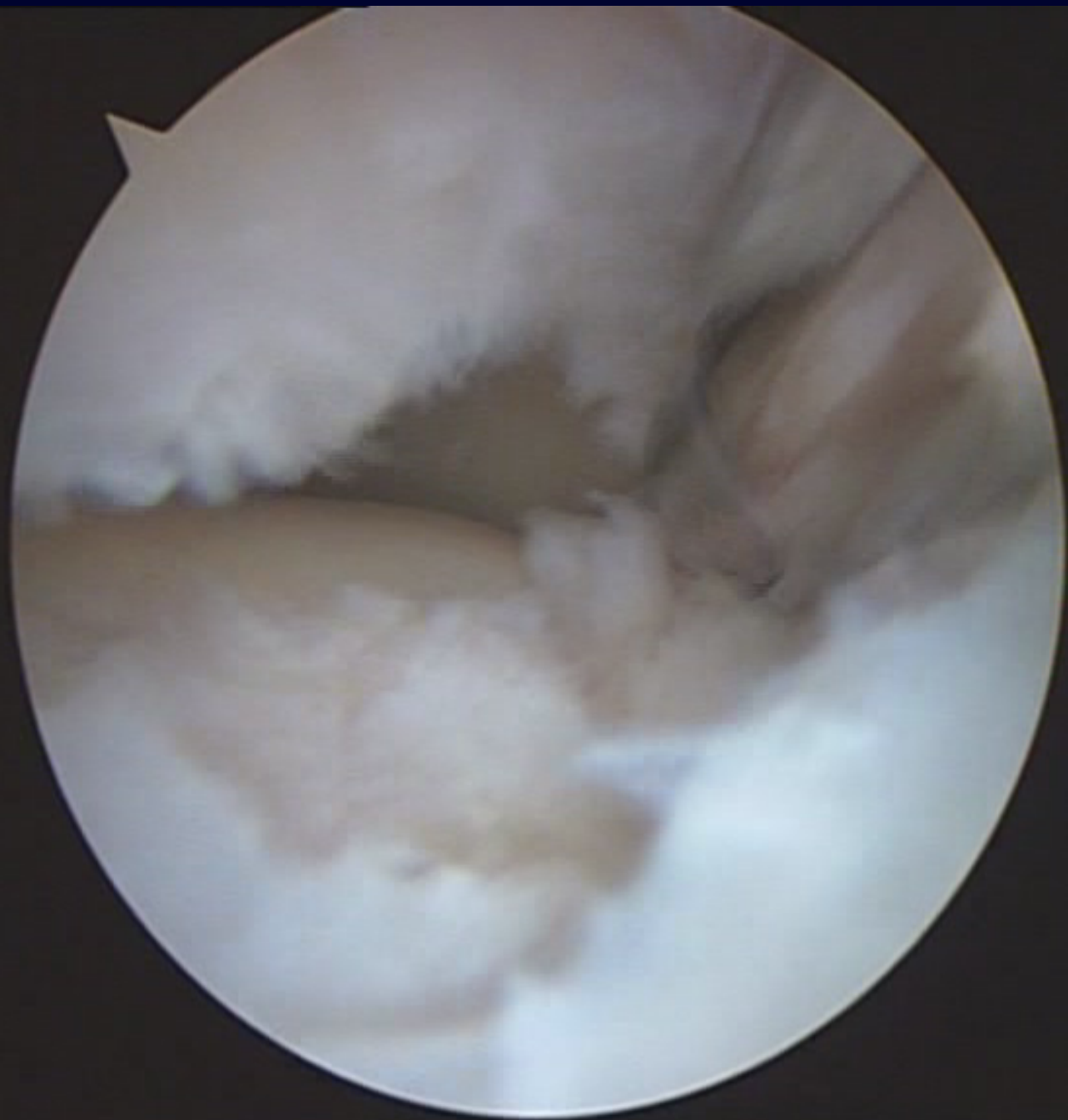







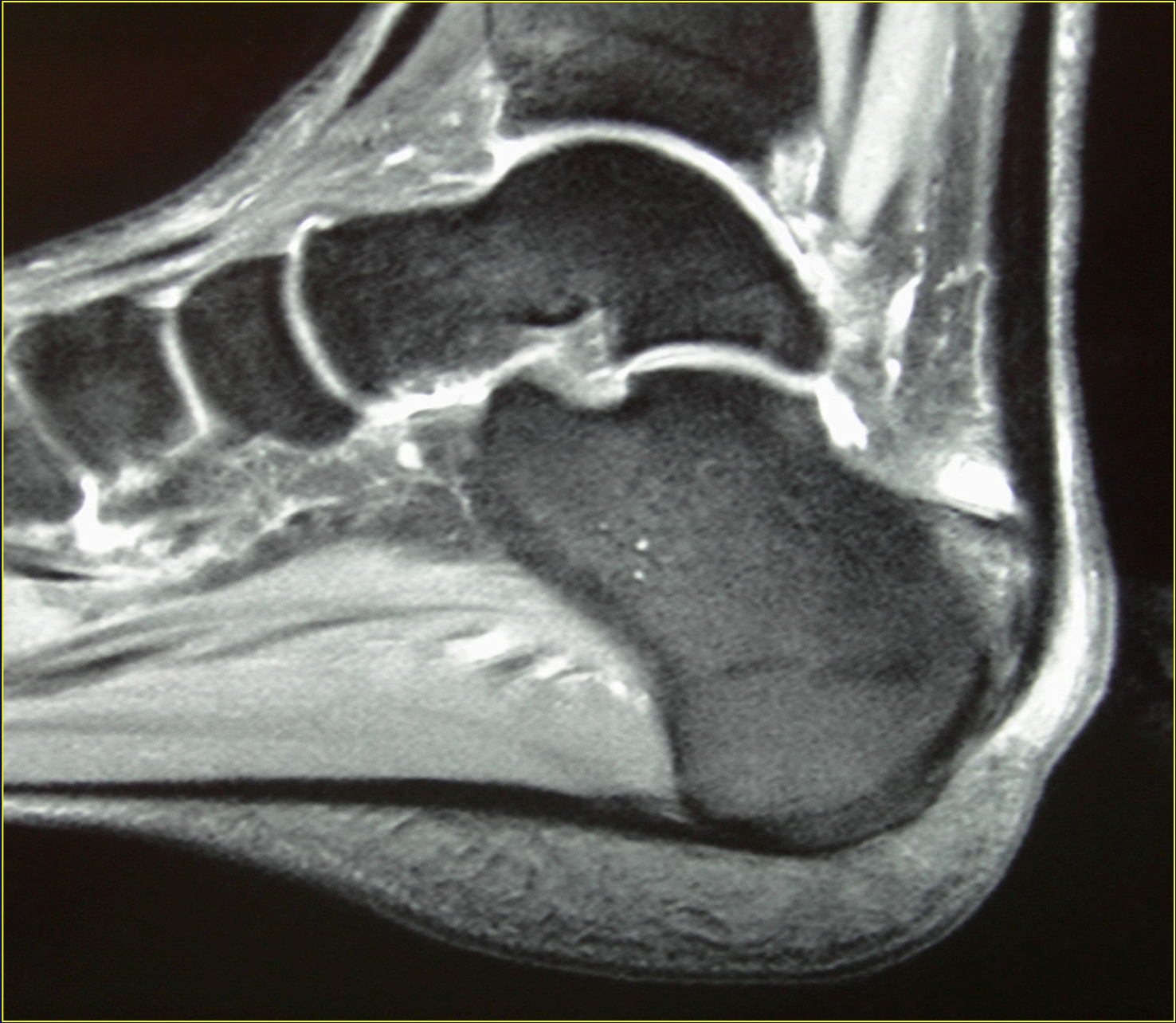


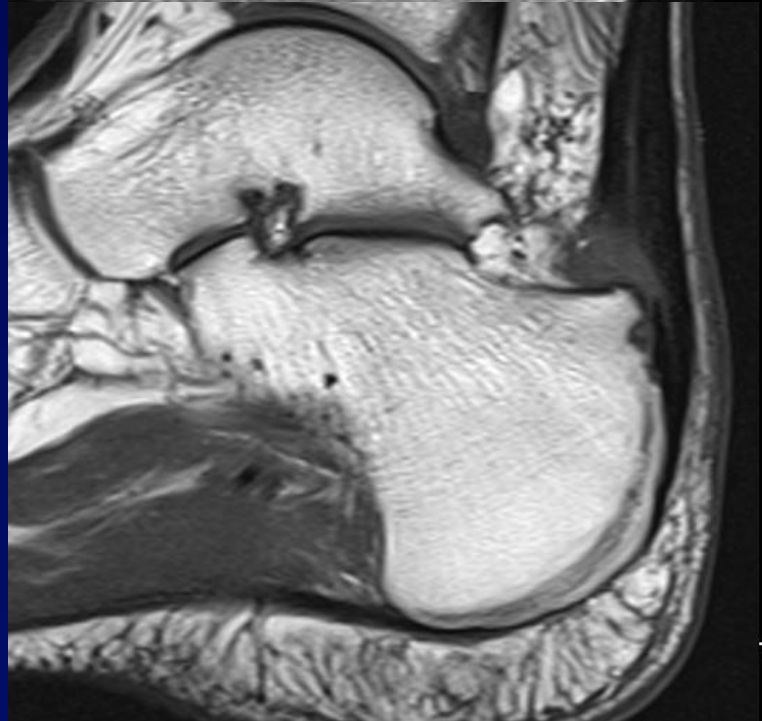
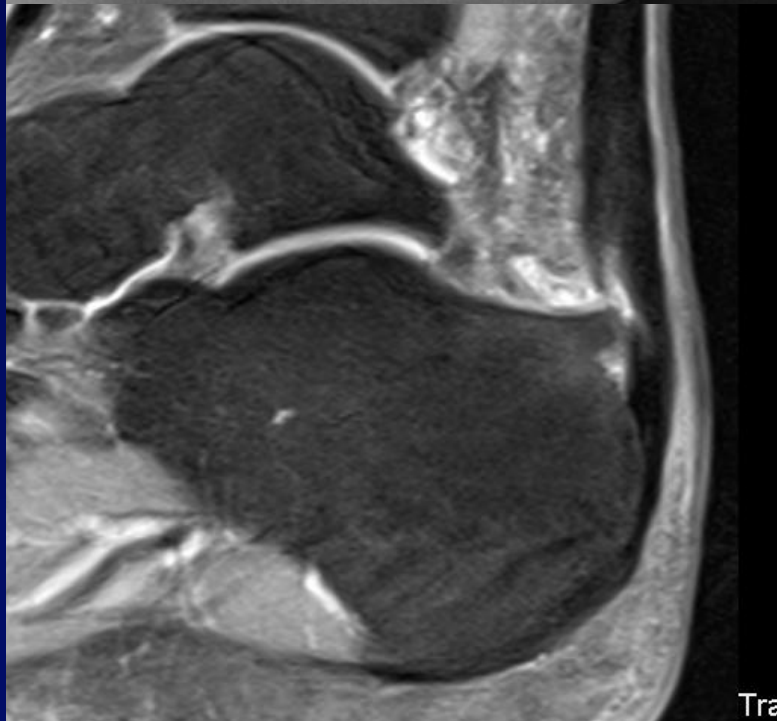


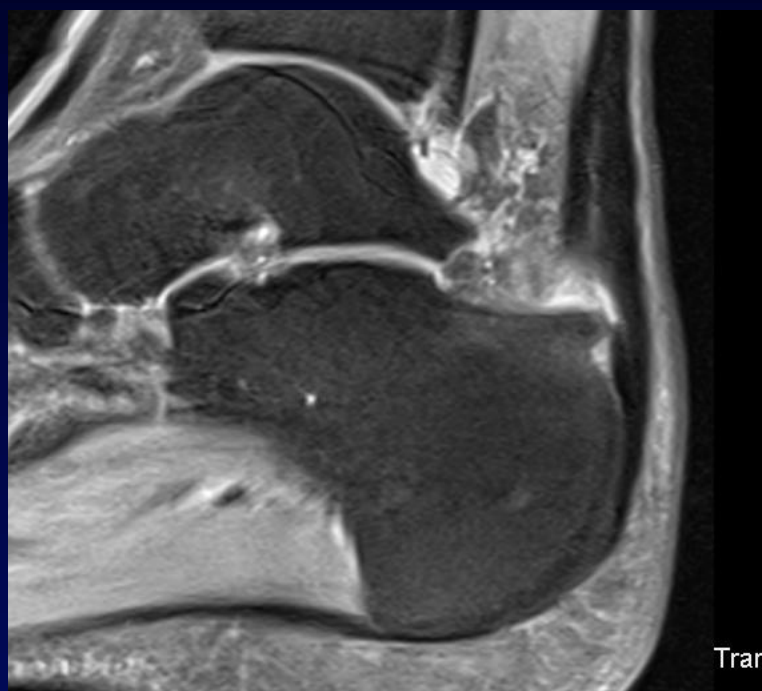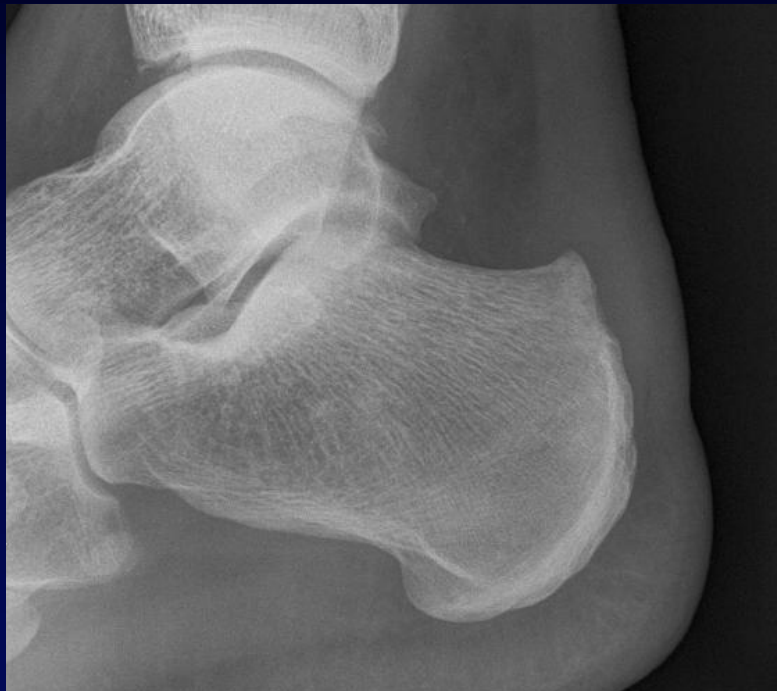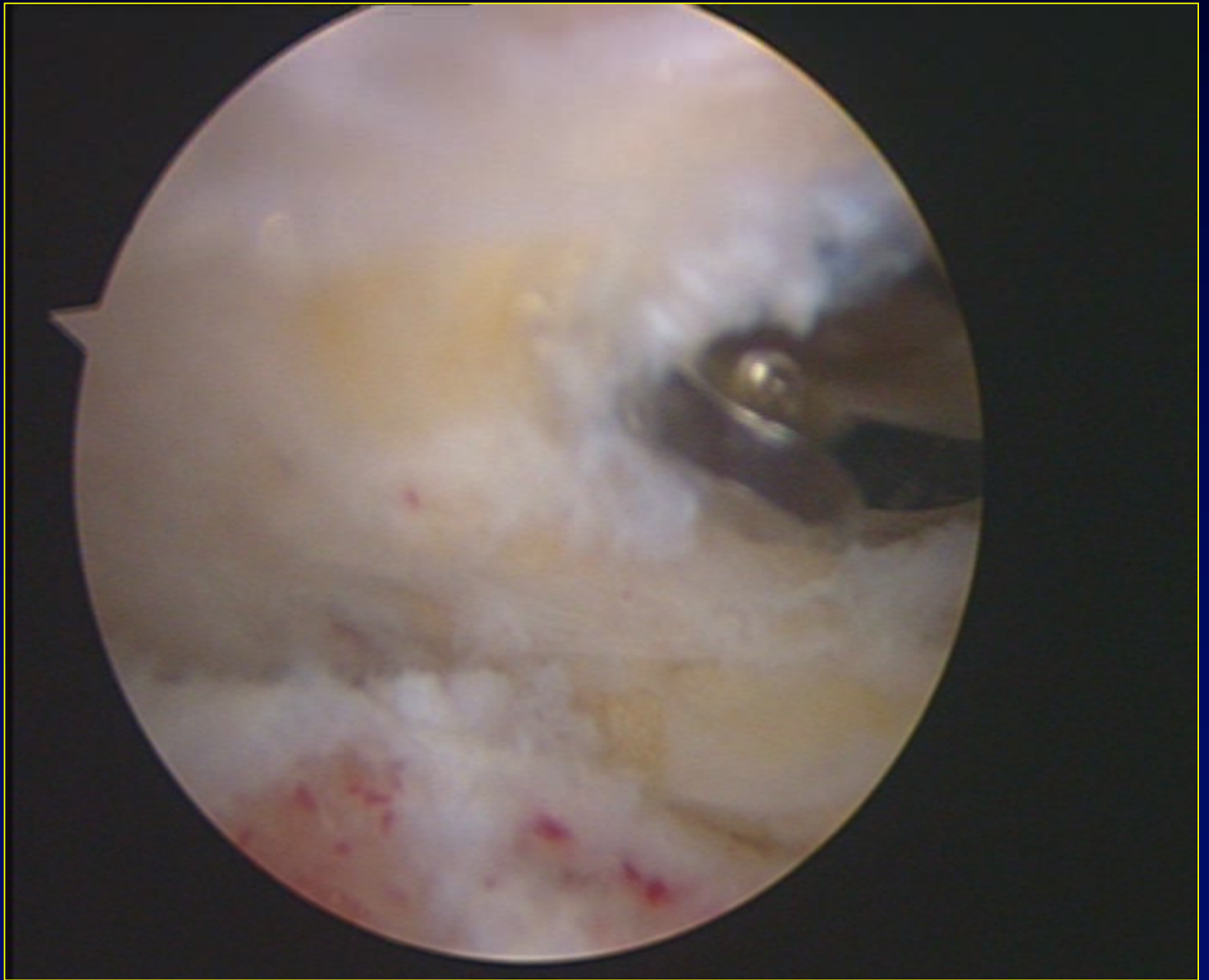


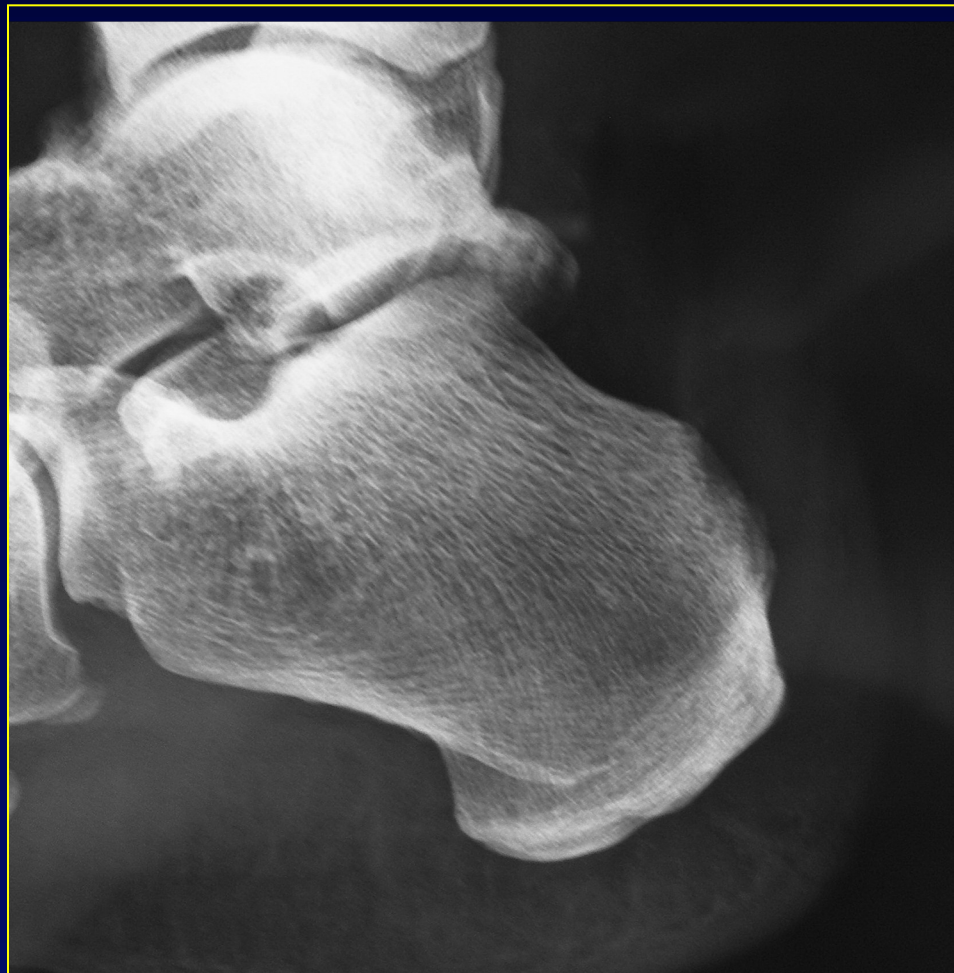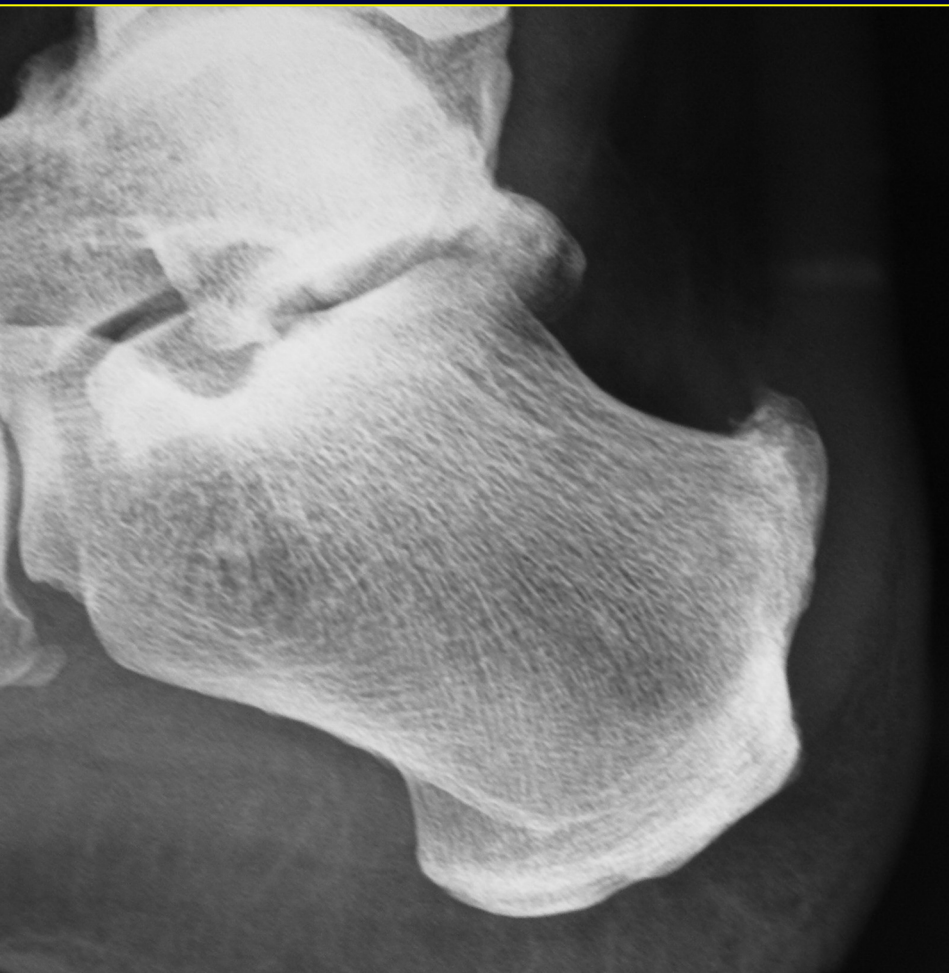Distal achilles tendon impingement

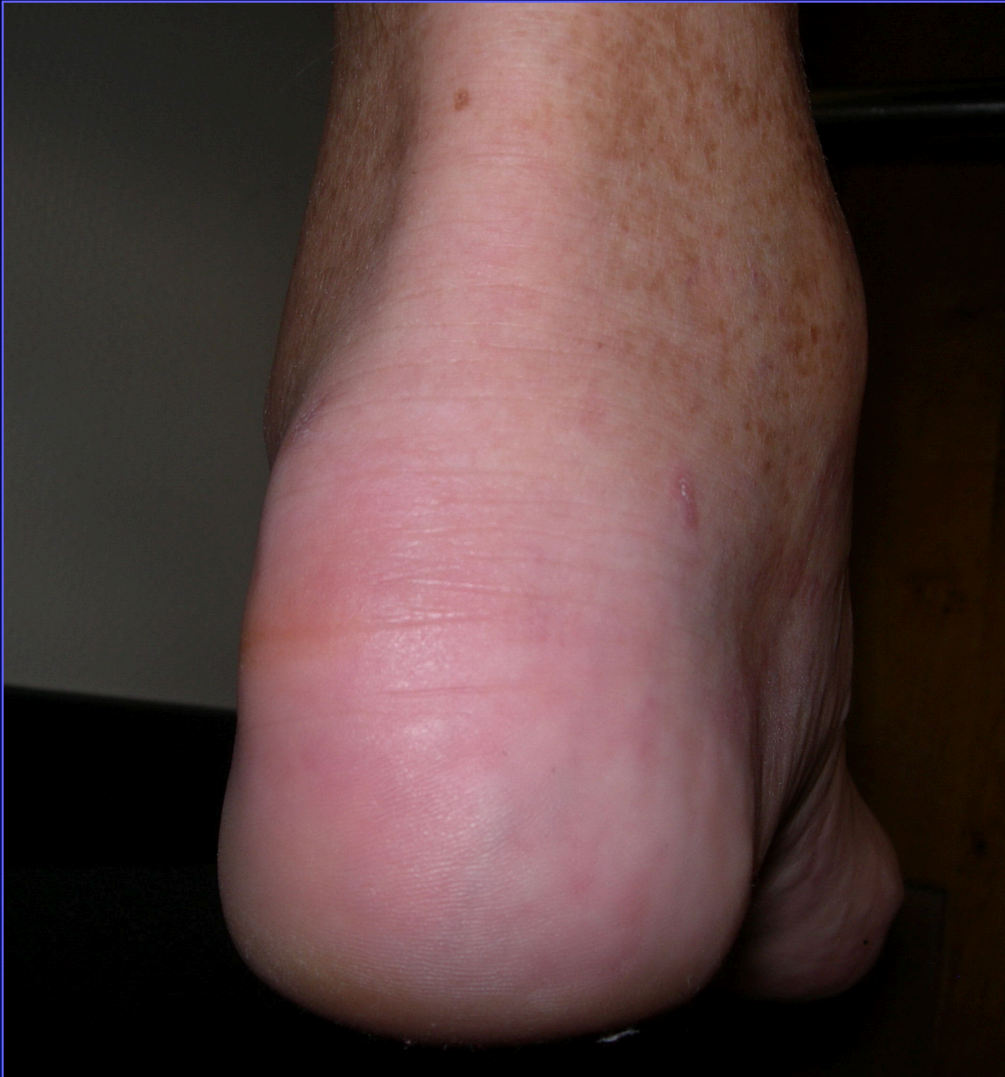


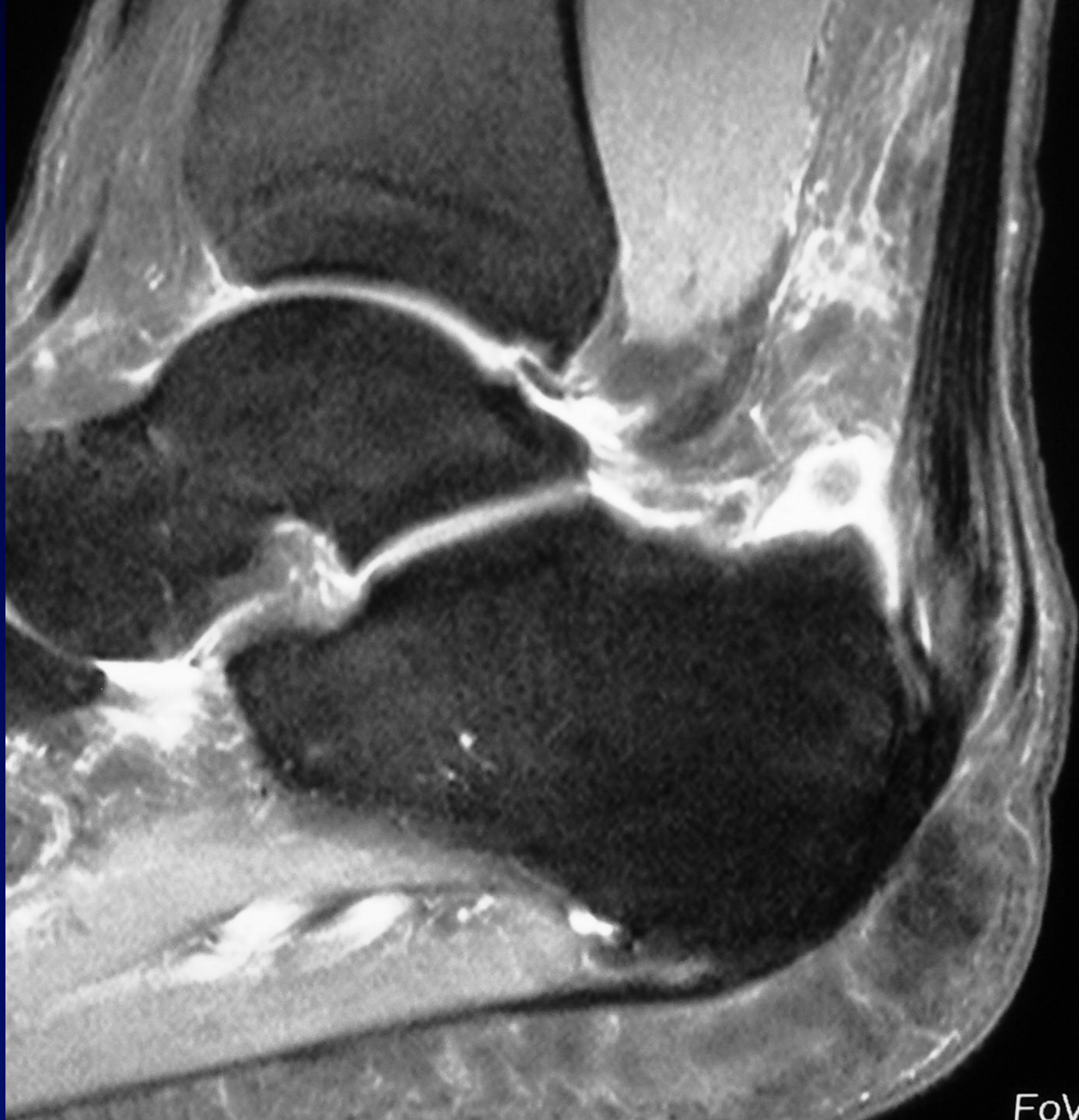


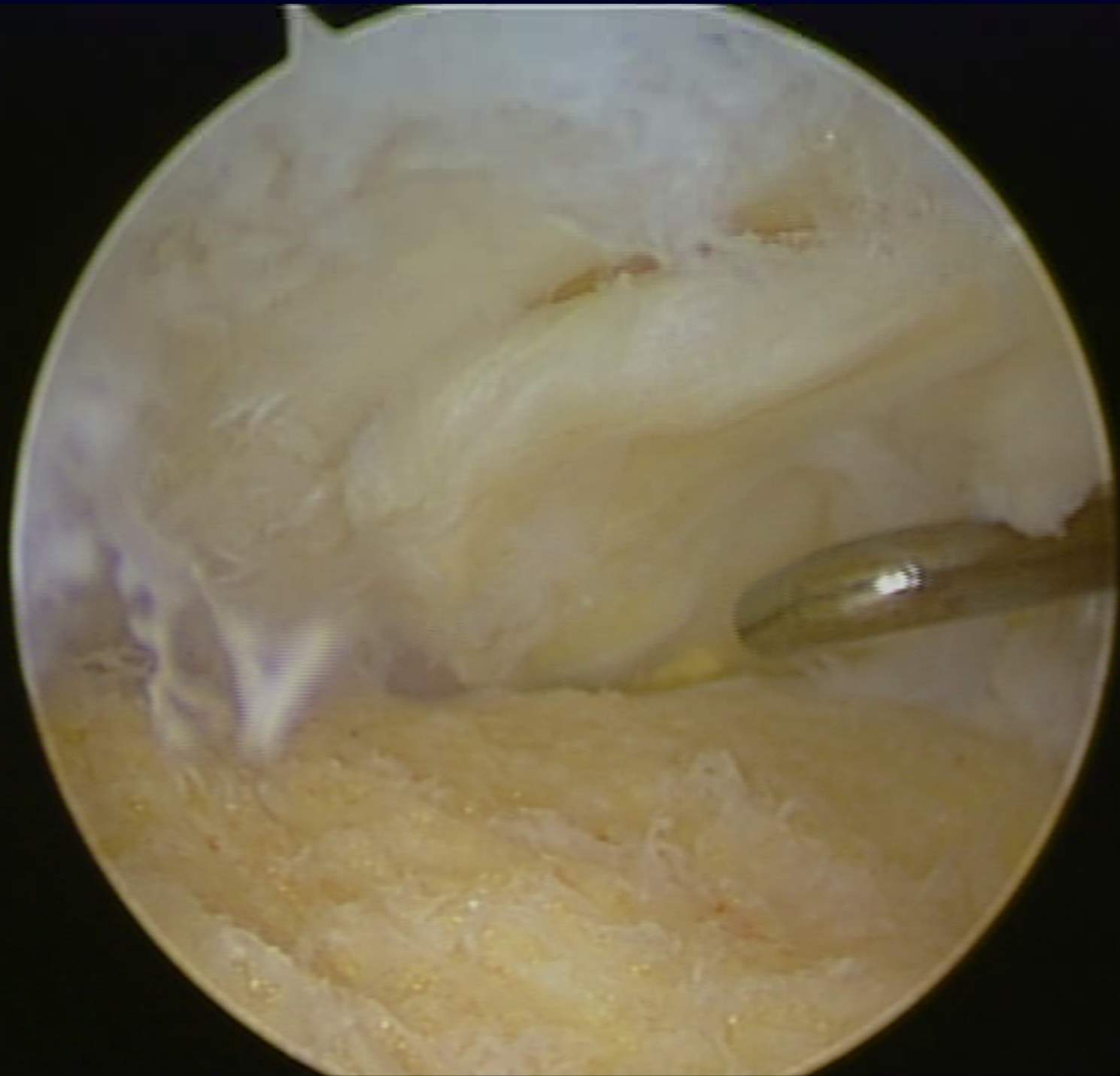








FoV



Take home message

- Vooreerst anatomische diagnose met klinisch onderzoek, RX, NMR, zo nodig Bot scan Spect CT.
- Arthroscopie van de enkel kan anterior en posterior worden uitgevoerd.
- Distal achillespees impingement kan arthroscopisch worden behandeld
- Minimaal invasief, goed zicht, snelle revalidatie

